Austin Internal Medicine

Open Access

Austin Publishing Group

Case Report

Pott's Disease, Avoiding Potentially Severe Consequences

Jessamy K*, Ojevwe F, Anozie O and Shepherd Z
Department of Internal Medicine, SUNY Upstate Medical University, USA

***Corresponding author:** Jessamy Kegan, Department of Internal Medicine, SUNY Upstate Medical University, 750 E Adams Street, Syracuse, NY, 13210, USA

Received: July 04, 2016; **Accepted:** August 10, 2016; **Published:** August 12, 2016

Abstract

Worldwide, Tuberculosis (TB) is the second leading cause of death from an infectious disease. The estimated incidence in the United States of America (USA) is 3.1per 100,000 population and is usually associated with immunecompromise. Tuberculous involvement of the vertebral body (Pott's disease) is a serious complication due to the hematogenous spread of *Mycobacterium tuberculosis* to the spine and it may have devastating consequences if not promptly treated.

We present a case of a 26 year old immunocompetent male with an eight month history of back pain and gradually worsening bilateral lower extremity weakness culminating in acute bilateral lower extremity paralysis. He underwent emergent surgical therapy due to his neurologic signs. Loboratory investigations yielded *Mycobacterium tuberculosis complex*. He was also treated with Rifampin, Isoniazid, Pyrazinamide and Ethambutol. This case highlights the importance of early recognition and diagnosis of Pott's disease, a rare and serious manifestation of TB infection, to prevent permanent neurological sequelae.

Keywords: Pott's Disease; Spinal Tuberculosis; Mycobacterium tuberculosis complex

Introduction

Worldwide, Tuberculosis (TB) is the second leading cause of death from an infectious disease with an estimated 9.6 million new TB cases in 2014 [1,2]. Tuberculosis is uncommon in developed nations and is commonly associated with states of immunocompromise, such as Human Immunodeficiency Virus (HIV) infection. The estimated incidence rate in the USA is 3.1per 100,000 population [1]. Osteoarticular tuberculosis affects approximately 2% of patients with tuberculosis and of these patients affected by skeletal tuberculosis, 50% present with spinal lesions [3]. Tuberculous involvement of the vertebral body (Pott's disease) is a serious complication due to the hematogenous spread of *Mycobacterium tuberculosis* to the spine and it can also occur in immunocompetent patients [1,4].

The clinical presentation of Pott's disease is variable: fever, chills, weight loss (58%), lower extremity weakness, radicular pain (90-100%) and in a few cases, paraplegia [5,6]. The diagnosis is usually made on imaging. In this case, we discuss an immunocompetent patient who presented with progressive bilateral lower extremity weakness culminating in bilateral paraplegia. Delay in establishing the diagnosis of Pott's disease and surgically relieving any associated spinal cord compression can lead to the progression of permanent neurological deficit and spinal deformity, thereby diminishing the likelihood of recovery [6].

Case Presentation

A 26 year old male inmate of a correctional facility presented complaining of acute bilateral lower extremity paralysis. He emigrated from Mexico when he was 21 years old. He was previously well until 8 months prior to his presentation when he developed gradually worsening thoracic region back pain which was aggravated by ambulation and associated with decreased sensation to his feet bilaterally. He noticed that he was having progressive bilateral leg weakness for 3 days prior to his admission and woke up on the day of admission unable to move or sense his lower limbs. He also complained of sensory loss up to the mid-abdomen and urinary retention for 2 days prior to admission. He denied cough, chest pain, fever, chills, rigors, unintentional weight loss, and any neurological deficit involving upper extremities. According to his records from the correctional facility, Purified Protein Derivative (PPD) skin testing at his correctional facility 8 months before was negative.

On examination, all vital signs were within normal limits: temperature 37.1°C, blood pressure 134/87 mm Hg, pulse 74 beats/minute, respiratory rate 16 breaths/minute, pulse oximetry 100% (room air). Physical examination was significant for withdrawal of the lower extremities only to noxious stimuli, bilateral lower extremity hyperreflexia, absent Babinski reflexes bilaterally, and diminished pinprick sensation inferior to the level of T8. Cardiovascular, respiratory and abdominal examinations were unremarkable. HIV, and Hepatitis B and C serology testing were negative.

Magnetic Resonance Imaging (MRI) of the thoracic spine revealed a peripherally enhancing collection in the T6-T7 disc space with extension into the epidural space and paraspinal soft tissues and associated severe spinal canal stenosis and compression of the spinal cord with expansion and edema of the cord from T5 through T8 (Figure 1). Computed Tomography (CT) scan of the thorax without contrast revealed diffuse pleural thickening on the right and small pulmonary nodules bilaterally (Figure 2).

The Neurosurgery team was consulted, and the patient underwent a laminectomy with complete facetectomy and foraminotomy of T4-T5 and T8-T9. A copious amount of pus was drained during the operative procedure and samples sent to the lab for culture, Polymerase Chain Reaction (PCR), and Acid Fast Bacilli (AFB) staining. Blood samples were also collected for a TB Interferon-Gamma Release Assay (IGRA). AFB was present on Fluorochrome

Jessamy et al. © All rights reserved

Citation: Jessamy K, Ojevwe F, Anozie O and Shepherd Z. Pott's Disease, Avoiding Potentially Severe Consequences. Austin Intern Med. 2016; 1(2): 1007.

Figure 1: MRI Thoracic Spine with contrast. Arrow indicates a peripherally enhancing collection in the T6-T7 disc space.

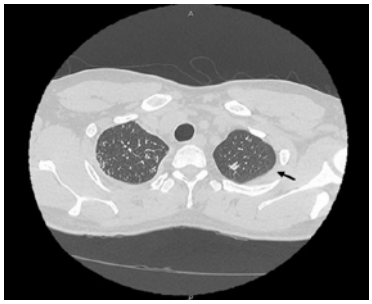

Figure 2: CT scan of Thorax without contrast. Arrow indicates pleural thickening.

staining. The patient was promptly started on Rifampin, Isoniazid, Pyrazinamide, and Ethambutol while awaiting IGRA, PCR, and culture reports which eventually returned positive for *Mycobacterium tuberculosis complex* with sensitivity to all of the aforementioned antimicrobial agents.

He received Rifampin, Isoniazid, Pyrazinamide, and Ethambutol for 2 months followed by Rifampin with Isoniazid for 10 months. After physical therapy, his strength and sensation eventually returned to his lower extremities.

Discussion

In 1782, Sir Percival Pott described spinal tuberculosis and described the surgical treatment of tuberculous spondylitis associated paraspinal abscess, hence, spinal TB is referred to as Pott's disease [7]. While lungs are the most common site of tuberculosis, bone and joint involvement is uncommon. Extrapulmonary tuberculosis most commonly occurs in the vertebral column (50%) and less frequently in the hip, knee and sacroiliac joints [3,4].

The HIV pandemic lead to a rise in the incidence of TB, however, it has made a minimal impact on the incidence of spinal TB [7]. Pott's disease is not only restricted to immunocompromised patients as it can also affect those who are immunocompetent as in our patient [4,7]. Recognition of Pott's disease in developing nations can be difficult as it is a rare complication of a relatively uncommon disease and there is a broad differential diagnosis which includes: spinal metastases, pyogenic and fungal osteomyelitis, multiple myeloma, and eosinophilic granuloma [7]. It is prudent that physicians detect Pott's disease as early as possible to decrease the risk of permanent paralysis occurring. The duration of symptoms prior to diagnosis is usually from 2 weeks to several years [7].

Our patient's MRI findings were due to advanced lesions related to pyogenic disease. MRI is more sensitive and specific than CT to diagnose Pott's disease [8]. Treatment options include surgery, conservative medical management or a combination of both. A prospective randomized, controlled, study on patients who had cervical myelopathy due to Pott's disease of the cervical spine showed a better outcome in surgically treated cases as compared to conservatively managed cases [9]. This was attributed to rapid spinal cord decompression which occurs in surgical cases. Kyphosis is a complication of Pott's disease which can be prevented by early detection prior to its onset.

Conclusion

Pott's disease is a rare but serious manifestation of TB infection that should be detected in its early stages to ensure prompt treatment. Patients with neurological complication require urgent surgical decompression for an optimal outcome. Even though TB and its extra-pulmonary manifestations are found more commonly in immunocompromised patients, it can also occur in immunocompetent persons. A high index of suspicion coupled with a thorough patient history, physical examination, and radiological investigation is necessary to obtain early diagnosis to minimize the risk of development of complications.

References

1. Global tuberculosis report. World Health Organization. 2016.
2. Lan L, Zhong J, Lan T, Lu Z, Long Q. Scapular bone destruction: A case report of skeletal tuberculosis with a series of dynamic radiologic features. Radiology of Infectious Diseases. 2015; 2: 84-87.
3. Chaudhry LA, Eissa EB, Chaudhry S. A 35-year-old immuno-competent male with open pulmonary tuberculosis associated with extra-ordinary extensive extra-pulmonary tuberculosis. International Journal of Mycobacteriology. 2013; 2: 183-186.
4. Ferrer MF, Torres LG, Ramirez OA, Zarzuelo MR, Gonzalez NDP. Tuberculosis of the spine. A systematic review of case series. International Orthopaedics (SICOT) International Orthopaedics. 2012; 36: 221-231.
5. Pertuiset E, Beaudreuil J, Liote F, Horusitzky A, Kemiche F, Richette P, et al. Spinal Tuberculosis in Adults: A Study of 103 Cases in a Developed Country, 1980-1994. Medicine. 1999; 78: 309-320.
6. Gur A, Altindag O, Karagullu H, Koca I, Madenci E. Multifocal skeletal tuberculosis presenting as paraplegia: a case report. Journal of Back and Musculoskeletal Rehabilitation. 2014; 27: 239-245.
7. Dass B, Puet TA, Watanakunakorn C. Tuberculosis of the spine (Pott's disease) presenting as 'compression fractures'. Spinal Cord. 2002; 40: 604-608.
8. Ridley N, Shaikh M, Remedios D, Mitchell R. Radiology of skeletal tuberculosis. Orthopedics. 1998; 21: 1213-1220.
9. Elsawaf A. Outcome of surgical versus conservative management of cervical spine myelopathy secondary to cervical tuberculosis. Neurosurgical Review. 2013; 36: 621-628.