

Mini Review

Ab Interno Approach of Subconjunctival Filtration with Xen Gel Stent

Keskin AM, Sevim DG*, Unlu M and Mirza GE
Department of Ophthalmology, Erciyes University,
Turkey

***Corresponding author:** Duygu Gulmez Sevim,
Department of Ophthalmology, Erciyes University
Faculty of Medicine, Yeni Mah, Talas Bulvari, 38039,
Melikgazi, Kayseri, Turkey

Received: August 02, 2016; **Accepted:** August 25,
2016; **Published:** August 26, 2016

Abstract

The XEN implantation is an ab interno technique of minimally invasive (or microincisional) glaucoma surgery (MIGS). It is a gelatin stent under investigation that would be implanted via a clear corneal incision without conjunctival dissection. Three 6.0mm long implants, each with an internal diameter for varying levels of Intraocular Pressure (IOP) control, were designed. It is injected through a small corneal incision using a simple, preloaded IOL-like injector. There are few articles about XEN gel stent and in these studies successful results have been achieved as a result of less traumatic surgical procedures than traditional glaucoma surgeries. In all cases, subconjunctival MMC injection was applied before the surgery. Also, most of the surgeries were combined with phacoemulsification and this should be taken into account while considering IOP reduction. In conclusion, more studies with higher numbers of patients and with more follow up are necessary.

Keywords: Glaucoma; Microincisional glaucoma surgery; Minimally invasive glaucoma surgery; Xen gel stent; Xen implantation

Abbreviations

SLT: Selective Laser Trabeculectomy; MIGS: Minimally Invasive (Or Microincisional) Glaucoma Surgery; IOP: Intraocular Pressure; POAG: Primer Open Angle Glaucoma; MMC: Mitomycin C

Introduction

Since glaucoma is one of the most important causes of irreversible blindness worldwide, new medical and surgical treatment options are needed to investigate. While many patients can be controlled with medications, patient adherence and ocular toxicity are major issues in the developed world, and lifetime costs and accessibility to medications are issues in developing regions [1]. Laser treatment options, especially Selective Laser Trabeculectomy (SLT), are noninvasive, non-medication treatment approaches, but its efficiency commonly decreases over time [2]. Therefore, surgery becomes significant for the long-term treatment. Although effectiveness of trabeculectomy and tube is evidently proved, short or long-term complications prompt the new investigations. Tube and trabeculectomy patients have similar rates of vision-threatening complications such as blebitis, endophthalmitis, or choroidal haemorrhage [3].

In order to decrease the rate of complications, different MIGS techniques have been developed. Those aim to provide a safer, less invasive means of reducing IOP than traditional surgery, with the goal of reducing dependency on topical medications.

Xen Gel Stent

The XEN implantation is an ab interno technique of MIGS. The XEN gel stent (Aquesys, Inc., Aliso Viejo, CA, USA) is a gelatin stent under investigation that would be implanted via a clear corneal incision without conjunctival dissection (Figure 1) [4,5].

The biocompatibility properties of gelatin are well established and

do not cause a foreign-body reaction. Ocular implantation in dogs with full histopathology (12 months) and ocular implantation in a nonhuman primate (6 years) showed no changes in implant cross-sections [6]. The flexibility and softness allows it to imitate to the ocular tissue, which may be shown to minimize many of the issues seen with synthetic materials.

As the basis of the traditional glaucoma surgeries, subconjunctival filtration provides a route for aqueous outflow. Therefore, success of the surgery is affected by conjunctival status, such as not to have a scarring. Also, it is aimed that hypotony, a significant complication of the surgery, is avoided by the flow resistance determined by the length and inner diameter of the tube [4].

Implant Models

Three 6.0mm long implants, each with an internal diameter for

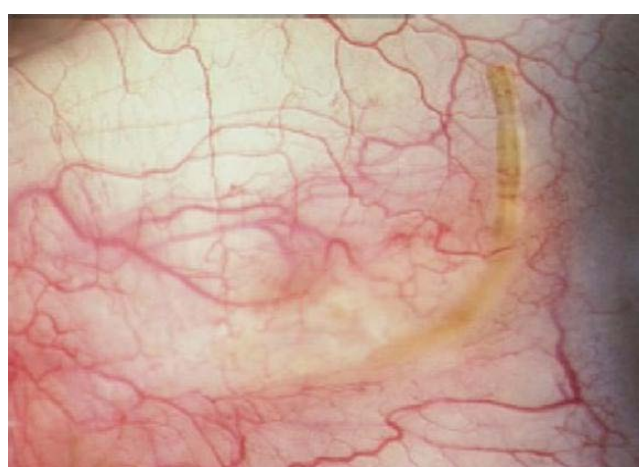


Figure 1: External view of XEN gel stent in subconjunctival space.

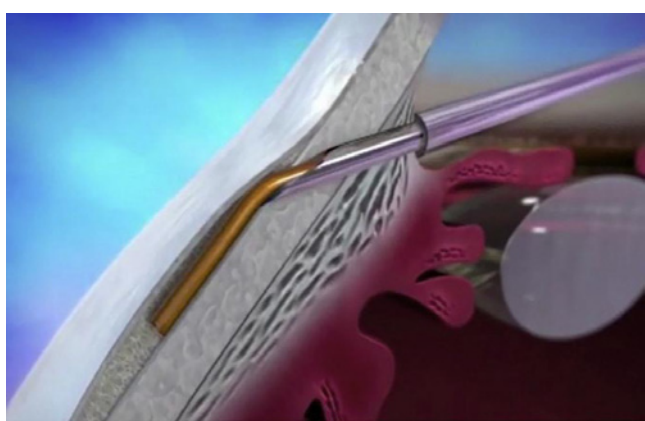


Figure 2: XEN45 implant being released into the subconjunctival space with the needle inserted in the angle.

varying levels of IOP control, were designed. Except from the diameter, the material, manufacturing processes, and implantation procedures of all XEN models are identical. The XEN140 has the largest, with an inner diameter of approximately 140 μ m. The XEN63 has a smaller lumen (approximately 63 μ m), and the XEN45 has the smallest inner lumen (approximately 45 μ m) [4]. It is injected through a small self-sealing corneal incision using a simple, preloaded IOL-like injector.

There are few articles about XEN gel stent in the literature. Perez-Torregrosa et al. published the first article [7]. They performed phacoemulsification combined with XEN45 implant surgery on 30 eyes requiring cataract surgery with Primer Open Angle Glaucoma (POAG), on at least 2 antiglaucoma medications. They injected 1mL of 0.01% Mitomycin C (MMC) fifteen minutes before the surgical procedure. Surgeries were performed by the same surgeon, through 2 temporal incisions, using the inferior to enter the XEN45 and to implant it in the superior nasal region. After implanting an intraocular lens in the capsular sac, 1% acetylcholine was injected in Anterior Chamber (AC) in order to contract the pupil, followed by high density viscoelastic for greater angle opening. Then the XEN45 injector needle was introduced into the AC through the inferior temporal incision while fixing the eye with a Vera hook through the superior temporal incision. The needle was carried out in a 3 mm intra-scleral pathway (Figure 2). The subconjunctival needle was withdrawn. When the entire bezel is seen, it was rotated 90°. After removing the implantation sleeve, the implant was released, and then the needle was withdrawn [6]. After the surgery, they approximately achieved an IOP reduction of 29.34% against presurgery values. The number of antiglaucoma medicaments diminished 94.57% at month 12 post-surgery.

Intraoperative slight intracameral hemorrhage occurred in 26 eyes (86.6%) and resolved with irrigation-aspiration in all cases. Discrete hemorrhage in the scleral exit points of the XEN device was observed in 27 eyes (90%), without additional consequences. In 6 eyes (20%) it was necessary to relocate the implant due to short subconjunctival pathway (under 2 mm), by means of scleral approach with blunt tweezers. In one eye (3.3%), the XEN device was extracted from the AC due to an excessively long intrachamber pathway, although it was reimplanted with the same injector. None of the eyes exhibited intra-surgery complications related to cataract surgery [7].

Looked at postoperative complications, none of the eyes exhibited hypotony below 5mmHg or other severe complications. In one case (3.3%) the bleb encapsulated at follow-up month 5, requiring topical antiglaucoma treatment with 3 pharmacological principles for controlling IOP at 12 months [7].

Sheybani and Ahmed reported numbers, as well very similar to Perez-Torregrosa's study with combined surgery comprising XEN45 implant and MMC in 31 eyes, obtaining IOP reduction of 30% and 37% at 6 and 12 months respectively, although they achieved a reduction in the use of medicaments of only 67% at one-year post-surgery [8].

Lavin-Dapena C et al. indicated 12 month results from a XEN45 implantation combining with a preoperative MMC. Intraoperative complications related to XEN gel stent were AC bleeding (2.8%) and subconjunctival bleeding (1.4%). Moreover, postoperative complications were flat anterior chamber requiring AC refill (1.4%), hyphema (4.1%) and hypotony below 6 mmHg at first day (12.6%). Also, one case was converted to tube at 1 month and 1 implant was fractured due to repositioning of implant [9].

Also, a hypertrophic bleb following XEN stent implantation is the one and only case report published. Fernandez-Garcia reported that a few weeks later the surgery, filtration bleb increased in size occupying 180° nasally, producing medial mechanical ectropion. They used 'Dry Lake' technique for treatment and it resulted in successfully [10].

There are three ongoing clinical trials related to Xen gel stent registered to clinicaltrials.gov. One active study has been ongoing since 2013 and its purpose is to evaluate the treatment of moderate primary open angle glaucoma patients with the AqueSys XEN Implant when medications are inaccurate (NCT02006693), while another one is investigating the outcomes of the same device in patients with refractory glaucoma (NCT02036541). Also, a study about micro structure of Schlemm's canal currently has been planned and one branch of the series is Xen Gel Stent implant (NCT02807935). The purpose of the series of studies is to evaluate different glaucoma treatment's *in vivo* effect on the conventional outflow pathway, and specifically on the Schlemm's canal anatomy using Enhanced Depth Imaging (EDI)-Optical Coherence Tomography (OCT). These clinical trials are needed to be resulted before the stent can be accepted throughout the world. Nevertheless, some surgeons individually try to apply the stent for appropriate patients with glaucoma in some countries.

Conclusion

A less traumatic surgical procedure and long-term IOP reduction are the main goals of effective glaucoma surgery. Although there are few clinical researches about the new gel stent, the results seem to be encouraging that it progresses with lower complication rates and effectiveness in POAG patients. Protecting the conjunctiva-tenon area is a significant aim for the filtration surgery and usage of MMC reduces the risk of fibrosis, as well. Moreover, it has an advantage of being combined with cataract surgery safely.

On the contrary, American Academy of Ophthalmology published a report about the effect of phacoemulsification on intraocular pressure in glaucoma patients. It suggested that cataract

surgery results in a small, moderate, and marked reduction in IOP and medications for POAG, pseudoexfoliation glaucoma, and primary angle-closure glaucoma, respectively [11]. While the surgery is commonly combined with the cataract surgery in the recent studies, it may be unclear whether it depends on the filtration surgery. But, Perez-Torregrosa reported that the reduction is greater than the reduction demonstrated by isolated phacoemulsification in patients with POAG [7].

In conclusion, it should be considered that there are some limitations of clinical studies. Therefore, more studies with higher numbers of patients and with more follow up are necessary in order to approve the encouraging results.

References

1. Lemij HG, Hoevenaars JG, van der Windt C, Baudouin C. Patient satisfaction with glaucoma therapy: reality or myth? *Clinical ophthalmology*. 2015; 9: 785-793.
2. Leahy KE, White AJ. Selective laser trabeculoplasty: current perspectives. *Clinical ophthalmology*. 2015; 9: 833-841.
3. Gedde SJ, Herndon LW, Brandt JD, Budenz DL, Feuer WJ, Schiffman JC, et al. Postoperative complications in the Tube Versus Trabeculectomy (TVT) study during five years of follow-up. *American journal of ophthalmology*. 2012; 153: 804-814.
4. Lewis RA. Ab interno approach to the subconjunctival space using a collagen glaucoma stent. *Journal of cataract and refractive surgery*. 2014; 40: 1301-1306.
5. Richter GM, Coleman AL. Minimally invasive glaucoma surgery: current status and future prospects. *Clinical ophthalmology*. 2016; 10: 189-206.
6. Yu DY, Morgan WH, Sun X, Su EN, Cringle SJ, Yu PK, et al. The critical role of the conjunctiva in glaucoma filtration surgery. *Progress in retinal and eye research*. 2009; 28: 303-328.
7. Perez-Torregrosa VT, Olate-Perez A, Cerda-Ibanez M, Gargallo-Benedicto A, Osorio-Alayo V, Barreiro-Rego A, et al. Combined phacoemulsification and XEN45 surgery from a temporal approach and 2 incisions. *Archivos de la Sociedad Espanola de Oftalmologia*. 2016.
8. Sheybani A AI. Ab interno gelatin stent with mitomycin-C combined with cataract surgery for treatment of open-angle glaucoma: 1-year results. *Congreso Sociedad Americana de Cirujanos de Catarata y Refractivos (ASCRS), Boston: ASCRS abstracts, 2015*.
9. Lavin CD CR, Arteaga JV, Cervero MAC, Suarez LC, Segarra MAS, Mardero OD, et al. 12 month results from a minimally-invasive, 45µm lumen ab interno gelatin stent in combination with a preoperative mmc from a multicenter study conducted in Spain. *World Glaucoma Congress; Hong Kong, 2015*.
10. Fernandez-Garcia A, Romero C, Garzon N. "Dry Lake" technique for the treatment of hypertrophic bleb following XEN((R)) Gel Stent placement. *Archivos de la Sociedad Espanola de Oftalmologia*. 2015; 90: 536-538.
11. Chen PP, Lin SC, Junk AK, Radhakrishnan S, Singh K, Chen TC. The Effect of Phacoemulsification on Intraocular Pressure in Glaucoma Patients: A Report by the American Academy of Ophthalmology. *Ophthalmology*. 2015; 122: 1294-1307.