

## Special Article - Cardiovascular Surgery

## Third Time Redo on Pump Beating Heart Mitral Valve Surgery via a Right Anterior Thoracotomy

Deser SB\* and Demirag MK

Department of Cardiovascular Surgery, Faculty of Medicine, Ondokuz Mayıs University, Samsun, Turkey

\*Corresponding author: Serkan Burc Deser, Department of Cardiovascular Surgery, Ondokuz Mayıs University, Medical Faculty, 55139 Samsun, Turkey

Received: May 20, 2016; Accepted: June 21, 2016;

Published: June 23, 2016

## Abstract

The rate of redo surgeries are increasing in patients with a history of coronary artery bypass graft surgery and valve replacement surgery due to the aging in the population, mechanical valve thrombosis or wearing out of the valves. Antero lateral thoracotomy and re sternotomy can be preferred for redo mitral valve surgery conventionally. Redo on pump beating heart mitral valve surgery via a right thoracotomy can be performed with the reasonable mortality rate and reduces the injury risk of patent grafts, adherent issues and ventricles. Lower mortality rate can be achieved with 'no touch technique' in high-risked patients with lower morbidity. Here we present third redo on pump beating heart mitral valve surgery via a right anterior thoracotomy.

**Keywords:** Redo; Surgery; Mitral valve; Thoracotomy

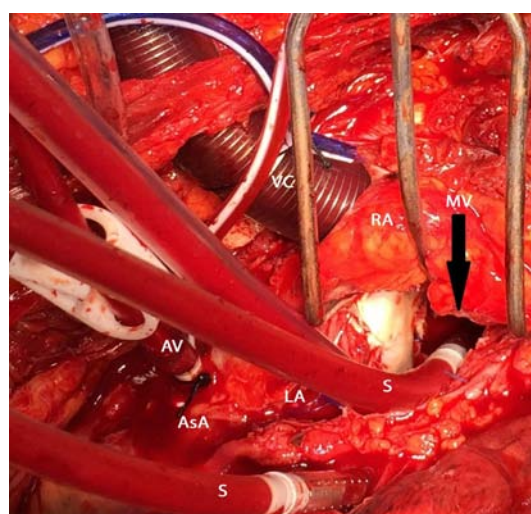
## Introduction

Mitral valve replacement surgeries have been performed since 1960's. Mechanical or bioprosthetic heart valves have an average 10-15 years lifespan. The rate of redo surgeries and mechanical valve thrombosis increase with the aging in the population and wearing out of the valves. Mitral valve surgery after previous open heart surgery is a surgical challenge. That may lead to two-three fold increase in the mortality and morbidity rather than primary surgery [1]. Anterolateral right/left thoracotomy and re sternotomy approaches can be used. However, conventional on pump median sternotomy approach may increase the risk of injury of the bypass grafts or cardiac structures. Redo on pump beating heart mitral valve surgery via a right thoracotomy is safer and reduces the injury risk of patent grafts, adherent issues and ventricles and also reduces the operation time, amount of blood loss and in hospital stay [2]. However, right pleural dissection in a redo surgery is an issue and often a surgical challenge. Patients with a history of previous mediastinitis and sternotomies, CABG with functioning grafts and previous aortic valve replacement (AVR) are the indications of thoracotomy approach.

## Case Presentation

A 30 years old female was presented with dyspnea who previously under gone three times mitral valve replacement surgery (New York Heart Association Functional Class II-III). The first mitral valve replacement surgery was performed for rheumatic heart disease for about 8 years ago (27mm mechanical valve (St. Jude Medical Inc, St Paul, MN, USA). The second and the third operations were performed 6 (27 mm mechanical valve (St. Jude Medical Inc, St Paul, MN, USA) and 4 years ago (27mm mechanical valve (St. Jude Medical Inc, St Paul, MN, USA), respectively due to valve thrombus. Patient terminated taking anti coagulant medication due to pregnancy despite the fact that she had two children which led to thrombosis on the mechanical mitral valve. That was the main reason for redo surgeries after the last three operations. A chest X-ray showed previously placed wires sternal and cardiomegaly. Transthoracic echocardiography revealed moderate mitral valve regurgitation, 20 mmhg of mean gradient and

thrombus on the atrial site of the valve. European System for Cardiac Operative Risk Evaluation II was 4.05%. On account of multiple time redo surgeries, we decided to perform mitral valve replacement surgery via right anterior thoracotomy. Routine preparation for surgery was made and informed consent was taken. External defibrillation pads were placed on the left anterior. Under general anesthesia with double lumen intubation, the patient was positioned with the right chest 30 degree elevated. A right anterior thoracotomy was performed through the fourth inter costals space. Cardio pulmonary bypass was initiated via right femoral artery for arterial cannulation and the right atrial appendage for venous cannulation. Continuous transesophageal echocardiography monitoring was provided during the surgery. The patient's body temperature was lowered to 20 centigrade celsius. Ascending aortic root cannulation was done and the patient was kept in the Trendelenburg (head-down



**Figure 1:** Perioperative view of the thrombosed previous mitral valve on the atrial site.  
(VC: Vena Cava; RA: Right Atrium; MV: Mitral Valve; AV: Aortic root Vent; LA: Left Atrium; S: Sucker; AsA: Ascending Aorta).

**Table 1:** Pros and cos for redo on pump beating heart mitral valve surgery.

Advantages	Disadvantages
Less bleeding	Depending on the surgeon's ability
Fewer blood transfusions	Single lumen ventilation
Avoidance of injury to cardiac structures or patent coronary bypasses in redo surgery	Use of femoral cannulation
Lower stroke risk	Groin complications (e.g., infections, arterial dissections/hematoma)
Avoidance of mediastinal infections and complications	
Fast recovery	
Important in elderly and debilitated patients	
No aortic clamping or manipulation for cannulation	
Decrease risk of ischemia-reperfusion injury	
Shorter length of hospital stay	

tilt) position to prevent air embolism. Cardiopulmonary bypass was performed without aortic cross-clamping which is known as the 'no-touch technique' due to severe adhesions [1]. The mean arterial perfusion pressure was maintained at over 40mmHg in order to keep the aortic valve closed. A longitudinal left atriotomy incision was performed. Due to the thrombus debris on it, previously replaced mechanical heart valve was almost stucked (Figure 1). Prosthetic valve was replaced with a 27mm mechanical valve (St. Jude Medical Inc, St Paul, MN, USA). Patients were weaned from cardio pulmonary bypass after rewarming. The operation was completed without any injury to the cardiac structures and blood loss was minimal. The heart was not fibrillated and neither aortic cross-clamping nor cardioplegia was required. Total cardiopulmonary bypass time was 87 minute. Total drainage was 550ml postoperatively.

## Discussion

Mitral valve surgery in the presence of multiple time previous sternotomy history is a surgical challenge for redo open heart surgeries. Redo procedures are technically more complex than the isolated first time valve operations. Lower mortality rate can be achieved with 'no touch technique' in high-risked patients with lower morbidity (Table 1). During standards sternotomy technique, dissection may lead to injury of cardiac structures [3]. Avoiding of excessive aortic manipulation and dissection reduces the risk of atheroma embolisation. Retrograde arterial perfusion via femoral artery cannulation reduces the risk of adverse neurologic event. Some authors stated that on pump beating heart surgery is superior to the hypothermic fibrillatory arrest and provides sufficient myocardial perfusion during diastole and has a threefold lower risks of stroke [4].

The right anterior thoracotomy approach provides good exposure of the mitral valve if there is not any previous pleural adhesions. Transapical transcatheter mitral valve in valve implantation is an alternative treatment however, dissection of ventricle is needed and there is a lack of follow up data in the literature [2]. The redo on pump beating heart mitral valve surgery provides a complete myocardial perfusion during diastole which maintains sufficient coronary perfusion to reduce myocardial ischemia and reperfusion injury. However, contraindications are including aortic regurgitation and a low ejection fraction. In conclusion, if aortic cross-clamping can not be used for redo surgeries, redo on pump beating heart mitral valve surgery via a right thoracotomy with the reasonable mortality rate can be performed compared to standard sternotomy.

## References

1. Kitamura T, Stuklis RG, Edwards J. Redo mitral valve operation via right minithoracotomy--"no touch" technique. *Int Heart J.* 2011; 52: 107-109.
2. Petracek MR, Leacche M, Solenkova N, Umakanthan R, Ahmad RM, Ball SK, et al. Minimally invasive mitral valve surgery expands the surgical options for high-risks patients. *Ann Surg.* 2011; 254: 606-611.
3. Kim HR, Kim GS, Yoo JS, Lee JW. Minimally invasive approach for redo mitral valve replacement: no aortic cross-clamping and no cardioplegia. *Korean J Thorac Cardiovasc Surg.* 2015; 48: 126-128.
4. Gammie JS, Zhao Y, Peterson ED, O'Brien SM, Rankin JS, Griffith BP J. Maxwell Chamberlain Memorial Paper for adult cardiac surgery. Less-invasive mitral valve operations: trends and outcomes from the Society of Thoracic Surgeons Adult Cardiac Surgery Database. *Ann Thorac Surg.* 2010; 90: 1401-1408, 1410.