Journal of Cardiovascular Disorders

Open Access

Austin Publishing Group

Case Report

A Rare Presentation of a Life- Threatening Condition Secondary to Masturbatory Activity: A Case Report

Ali Ridha[1]*, Shoaib Safiullah[2], Sarah Al-Abayechi[3], Ahmed Ghadai[4] and Amin Ur Rehman Nadeem[5]

[1]Chicago Medical School/Rosalind Franklin University of Medicine and Science, USA

[2]Chicago Medical School/Rosalind Franklin University of Medicine and Science, USA

[3]College of Medicine/Baghdad University, Iraq

[4]Chicago Medical School/Rosalind Franklin University of Medicine and Science, USA

[5]Chicago Medical School/Rosalind Franklin University of Medicine and Science, USA

***Corresponding author:** Ali Ridha, Chicago Medical School/Rosalind Franklin University of Medicine and Science, 3333 Green Bay Rd, North Chicago, IL 60064 USA, Tel: 979-422-5631; Fax: 224-610-3722; Email: alim.ridha@yahoo.com

Received: April 29, 2015; **Accepted:** May 07, 2015; **Published:** May 08, 2015

Abstract

Aortic dissection is a lethal condition. Coitus or masturbatory activity is one of the rarest risk factors for aortic dissection. The most frequent predisposing factors are chronic systemic hypertension, hereditary connective tissue diseases, and congenital aortic valve diseases. To our knowledge, this is the first reported case of aortic dissection after masturbatory activity. We report the case of a 67 year old man who developed sudden onset chest pain during masturbatory activity. This presentation was atypical in that his pain radiated to his upper abdomen and lower back with relatively equal blood pressure in both arms. Computed tomography angiography showed a type an aortic dissection that extended from the ascending aorta to the level of the origin of superior mesenteric artery. Patient was transferred to the operating room immediately with subsequent successful treatment. This case illustrates that aortic dissection may be added to the complications seen after acute onset of peri- or post-masturbatory activity severe chest pain.

Keywords: Aortic Dissection; Debakey Classification; Stanford Classification; Computed Tomography Angiography

Case Presentation

A 67 year-old Caucasian man presented on December 13, 2014 to the emergency department in North Chicago, Illinois with acute onset of chest pain that started on the morning of arrival while engaging in masturbatory activity. The pain was sharp, constant, 10/10 in severity, and located midsternal with radiation towards the upper abdomen and lower back. It was associated with nausea, diaphoresis and dyspnea. His past medical history was significant for hypertension controlled by diet and exercise, chronic obstructive pulmonary disease, and compensated alcoholic cirrhosis.

On physical examination, he was in acute distress, afebrile, anicteric, and not pale. Cardiovascular system examination revealed a regular rhythm with a rate of 90 bpm, and no radio-radial delay. He had normal first and second heart sounds with a loud A2 heard over the precordium. No murmurs or carotid bruits were appreciated. His blood pressure on the left arm was 109/66 mmHg and right arm 120/70 mmHg supine and standing positions. Respiratory rate was 24 breaths/ min and his chest was clear to auscultation and his temperature was 36°C. There were no neurological deficits. Laboratory findings were unremarkable. Electrocardiography and chest X-ray were normal. He was given a 500 mL intravenous normal saline bolus along with 325 mg aspirin. For his pain, he received 1mg hydromorphone IV and sublingual nitroglycerin, with subsequent decrease in pain to a 5/10 severity. Computed tomography angiography showed a 4·4 cm x 4·4 cm aneurysmal dilatation of the ascending thoracic aorta, with a type A dissection of the thoracic aorta extending from the aortic root (Figure 1) involving the entire thoracic aorta and upper abdominal aorta ending directly above the origin of the left renal artery. The dissection extended into the brachiocephalic artery and the proximal part of superior mesenteric artery (Figure 2). The patient was immediately transferred to the operating room per cardiothoracic surgeon recommendations on 12/13. During surgery, the aortic valve was interrogated and indicated only minimal aortic insufficiency and no frank aortic rupture; the tear site was found in the distal ascending aorta, proximal to the brachiocephalic artery. Under deep hypothermic circulatory arrest, repair was performed by transection of the aorta, hemiarch reconstruction, and aortic valve resuspension. A 30 mm graft was beveled and then sewn to the undersurface of the arch. Homeostasis was maintained during surgery with several rounds of blood products. Patient was then transferred to the intensive care unit for one day for close monitoring; he remained stable and then was transferred to the medical floor. He was then discharged on 12/17 to an extended care facility for cardiac rehabilitation and physical therapy for seven days; his stay was uncomplicated. He was subsequently discharged to home with plans to follow-up with cardiology.

Introduction

Aortic dissection is the separation of the aortic wall layers, allowing blood to enter the intima-media space with potential progression of the dissection. The risk of aortic dissection increases with blood pressure elevation and cardiac output, both of which increase with physical and emotional stress [1]. The incidence of acute aortic dissection in the general population is estimated to range from 2.6 to 3.5 per 100,000 person-years [2]. Propagation of the dissection can occur both distal and proximal to the initial tear, involving branch vessels and the aortic valve and entering the pericardial space which may lead to ischemia (coronary, cerebral, spinal, or visceral), aortic regurgitation, and cardiac tamponade [3]. We present a rare case in which the development of aortic dissection occurs during masturbatory activity.

Ridha et al. © All rights reserved

Citation: Ridha A, Safiullah S, Al-Abayechi S, Ghadai A and Nadeem AUR. A Rare Presentation of a Life-Threatening Condition Secondary to Masturbatory Activity: A Case Report. J Cardiovasc Disord. 2015;2(2): 1012.

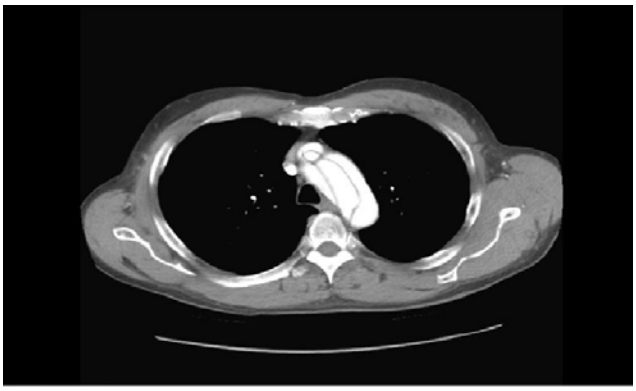

Figure 1: CT-angiography demonstrating aortic dissection at the level of ascending aorta and the aortic arch.

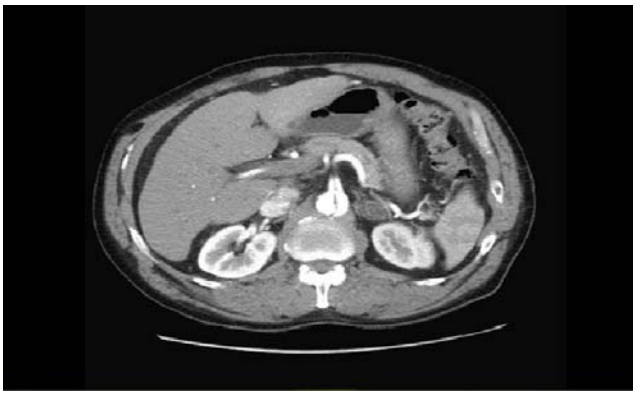

Figure 2: CT-angiography scan demonstrates aortic dissection extending into the superior mesenteric artery.

Discussion

Aortic dissection is a rare life threatening condition defined as a separation of the layers of the aortic wall due to extraluminal blood that has entered the aortic wall through an intimal tear. When blood enters through an intimal tear it passes longitudinally along the tunica media separating the intima from the adventitia [1].

Two different formats, the DeBakey and Daily (Stanford) systems, have been used to classify aortic dissection. DeBakeydivides dissections into 3 types: I– involving the ascending aorta and a variable amount of descending or thoraco-abdominal aorta; II – dissection limited to the ascending aorta; and III – dissection of the descending aorta either without (IIIa) or with (IIIb) involvement of the abdominal aorta. Stanford divides dissections into 2 types: A – all dissections involving ascending aorta, regardless of the site of origin; B – all dissections not involving the ascending aorta [4]. Our patient clearly had a DeBakey type I dissection and Stanford type A.

Patients with an aortic dissection typically present with severe, sharp or "tearing" posterior chest or back pain. Pain is most intense when the symptoms begin which in our patient occurred during masturbation. The localization of the pain is usually related to the region in which the intimal rupture occurs; if the tear is in ascending aortic dissection the pain is felt anteriorly, but if it is distal to the left subclavian artery it is felt in the back. Spreading of the pain maybe a sign of progressive dissection [5]. With a progressing dissection, risk of complications will be higher, such as: sudden

Cardiovascular collapse from cardiac tamponade secondary to pericardial effusion, or massive acute myocardial infarction from dissection of coronary arteries, usually the right coronary artery [6]. Aortic insufficiency may occur due to retrograde dissection into the aortic sinuses or annulus. A dissection may also be complicated by branch artery obstruction resulting in neurovascular deficits, such as stroke, ischemic neuropathy, paraplegia and paresis, limb ischemia, bowel ischemia, and renal failure [7].

It has been long known and well-documented that the human sexual response entails an increase in sympathetic nervous system activity. In particular, blood pressure has been demonstrated in one study to rise from a resting systolic value of 110 mmHg to 175 mmHg during ejaculation [8]. Other studies have noted similarly increased blood pressure values from baseline during sexual arousal, with peak blood pressures noted during orgasm [9]. This then raises the concern of the effects and consequences of these blood pressure changes in a person engaged in any sexual activity.

Numerous studies have also demonstrated a correlation between arterial blood pressure and increased aortic wall stress [10]. For instance, sudden death due to aortic dissection has been reported in athletes during strenuous exercise, possibly due to the significant transient systemic hypertension occurring during heavy weightlifting [11]. Certainly, other physical and emotional stresses can also result in acute hypertension, potentially leading to aortic dissection. We believe that our patient with the poor antihypertensive drug compliance, the persistent increase in arterial pressure caused enhanced aortic wall tension, and a further sudden increase of pressure on the aortic wall triggered by exertional masturbatory activity led to the intimal tear and consequent aortic dissection arising from the ascending aorta to the descending aorta.

Early recognition and management, including blood pressure control and surgery, are imperative. Furthermore, BP control should be continued following repair, as administration of beta-blockers has been shown to reduce the risk of late complications after repair of type A dissection [12].

Conclusion

Clinicians should maintain a high level of suspicion for aortic dissection in patients who present to the emergency department with complaints of non-traumatic severe low back pain after exertive activities such as coitus or masturbatory activity. Noninvasive diagnostic methods such as X-ray, computed tomography, echocardiography, or magnetic resonance imaging should be performed promptly to rule out aortic dissection. This case reminds us that aortic dissection is an uncommon, but emergent, diagnosis that must always be considered in exertional chest pain, regardless of the nature of the exertive activity.

Acknowledgment

This case report has received no specific grant from any funding agency in the public, commercial, or not-for-profit sectors. All the authors declare that there is no conflict of interest.

References

1. DeSanctis RW, Doroghazi RM, Austen WG, Buckley MJ. Aortic dissection. N Engl J Med. 1987; 317: 1060-1067.
2. Clouse WD, Hallett JW Jr, Schaff HV, Spittell PC, Rowland CM, Ilstrup DM, et al. Acute aortic dissection: population-based incidence compared with degenerative aortic aneurysm rupture. Mayo Clin Proc. 2004; 79: 176-180.
3. Nienaber CA, Eagle KA. Aortic dissection: new frontiers in diagnosis and management: Part I: from etiology to diagnostic strategies. Circulation. 2003; 108: 628-635.
4. Tsai TT, Nienaber CA, Eagle KA. Acute aortic syndromes. Circulation. 2005; 112: 3802-3813.
5. Hagan PG, Nienaber CA, Isselbacher EM, Bruckman D, Karavite DJ, Russman PL, et al. The International Registry of Acute Aortic Dissection (IRAD): new insights into an old disease. JAMA. 2000; 283: 897-903.
6. Baydin A, Nural MS, Güven H, Deniz T, Bildik F, Karaduman A. Acute aortic dissection provoked by sneeze: a case report. Emerg Med J. 2005; 22: 756-757.
7. Ogun SA, Adefuye B, Kolapo KB, Osalusi BS. Anterior spinal artery syndrome complicating aortic dissecting aneurysm: case report. East Afr Med J. 2004; 81: 549-552.
8. Fox CA, Fox B. Blood pressure and respiratory patterns during human coitus. J Reprod Fertil. 1969; 19: 405-415.
9. Exton MS, Krüger TH, Bursch N, Haake P, Knapp W, Schedlowski M, et al. Endocrine response to masturbation-induced orgasm in healthy men following a 3-week sexual abstinence. World J Urol. 2001; 19: 377-382.
10. Gao F, Watanabe M, Matsuzawa T. Stress analysis in a layered aortic arch model under pulsatile blood flow. Biomed Eng Online. 2006; 5: 25.
11. Elefteriades JA, Hatzaras I, Tranquilli MA, Elefteriades AJ, Stout R, Shaw RK, et al. Weight lifting and rupture of silent aortic aneurysms. JAMA. 2003; 290: 2803.
12. Zierer A, Voeller RK, Hill KE, Kouchoukos NT, Damiano RJ Jr, Moon MR. Aortic enlargement and late reoperation after repair of acute type A aortic dissection. Ann Thorac Surg. 2007; 84: 479-486.

J Cardiovasc Disord - Volume 2 Issue 2 - 2015
ISSN 2379-7991 | www.austinpublishinggroup.com
Ridha et al. © All rights reserved

Citation: Ridha A, Safiullah S, Al-Abayechi S, Ghadai A and Nadeem AUR. A Rare Presentation of a Life-Threatening Condition Secondary to Masturbatory Activity: A Case Report. J Cardiovasc Disord. 2015;2(2): 1012.