Journal of Cardiovascular Disorders

Open Access

Austin Publishing Group

Review Article

Measurement of Strain by Speckle Tracking: Its Current use in Medicine and in Animal Models

Alves FR[1]*, Pessoa GT[1], Rodrigues RPS[1], da Silva ABS[1], Moura LS[1], Alves JJRP[2], Macedo KV[3], Sousa FCA[4], Neves WC[1], Bezerra-Neto L[5] and Vieira MLC[6]

[1]Department of Veterinary Morphophysiology, Imaging Diagnosis of Veterinary Specialties – LABDIVE, Federal University of Piauí (UFPI), Teresina, PI, Brazil

[2]Coloproctology and Colorectal Surgery Service of the University Hospital, Federal University of Piauí, Teresina, PI, Brazil

[3]Health Science Post-Graduate Program, Federal University of Piauí (UFPI), Teresina, PI, Brazil

[4]Department of Medicine, Faculty of Medical Science, State University of Piauí, (UESPI), Teresina, PI, Brazil

[5]Cardiocenter Institute, Teresina, PI, Brazil

[6]Cardiopneumology Department, Heart Institute (Incor), University of São Paulo (USP), São Paulo, SP, Brazil

***Corresponding author:** Alves FR, Department of Veterinary Morphophysiology, Federal University of Piauí, UFPI, CEP 64049-550, Teresina, PI, Brazil

Received: July 13, 2017; **Accepted:** October 09, 2017; **Published:** October 16, 2017

Abstract

Echocardiography and Doppler techniques have revolutionized cardiovascular imaging and diagnosis, enabling the visualization of structures in real time and the determination of haemodynamic aspects, which have improved the accuracy of clinical diagnoses. Among these techniques, Tissue Doppler Imaging (TDI) was the pioneer in determining the speed of the contraction of myocardial fibres and was an important diagnostic tool that allowed for the non-invasive evaluation of the heart, including the quantification of regional or global myocardial function and the evaluation of myocardial motion. However, TDI has many limitations, which have led to its gradual replacement by other more sophisticated diagnostic methods, such as speckle tracking. Speckle tracking allows for the calculation and analysis of myocardial movement through acoustic markers that are superimposed onto two-dimensional ultrasonic images of the cardiac cycle. With this technique, it is possible to calculate the strain in various aspects of the analysed structure without an influence from the angle. This technique does not share the limitations of TDI and has been extensively used in medicine due to positive results in the evaluation of cardiac function and because it is an accurate diagnostic method that allows for the detection of subclinical cardiac lesions. However, despite the benefits, this technique has several limitations that should be considered when using speckle tracking for examination.

Keywords: Echocardiography; Technologies; Deformation; Speckles.

Introduction

Conventional echocardiography

Echocardiography is a cardiovascular evaluation tool that uses ultrasonographic techniques to diagnose and monitor cardiac abnormalities [1]. This is the method of choice for the evaluation of systolic and diastolic function and valvular lesions, including cases of insufficiencies, dysplasia and overload, as it exhibits good sensitivity for the identification of cardiac involvement in hypertensive patients. Echocardiographic evaluation allows for the accurate diagnosis of various heart diseases, such as valvular degeneration, cardiac deviations, thoracic masses, pleural and pericardial effusions, myocardial diseases, stenotic valve lesions and large vessels, as well as congenital and haemodynamic changes [2].

Echocardiographic images are obtained in three modes: the two-dimensional mode (B mode), the movement mode (M-mode) and the Doppler mode, with different modalities, including the spectral (pulsed and continuous), coloured and tissue (TDI – tissue Doppler imaging) modalities [3]. Two-dimensional evaluation enables real-time imaging, allowing for global and subjective analysis of the heart. The image obtained is that of a cut plane showing the anatomical structures in two dimensions [4]. The M-mode, by means of a graph, shows signs of different echogenicities based on the type and depth of the tissues, recording the movement of the heart through a timeline [5]. It is obtained by positioning the cursor line in the two-dimensional image of the heart onto the structure to be evaluated. The segment of the heart crossed by this line will be displayed as a graph that shows a function of time, where the structures that do not present movements are presented as straight lines, and those that move appear as wavy lines [6] (Figure 1).

Doppler echocardiography

Doppler techniques provide information on elements that are constantly moving; in the heart, these elements are red blood cells, which behave as reflecting bodies, thus allowing for the evaluation of the haemodynamic function of the heart [7]. In ultrasonography, the so-called Doppler effect is defined as the physical principle in which one can pick up differences in the frequency of reflected sound waves when reflector bodies move in relation to a sound source. In medicine, this effect is used during examination of the cardiovascular system. Red cells within the vessels produce different echo frequencies as they move away from or approach the ultrasound source, and this variation is captured and processed by the computer for image conversion [7].

Continuous Doppler was the first modality to emerge and be applied in the clinic, and it has the great advantage of capturing flows of any velocity since the transmission and reception of the echoes are uninterrupted [8]. The pulsatile Doppler was developed to map specific areas. The great advantage of this method is the possibility of evaluating a specific area, such as the atrioventricular valve to detect regurgitation [9]. However, it has limitations when measuring flows with high velocities, such as those that frequently occur with valvular diseases or stenosis [10]. The coloured Doppler appears as a coloured flow that is superimposed on a two-dimensional image.

Citation: Alves FR, Pessoa GT, Rodrigues RPS, da Silva ABS, Moura LS, Alves JJRP, et al. Measurement of Strain by Speckle Tracking: Its Current use in Medicine and in Animal Models. J Cardiovasc Disord. 2017; 4(2): 1037.

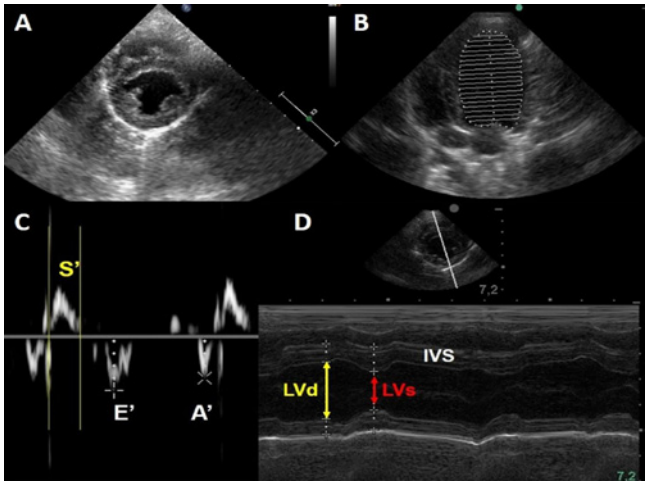

Figure 1: Echocardiographic assessment of left ventricle (LV) size and function in a normal canine animal model. (A) Parasternal short-axis acquired at the level of the papillary muscles. (B) Parasternal long-axis (apical four chambers view) used to acquire volume measurements based on tracings of the blood-tissue interface. (C) Tissue Doppler recordings of lateral mitral annular velocities. (D) Parasternal short-axis (level of the papillary muscles) to obtain linear internal measurements of the LV. ***Courtesy*:** Imaging Diagnosis of Veterinary Specialties – LABDIVE, UFPI, Teresina, PI, Brazil.

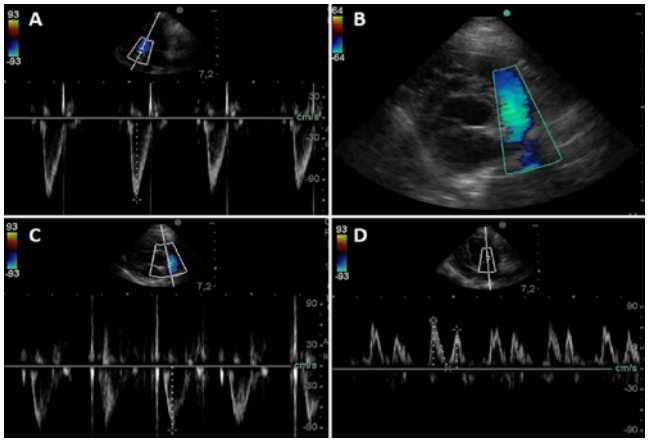

Figure 2: Example of echocardiography normal findings from a canine animal model. (A) Pulse wave doppler (PW) recording of left ventricular outflow track velocity obtained from apical four chambers view. (B-C) Parasternal short-axis used to obtain right ventricular outflow track velocity from the pulmonary artery. (D) A normal mitral inflow pattern. ***Courtesy*:** Imaging Diagnosis of Veterinary Specialties – LABDIVE, UFPI, Teresina, PI, Brazil.

The velocity with which the red blood cells approach or move away from the transducer is colour coded, and it has been decided that any flow approaching the transducer is represented by a red colour, and any flow away from the transducer is represented by a blue colour. Turbulent flows, in which the velocity of the erythrocytes varies, appear as a mosaic of colours [8] (Figure 2).

Tissue doppler

Fairly recently, a new modality called TDI was introduced in the clinic. The first published studies on this technique date from 1986 during a congress of the American College of Cardiology [11], where it was suggested that TDI had great potential for the evaluation of myocardial function. However, its improvement occurred about ten years later, around 1994, when the first scientific works on the spectral and colour Doppler examinations of myocardial movement began to be reported [12,13].

To perform TDI, the ultrasound equipment uses filters and special configurations to eliminate the low frequency and high amplitude noises originating from the ventricular wall, thus allowing for the evaluation of the displacement velocity of the myocardium from the detriment of blood flow. This allows for a better understanding of the systolic and diastolic functions of the heart, increases the accuracy of conventional Doppler examination and integrates regional function information to estimate global cardiac function, which is not significantly affected by variations in the pre-load conditions [10,14].

The intracardiac blood flows moves at high speeds, but they have a low amplitude; in contrast, the myocardium moves at a slower rate but at a greater amplitude. It is this inversion that the devices with the TDI feature can capture to measure the movement of the myocardial mass. As with the visual representation of blood flow, myocardial motion may be colour coded or spectral [15].

However, because it is a technique that uses the same principles of conventional Doppler, its limitations are also the same. The TDI requires the alignment of the cursor to be as parallel as possible to the assumed direction of the myocardial motion, making it impossible to perfectly evaluate all portions of the cardiac muscle. Moreover, it is strongly influenced by translational movement and is not able to differentiate between the active contraction of a normal segment and the passive contraction of a segment that is only moving at the expense of an adjacent normal muscular portion. These and other limitations cause TDI to be gradually replaced by other more advanced and more realistic methods that are independent of Doppler [10,14]. More recent technologies than TDI, such as speckle tracking, allow for a more accurate analysis of ventricular function. Speckle tracking enables the study of strain and strain rate through two-dimensional echocardiography and by evaluating deformation in the various cut planes.

Strain by Speckle Tracking (ST)

To understand the principles of advanced techniques in echocardiography, it is important to have an understanding of cardiac muscle conformation. The myocardium can be described as an incompressible tissue, which means that its longitudinal deformation is inversely proportional to the changes observed in its thickness; that is, the more the muscle lengthens, the more it decreases its thickness, and as it is shortened, its thickness increases. According to this principle, when measuring myocardial fibre elongation, it is possible to determine its degree of contractility [16].

The spiral arrangement of the myocardial band [17] is associated with the change of the direction of the fibres in the ventricular wall, and the laminar distribution of these fibres results in helical deformation following cardiac muscle contraction. This movement results in shortening between the base and the apex, the thickening of the walls, variation in the circumference of the cavity and slipping between the various layers of muscle [18]. However, this deformation is a complex process, and to be properly studied, it must be broken down into several planes, including the orthogonal and tangential planes [19] (Figure 3).

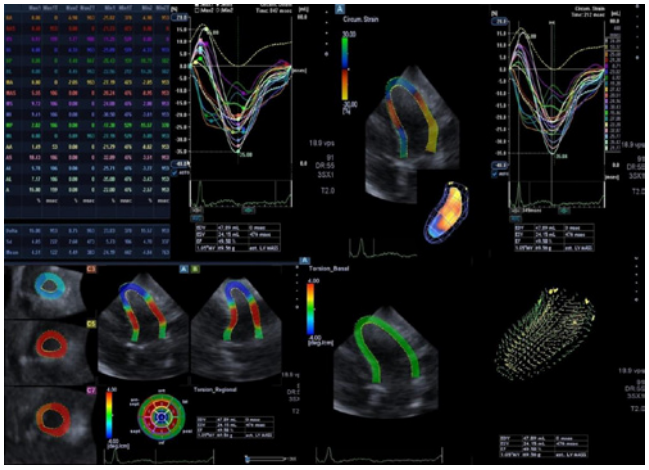

Figure 3: Advanced echocardiographic measurements (Three-Dimensional Myocardial Strain) in healthy human patients to demonstrate different ways of analysis of cardiac mechanics. ***Courtesy*:** Prof. Dr. Marcelo Luiz Campos Bezerra, Incor, São Paulo, Brazil.

In this context, the advanced techniques in cardiac imaging enable the quantification of the cardiac muscle deformities, which is referred to as strain, from the vectoral analysis of the different velocities in which two points in the myocardium move. The spatial gradient of the velocities obtained by the displacement of certain points in the myocardium during a cardiac cycle determines the rate of deformation or the strain rate of a certain muscle segment. Thus, the strain is obtained through the integration of the speed curves acquired in the strain rate [20,21].

The parameters of myocardial deformation are clinically relevant because it is an easy evaluation method, and thus, it has aroused great interest in the echocardiographic community. This has been reflected in the growing number of publications that have focused on all aspects of ST echocardiography, thus testing the potential clinical utility of this new modality [22].

Two-dimensional echocardiography with ST is one of the most recent and promising ultrasound tools that allows for the direct evaluation of cardiac function from standard echocardiographic images [23]. This technique is based on the tracking of points created by the interference between the sonographic beam and the myocardium that are superimposed on two-dimensional greyscale images. These speckles appear as small bright spots within the myocardium and represent natural tissue acoustic markers that can be monitored moment by moment throughout the cardiac cycle [23,24].

The displacement of these points generates a path, and each acoustic mark presents, in its course, instantaneous changes of speed and direction. These changes are represented by vectors that constantly change their size and direction. The movement of the speckle during the cardiac cycle follows the movement of the myocardium, thereby representing muscular deformation. Thus, ST has the advantage of assessing myocardial function independent of cardiac translation and insonation angle [25] (Figure 4).

The movement of each of these points can be demonstrated in graphs as a curve representing a function of time or strain rate in

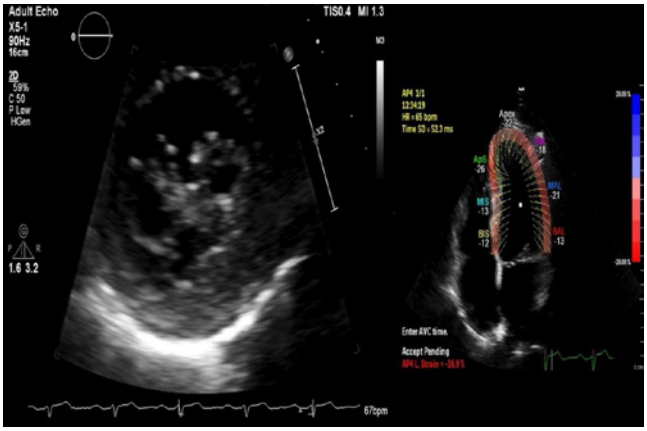

Figure 4: Two-dimensional Myocardial Strain – A Patient after Alfieri Mitral Valve Repair. ***Courtesy*:** Prof. Dr. Marcelo Luiz Campos Bezerra, Incor, São Paulo, Brazil.

units of s-1 or 1/s. In this type of chart, the movement is negative during systole because the cavity shortens, whereas during diastole, two positive waves are inscribed; these waves correspond to rapid filling and atrial contraction. The integral of the velocity of this curve represents the rate of deformation and is shown as a percentage with respect to the initial position of the point. In general, the end of diastole is represented by the peak of the QRS on an electrocardiogram [26].

For measurements of myocardial tension, it is more appropriate to measure the natural stress because the measured values are less dependent on the definition of the initial length. In the case of two-dimensional (2D) organs, deformation is not limited to stretching or shortening in one direction. A 2D object can stretch or shorten along the x or y-axis (normal strain) and can also distort (shear strain) from the relative displacement of the upper edge to the lower edge or the right edge to the left margin [27].

The path of the speckles can be analysed in several planes. Conventionally, the three orthogonal planes and at least two tangential planes are used. The orthogonal planes are perpendicular to each other, and the first orthogonal plane determines the deformation in the apical section in two, three or four chambers by measuring the shortening in the base-apex direction of the cavity, also known as the longitudinal strain. As the final length of the cavity (systole) is less than the initial length (diastole), the percentage of deformation is negative. The second orthogonal plane evaluates the thickening of the walls and is measured by the transverse section of the left ventricle, also known as the radial strain. As the final thickness (systole) is greater than the initial thickness (diastole), the percentage of the deformation is positive. The third orthogonal plane, which is also obtained in the short axis view, measures the change in the heart circumference, also known as the circumferential strain, and as the circumference is lower in systole than in diastole, the percentage of the deformation is negative [26].

The tangential planes measure the displacement between points located in the epicardium and the endocardium in the longitudinal (radial longitudinal shear strain) and transverse (circumferential radial shear strain) directions. There is also the longitudinal circumferential shear strain, which measures the transverse displacement of two

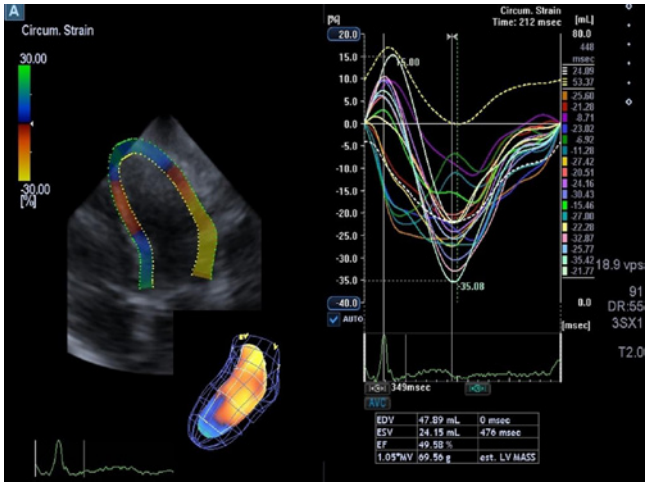

Figure 5: Circumferential strain (2D) in healthy human patients and myocardial parameters obtained by Three-Dimensional Myocardial Strain. ***Courtesy*:** Prof. Dr. Marcelo Luiz Campos Bezerra, Incor, São Paulo, Brazil.

points along the major axis of the cavity [28]. The measurement of the displacement of the points in the circumferential direction also allows for the estimation of rotation, which is expressed in degrees, and the rate of rotation, which is expressed in degrees per second. The opposition between the basal and apical rotation of the cavity in opposite directions, clockwise and counterclockwise, respectively, results in apical twisting; the measurement known as twisting is an important parameter for the evaluation of ventricular function [29] (Figure 5).

Commercial ultrasound devices that are used to perform speckle tracking obtain tracings using two methodologies, the ST method by block matching and tracking by optical flow. The ST method follows a group of pixels within a region of the image frame by frame. With each frame, the group of pixels that most closely resembles that of the previous frame is analysed. Optical flow tracking is based on the principle of conservation of the value in greyscale. This principle assumes that a grey value does not change with respect to time unless that pixel has moved to another location. After the speckles have been defined in the different captured cardiac axes, a software is used to trace the speckles by estimating the velocity vector of each pixel in the image. This procedure is then repeated frame by frame to quantify the strain, the strain rate and the speed of movement of the myocardial segment by vector analysis [19].

The interpretation of the results must take into consideration the factors that interfere in the global deformation of the myocardium, such as physiological factors (gender, age and patient weight) and technical factors (orientation of the imaging planes and the quality of the images in greyscale). In addition, universally accepted normal values are available for the different parameters of myocardial deformation, although several researchers have attempted to define the specific reference intervals for the different components of the deformation [30].

In summary, the myocardial velocities obtained in speckle marking tend to be reduced in the direction of the apex, with greater velocities at the level of the mitral annulus. Based on convention, the final diastolic length of the segment to be analysed is set to 100%, and the final diastolic strain is set as 0%. The axes of deformation acquire a differentiated characteristic in the case of longitudinal strain. Due to the greater concentration of longitudinal and oblique muscle fibres in the apical region, the percentage of deformation towards the apex tends to increase, with global values starting at -16.1% ± 3, 0% at the base and up to -22.0% ± 3.8% at the apex. In the same way, circumferential strain acquires a similar pattern as longitudinal stain; however, the percentage increase is more discrete, going from -22.1% ± 4.6% at the base to -26.5% ± 5.8% at the apex [31,32].

In contrast, the radial strain usually exhibits an inverse behaviour; that is, radial strain is reduced towards the apex. This is related to the higher concentration of circular fibres in the base, and thus, the overall values range from 37.4% ± 8.7% at the base to 31.0% ± 3.5% at the apex. These values may vary depending on the equipment, the technique used and the condition of the patient at the time of the examination [31,32].

Compared with TDI, echocardiography by ST stands out because it is not restricted to the angle of insonation, thereby allowing for the measurement of myocardial deformation in all planes, including the apical region of the ventricular cavity. In addition, the traced light points are represented by velocity vectors, which reveals the direction and intensity of the movement of a certain cardiac segment [26]. While TDI measures only the mean velocity of the longitudinal movement of the myocardium, TS quantifies longitudinal, radial and circumferential deformity.

However, this method also has some limitations that must be considered for better performance and interpretation of the clinical results. There is lateral resolution in distant myocardial regions in addition to the myocardial plane and reverberations. More importantly, the quality of the two-dimensional image must be perfect for the program to be able to perform its functions. This technique depends, for the most part, on the operator's experience. Image artefacts may be confused with points and will be tracked, which can affect the results. Thus, it is important for the echocardiographer to be able to distinguish artefacts from true points. Moreover, the devices that are capable of ST are still quite expensive, thus limiting this type of work [33]. The algorithms available for strain application differ among device manufacturers, and therefore, the available information disagrees on how the results compare or how physical assumptions differ between different programs [22].

Advanced methods have still been used for accurate assessment of the global left ventricle function. Thus, new tools for segmental cardiac evaluation, such as three-dimensional strain, have been widely discussed [34]. The study of three-dimensional blocks called *full volume* made possible the derivation of strain values from a single image acquisition, different from the two-dimensional strain that requires at least six image planes [35]. Based on *cubic models*, this new technology can evaluate all myocardial segmentation function in real time [36] (Figure 6).

The Measurement of Strain Using ST: Applicability

The determination of strain by ST has been intensively used in medicine and has obtained good results, which have been confirmed by more accurate tests, such as magnetic resonance and sonomicrometry

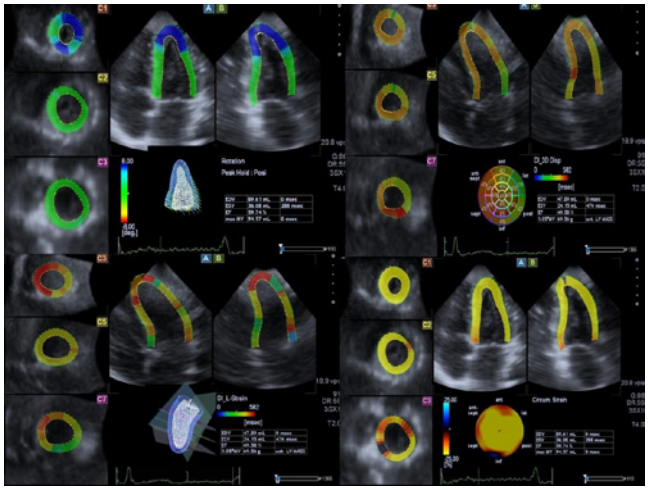

Figure 6: Echocardiographic examination evidencing parameters derived from three-dimensional strain for the analysis of cardiac mechanics in a healthy patient. *Courtesy*: Prof. Dr. Marcelo Luiz Campos Bezerra, Incor, São Paulo, Brazil.

[37,38]. The role of strain is to quantitatively measure left ventricular (LV) systolic function, which can accurately detect subtle changes in myocardial function. This tool has been used to obtain reference values in healthy patients and in carriers of different heart diseases [39].

Numerous studies have demonstrated the application of myocardial deformation analysis in the clinic, where its use is increasing every day due to its positive results. These studies aimed to test the effectiveness of strain measurements for the early diagnosis and monitoring of diverse cardiopathies. This technique can be used for differential diagnosis in cases of secondary genetic and athlete hypertrophy, for early identification of changes in segmental contractility among patients with Chagas disease and for the identification of ischaemic areas with or without electrocardiogram conduction disturbances. It also allows for the assessment of myocardial viability without the need for pharmacological stimulation and for systolic function evaluation in patients with volume overload and cardiac synchronization, among others [22].

In ischaemic diseases, strain is an important ally since the degree of cardiac deformation is affected by the size and transmural extension of the affected area, although it may change during the first month after the acute ischaemic event [40]. In these cases, both segmental and global strain will be reduced in all directions, including transmurally, based on scar extension [41,42]. In addition, two-dimensional speckle tracking is useful for identifying patients in the acute phase of infarction without ST segment elevation, to the electrocardiogram, allowing a previous treatment [43]. Recent research has shown that the global strain assessed in old infarcts was a better predictor of adverse cardiovascular events than ejection fraction (LVEF) and left ventricular wall motion index (LMI) [44].

Despite the limitations, several studies have concluded that strain, as determined by ST, has value in detecting changes in LV myocardium mechanics, allowing for the identification of coronary stenosis with good sensitivity and acceptable specificity [45]. It has been demonstrated that in patients with heart failure, longitudinal global strain by 2D-ST is a prognostic technique that is superior to the measurement of ejection fraction and TDI; in addition, it exhibits a higher correlation with the measurement of ejection fraction by magnetic resonance than by the Simpson's method using bidimensional echocardiogram [46].

Another application of strain measurements is the identification of early alterations in LV segmental contractility in the indeterminate forms of Chagas disease when they are not yet detectable by conventional echocardiography; in addition, strain measurements can provide data on the pathophysiology of the disease in the heart [22]. Studies that have measured myocardial strain in patients with Chagas disease have concluded that the percentage of contraction of the various myocardial segments, both radially and longitudinally, is higher in normal individuals than in patients with the chronic form or the indeterminate form of Chagas disease. The radial contractility of the left ventricle was greater than the longitudinal contractility of the left ventricle in these patients at all stages of the disease [47].

Systemic arterial hypertension induces changes in LV structure, which occurs in different patterns, including concentric remodelling, concentric hypertrophy (CH) and eccentric hypertrophy [48]. These changes can be detected by the longitudinal strain, which is reduced in patients with these types of alterations [49].

Studies on patients with hyper- or hypothyroidism have shown that these alterations are associated with reduced LV longitudinal and circumferential strain. This is because patients with these disorders may develop systolic and diastolic dysfunction as well as increased LV mass in addition to cardiac arrhythmias [50].

The use of strain in cardio-oncology deserves distinction. More than half of the patients exposed to anthracyclines will develop detectable cardiac dysfunction 10 to 20 years after chemotherapy, and 5% of them will progress to apparent HF [51]. According to the I Cardio-Oncology Guideline, echocardiographic follow-up of patients taking cardiotoxic drugs should be done prior to the first cycle of chemotherapy; after half the cumulative total dose has been administered or after specific doses of anthracyclines or equivalent drugs; and after each subsequent cycle of chemotherapy [52]. The LV ejection fraction should not decrease by more than 10% compared to the pre-chemotherapy value or should not have an absolute value lower than 50% (53% according to the ASE guideline) [53]; otherwise, the chemotherapy treatment may need to be terminated [52]. However, the LV ejection fraction is not sensitive enough to identify anthracycline-induced cardiotoxicity [54]. In this scenario, the use of ST is very promising, as it may identify myocardial lesions before there are detectable changes in ejection fraction values. The reduction of the longitudinal strain value within three months of chemotherapy among breast cancer patients treated with anthracycline and trastuzumab and the level of high-sensitivity troponin were independent predictors of cardiotoxicity in six months. LV ejection fraction, NT-pro BNP and diastolic dysfunction parameters were not able to predict cardiotoxicity [55]. The ASE/EACVI guideline and the European Society of Cardiology agree that a drop of more than 15% in overall longitudinal strain compared to the pre-chemotherapy examination without the presence of a decrease in ventricular ejection fraction is very suggestive of subclinical ventricular dysfunction;

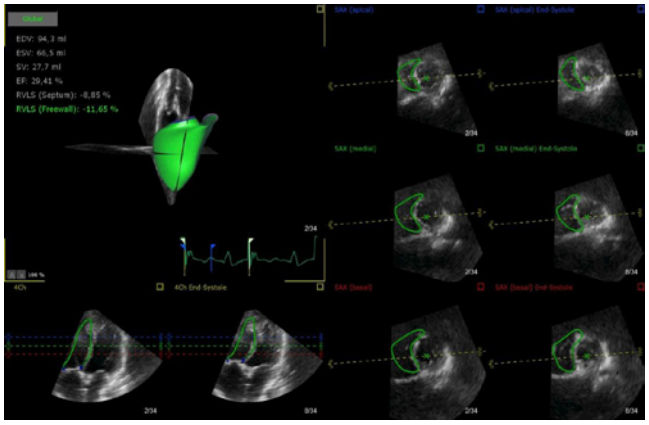

Figure 7: Echocardiographic examination showing volumes measurements (3D), ejection fraction (3D), septal strain (2D) and right ventricular free wall strain (2D) in a human patient with schistosomiasis. A decrease in ejection fraction and strain measurements is observed. *Courtesy*: Prof. Dr. Marcelo Luiz Campos Bezerra, Incor, São Paulo, Brazil.

however, reductions of up to 8% are considered tolerable, with no indication of discontinuation of treatment [53,56] (Figure 7).

In hypertrophic cardiomyopathy, the evaluation of strain is of great importance. A global longitudinal strain reduction greater than 10.6% (mean values obtained on the septal, lower, lateral and anterior walls) had a sensitivity of up to 85% and a specificity of 100% for the detection of hypertrophic cardiomyopathy. In several segments in the hypertrophied regions, it was possible to observe positive longitudinal strain in up to 55% of the cases [57]. In cardiac amyloidosis, early detection of the involvement of longitudinal fibres by the reduction of overall longitudinal strain generally leads to a classic pattern of reduction in more apical segments with preservation of mid-basal segments. In other systemic diseases that occur with heart disease, such as Duchenne muscular dystrophy, systemic sclerosis, thalassemia and Friedreich ataxia, [58], global longitudinal strain is promising for the early evaluation of cardiac dysfunction in these patients.

The Measurement of Strain Using ST on Animal Models

More recently, strain by ST has been incorporated into veterinary medicine in experiments using different animal species. These studies have demonstrated numerous similarities in the parameters of cardiac function between animals and humans. Thus, the study of strain in animal models may be an option for research aimed at the diagnosis and treatment of cardiac diseases that affect humans.

Currently dogs have been widely used as models for studies of the cardiovascular system, the respiratory system, the gastrointestinal system, the endocrine system and transplant techniques. Additionally, primates, as they closely resemble humans, are susceptible to many of our diseases.

The advantages of experiments with animal models are easy maintenance and observation; the possibility of working with a very large number of individuals; short life cycles; the ability to perform a controlled analysis at any stage of the disease; and the ability to standardize the genetic background and the environment. Furthermore, it is possible to evaluate the natural progression of a

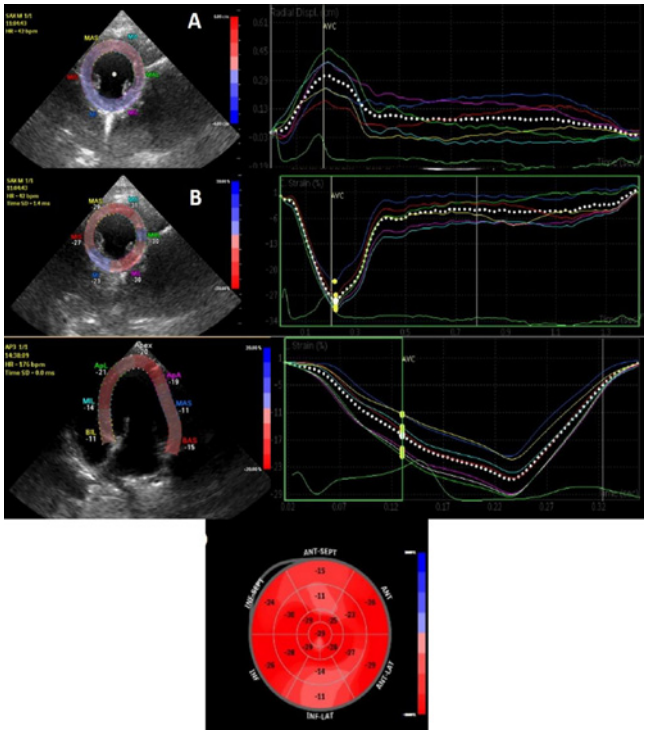

Figure 8: Echocardiographic examination evidencing radial, circumferential and longitudinal strain of canine animal model with mitral myxomatous degeneration. Note a significant deficit of segmental contractility in the anteroseptal, mid anteroseptal, mid inferolateral and especially in the inferolateral segments. *Courtesy*: Imaging Diagnosis of Veterinary Specialties – LABDIVE, UFPI, Teresina, PI, Brazil.

disease by examining animals exposed to the natural cycle, and it is possible to measure the pathogenicity of a pathogen in its natural environment [59].

The evaluation of the strain by ST was recently incorporated in veterinary medicine to aid the determination of a definitive diagnosis and to determine the prognosis of the cardiac alterations; up until then, the technique was limited to research. Numerous results from strain analysis in dogs and cats have been demonstrated [23]. ST has been used as a tool in the echocardiographic studies of animals with Duchenne muscular dystrophy, hypertrophic cardiomyopathy [60], chronic mitral valve degeneration [61,62] and dilated cardiomyopathy [63].

In dogs, chronic myxomatous degeneration of the mitral valve is the most prevalent among the valvular heart diseases [25,64]. Thus, ST is used to verify left cardiac remodelling, the main result from this cardiopathy, and to predict cardiovascular events from other affections. An important observation that can be obtained with this tissue echocardiographic tool is segmental shortening, which may suggest the presence of heart disease [62]. Animals that have congestive heart failure associated with the chronic myxomatous degeneration of the mitral valve can exhibit alterations in strain, as determined using the ST variables, and in TDI at both diastole and systole compared to healthy animals [65] (Figure 8).

In cats, an important cardiopathy that is diagnosed and evaluated using the ST method is hypertrophic cardiomyopathy. Researchers

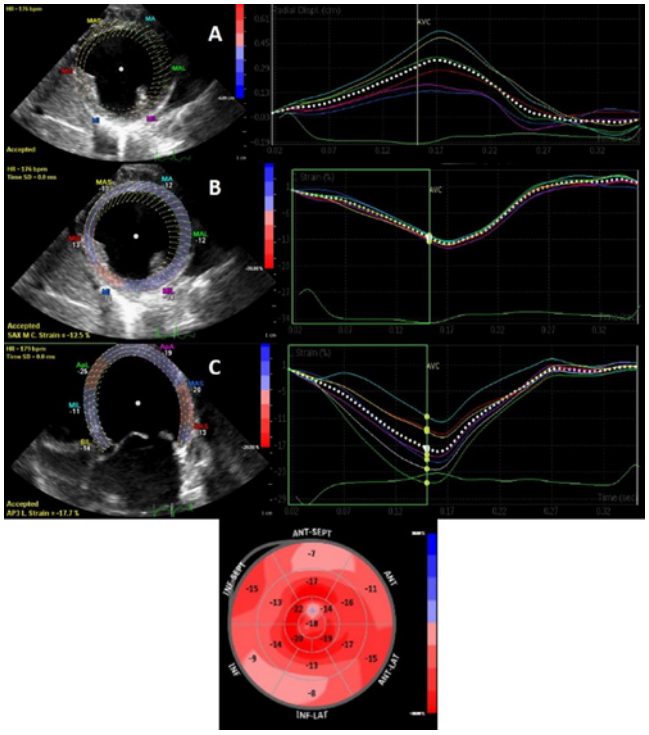

Figure 9: Echocardiographic examination evidencing radial, circumferential and longitudinal strain of canine animal model with dilated cardiomyopathy. Note a significant deficit of segmental contractility in the anteroseptal, basal inferior, inferolateral, mid inferolateral and significant decrease in contractility of apical segments. *Courtesy*: Imaging Diagnosis of Veterinary Specialties – LABDIVE, UFPI, Teresina, PI, Brazil.

have observed that the E wave of the radial and circumferential strain rate is decreased in sick cats compared with that of healthy cats. In addition, a correlation was observed between myocardial segment thickness and ST variables, demonstrating that this tool is clinically feasible to evaluate myocardial function in this species [60].

In veterinary medicine, dilated cardiomyopathy is among the major myocardial changes in large-breed dogs. It is characterized by the progressive dilation of the ventricular wall, leading to loss of contractility and deleterious effects on the organism due to congestive heart failure [66] as well as sudden death as a consequence of arrhythmias in severely affected animals [67]. The main cardiac alteration observed is atrial fibrillation, which is responsible for the occurrence of tachycardia, myocardial degeneration and death [66]. Thus, the use of ST is considered a complementary tool for early diagnosis and for the optimization of the therapeutic protocol [68].

Clinicians and researchers have used this method to confirm the diagnosis of dilated cardiomyopathy and to analyse the recommended treatment. Researchers evaluated the use of ST prior to the diagnosis of cardiomyopathy and at 16 weeks and 15 days after the initiation of treatment, and they observed a reduction in the internal dimensions of the left chambers together with an increase in contractility in diseased dogs [68].

Myocardial deformities induced by congenital anomalies in animals can also be observed using the ST method. Researchers showed a slight preference for ST for the early diagnosis of patent ductus arteriosus persistence compared to the conventional Doppler echocardiography technique, as the alterations in myocardial deformation caused by the PDA are restricted to the left ventricle, which is in contrast to the vascular effects [69]. However, additional studies are required to determine the reliability of this tool in patients with cardiomyopathies and to determine its influence on veterinary therapy.

The results showed that despite the use of sedation for restraint, the rate of cardiac deformation in *Cebus apella* was similar to that in humans (-17±5.5%) (Linnaeus, 1758). Thus, given the similarities in the parameters of left heart function between the tufted capuchins and humans, these animals have the potential to be explored in cardiology preclinical studies [70-72].

However, this strategy also has drawbacks, such as limited basic information on many species, difficulty in maintaining laboratories and biological risks [13], all of which contribute to the challenges in animal research.

Conclusion

Due to the positive results observed in numerous studies, the echocardiographic measurement of strain by ST has been shown to be a promising technique for the evaluation of cardiovascular diseases. However, additional studies are required to reduce the limitations of this technology in order to unify and further popularize its results.

References

1. Morcerf, FAP. Ecocardiografia uni-bidimensional, transesofágica e doppler. 2nd editio. Rio de Janeiro: Revinter. 1996.
2. Póvoa R, Souza D. Análise crítica do eletrocardiograma e do ecocardiograma na detecção da hipertrofia ventricular esquerda. Revista Brasileira de Hipertensão. 2008; 15: 81-89.
3. Boon JA. Veterinary echocardiography. 2nd edition. West Sussex: Wiley Blackwell. 2011.
4. Jaudon JP, Perrot C, Viaud F. Bases físicas, tecnológicas e semiológicas da ultra-sonografia clínica. A Hora Vet. 1991; 11: 10-16.
5. Henik 26RA. Echocardiography and Doppler ultrasound. Em: Miller MS, Tilley LP. (Editors). Manual of canine and feline cardiology. 2nd edition. Philadelphia: Saunders. 1995.
6. Bonagura JD. Echocardiography. J Am Vet Med Associ. 1994; 204: 516-522.
7. Feigenbaum, H. Instrumentation. In: Echocardiography. 4th edition. Philadelphia: Lea & Febiger. 2015.
8. Carvalho CF, Tudury EA, Neves IV, Fernandes THT, Gonçalves LP, Salvado RRCL. Eletrocardiografia pré-operatória em 474 cães. Arq Bras Med Vet Zoo. 2009; 61: 590-597.
9. Abduch MCD. Ecocardiografia. In: Ultrassonografia Doppler em pequenos animais. Carvalho CF. São Paulo: Roca. 2009.
10. Feliciano MAR, Canola JC, Vicente WRR. Diagnóstico por imagem em cães e gatos. 4th edition. São Paulo: MedVet. 2015.
11. Isaaz K, Cloez JL, Ethevenot JG, Danchin N, Perrot B, Pernot C. Analysis of left ventricular wall motion by pulsed Doppler echocardiography. Application to the assessment of myocardial function. J Am Coll Cardiol. 1986; 7: 228.
12. McDicken WN, Sutherland GR, Moran CM, Gordon LN. Colour Doppler velocity imaging of the myocardium. Ultrasound Med Biol. 1992; 18: 651-654.
13. Sutherland GR, Stewart MJ, Groundstroem KW, Moran CM, Fleming A, Guell-Peris FJ, et al. Color Doppler myocardial imaging: a new technique for the assessment of myocardial function. J Am Soc Echocardiogr. 1994; 7: 441-458.

14. Yu CM, Lin H, Yang H, Kong SL, Zhang Q, Lee SW. Progression of systolic abnormalities in patients with "isolated" diastolic heart failure and diastolic dysfunction. Circulation. 2002; 105: 1195-1201.

15. Waggoner AD, Bierig SM. Tissue Doppler imaging: A useful echocardiographic method for the cardiac sonographer to assess systolic and diastolic ventricular function. J Am Soc Echocardiogr. 2001; 14: 1143-1152.

16. Heimdal A, Stoylen A, Torp H, Skjaerpe T. Real-time strain rate imaging of the left ventricle by ultrasound. J Am Soc Echocardiogr. 1998; 11: 1013-1019.

17. Torrent-Guasp F. La estructura macroscópica delmiocardio ventricular. Rev Esp Cardiol. 1980; 33: 265-287.

18. Del Castillo JM, Herszkowicz N, Boschilia T, Capuano RL, Cortese MDS. Deformação miocárdica tangencial (shear strain) em indivíduos normais: o seu significado. Ver Bras Ecocardiogr Imagem Cardiovasc. 2009; 22: 20-26.

19. D'hooge J, Bijnens B, Thoen J, Van de Werf F, Sutherland GR, Suetens P. Echocardiographic strain and strain-rate imaging: a new tool to study regional myocardial function. IEEE Trans Med Imaging. 2002; 21: 1022-1030.

20. D'Hooge J, Heimdal A, Jamal F, Kukulski T, Bijnens B, Rademakers F, et al. Regional strain and strain rate measurements by cardiac ultrasound: principles, implementation and limitations. Eur J Echocardiogr. 2000; 1: 154-170.

21. Mario K, Aleksandrov A, Escher F, Al-Saadi N, Makowski M, Spillmann F, et al. Multimodality imaging approach in the diagnosis of chronic myocarditis with preserved left ventricular ejection fraction (MCpEF): The role of 2D speckle-tracking echocardiography. Int J Cardiol. 2017.

22. Almeida ALC, Gjesdal O, Mewton N, Choi E, Teixido-Tura G, Yoneyama K, et al. Speckle Tracking Echocardiografy – Clinical Applications. Rev Bras Ecocardiogr Imagem Cardio. 2013; 26: 38-49.

23. Chetboul V. Advanced techniques in echocardiography in small 316 animals. Vet Clin North Am Small Anim Pract. 2010; 40: 529-543.

24. Hooge J. Principles and different techniques for speckle tracking. In: Marwick TH, Yu C, M, Sun JP (Editors). Myocardial imaging: tissue Doppler and speckle tracking. Massachusetts: Blackwell, 2007; 17-25.

25. Toaldo MB, Romito G, Guglielmini C, Diana A, Pelle NG, Contiero B, et al. Assessment of Left Atrial Deformation and Function by 2-Dimensional Speckle Tracking Echocardiography in Healthy Dogs and Dogs WithMyxomatous Mitral Valve Disease. J Vet Intern Med. 2017; 31: 641-649.

26. Del Castillo JM, Herszkowicz N. Strain bidimensional (X-Strain): utilização do método para avaliação de cardiopatias. Ver Bras Ecocardio. 2008; 21: 29-35.

27. Yue Y, Clark Jr, John W, Khoury, Dirar S. Speckle tracking in intracardiac echocardiography for the assessment of myocardial deformation. IEEE Trans Bio Eng. 2009; 56: 416-425.

28. Nottin S, Doucende G, Schuster-Beck I, Dauzat M, Obert P. Alteration in left ventricular normal and shear strains evaluated by 2-D strain echocardiography in the athlete's heart. J Physiol. 2008; 586: 4721-4733.

29. Kim HK, Sohn DW, Lee SE, Choi SY, Park JS, Kim YJ, et al. Assessment of left ventricular rotation and torsion with two-dimensional speckle tracking echocardiography. J AmSocEchocardiogr. 2007; 20: 45-53.

30. Blessberger H, Binder T. Two dimensional speckle tracking echocardiography: basic principles. Heart. 2010; 96: 716-722.

31. Dalen H, Thorstensen A, Aase SA, Ingul CB, Torp H, Vatten LJ, et al. Segmental and global longitudinal strain and strain rate based on echocardiography of 1266 healthy individuals: the HUNT study in Norway. Eur J Echocardio. 2010; 11: 176-183.

32. Feigenbaum H, Mastouri R, Sawada S. A practical approach to using strain echocardiography to evaluate the left ventricle. Circ J. 2012; 76: 1550-1555.

33. Pavlopoulos H, Nihoyannopoulos P. Strain and strain rate deformation parameters: from tissue Doppler to 2D speckle tracking. Int J Cardio Imaging. 2008; 24: 479-491.

34. Xu C, Pilla JJ, Isaac G, Gorman JH 3rd, Blom AS, Gorman RC, et al. Deformation analysis of 3D tagged cardiac images using an optical flow method. J Cardiovasc Magn Reson. 2010; 12: 19-25.

35. Zhong X, Spottiswoode BS, Meyer CH, Kramer CM, Epstein FH. Imaging three-dimensional myocardial mechanics using navigator-gated volumetric spiral cine DENSE MRI. Magn Reson Med. 2010; 64: 1089–1097.

36. Zamorano JL, Lancellotti P, Rodriguez Muñoz D, Aboyans V, Asteggiano R, Galderisi M, Habib G, Lenihan DJ, Lip GY, Lyon AR, Lopez Fernandez T, Mohty D, Piepoli MF, Tamargo J, Torbicki A, Suter TM. 2016 ESC position paper on cancer treatments and cardiovascular toxicity developed under the auspices of the ESC Committee for Practice Guidelines. Eur Heart J. 2016; 37: 2768–2801.

37. Amundsen H, Helle-Valle T, Edvardsen, T, Torp H, Crosby J, Lyseggen E, et al. Noninvasivemyocardial strain measurement by speckle tracking echocardiography:Validation against sonomicrometry and tagged magnetic resonance imaging. J Am Coll Cardiol. 2006; 47: 789-793.

38. Goffinet C, Chenot F, Robert A, Pouleur AC, Le Polain de Waroux JB, Vancrayenest D, et al. Assessment of subendocardial vs. subepicardial left ventricular rotation and twist using two-dimensional speckle tracking echocardiography: comparison with tagged cardiac magnetic resonance. European Heart Journal. 2009; 30: 608-617.

39. Takamura T, Bensaid A, Dussault C, Macron L, Clémence D, Bouhemad B, et al. Reversible left ventricular regional non-uniformity quantified by speckle-tracking displacement and strain imaging in patients with acute pulmonary embolism. J Am Soc Echocardio. 2011; 24: 792-802.

40. Gupta KB, Ratcliffe MB, Fallert MA, Edmunds LH, Bogen DK. Changes in passive mechanical stiffness of myocardial tissue with aneurysm formation. Circulation. 1994; 89: 2315-2326.

41. Becker M, Hoffmann R, Kuhl HP, Grawe H, Katoh M, Kramann R, et al. Analysis of myocardial deformation based on ultrasonic pixel tracking to determine transmurality in chronic myocardial infarction. Eur Heart J. 2006; 27: 2560-2566.

42. Chan J, Hanekom L, Wong C, Leano R, Cho GY, Marwick TH. Differentiation of subendocardial and transmural infarction using two-dimensional strain rate imaging to assess short-axis and long-axis myocardial function. J Am Coll Cardiol. 2006; 48: 2026-2033.

43. Eek C, Grenne B, Brunvand H, Aakhus S, Endresen K, Smiseth OA, et al. Strain echocardiography predicts acute coronary occlusion in patients with non-st-segment elevation acute coronary syndrome. Eur J Echocardiogr. 2010; 11: 501-508.

44. Antoni ML, Mollema SA, Delgado V, Atary JZ, Borleffs CJ, Boersma E, et al. Prognostic importance of strain and strain rate after acute myocardial infarction. Eur Heart J. 2010; 31: 1640-1647.

45. Li L, Zhang PY, Ran H, Dong J, Fang LL, Ding QS. Evaluation of left ventricular myocardial mechanics by threedimensional speckle tracking echocardiography in the patients with different graded coronary artery stenosis. 2017; 1-8.

46. Nahum J, Bensaid A, Dussault C, Macron L, Clémence D, Bouhemad B, et al. Impact of longitudinal myocardial deformation on the prognosis of chronic heart failure patients. Circ Cardiovasc Imaging. 2010; 3(3): 249-256.

47. Silva CES, Ferreira LDC, Peixoto LB, Monaco CG, Gil MA, Ortiz J, et al. Avaliação da contratilidade segmentar na doença de Chagas utilizando a integral do gradiente intramiocárdico de velocidade (strain miocárdico) obtida pela ecocardiografia com Doppler tecidual. Arq Bras Cardiol. 2005; 84: 285-291.

48. Baker B, O'Kelly B, Szalai JP, Katic M, McKessock D, Ogilvie R, et al. Determinants of left ventricular mass in early hypertension. Am J Hypertens. 1998; 11: 1248-12451.

49. Kouzu H, Yuda S, Muranaka A, Doi T, Yamamoto H, Shimoshige S, et al. Left ventricular hypertrophy causes different changes in longitudinal, radial, and circumferential mechanics in patients with hypertension: A two-dimensional speckle tracking study. J Am Soc Echocardiogr. 2011; 24: 192-199.

50. Kahaly GJ, Dillmann WH. Thyroid hormone action in the heart. Endocr Rev. 2005; 26: 704-728.

51. Steinherz LJ, Steinherz PG, Tan CT, Heller G, Murphy ML. Cardiac toxicity 4 to 20 years after completing anthracycline therapy. JAMA. 1991; 266: 1672-1677.

52. Kalil-Filho R, Hajjar LA, Bacal F, Hoff PM, Diz M Del P, Galas FRBG, et al. I Diretriz brasileira de cardio- oncologia da Sociedade Brasileira de Cardiologia. Arq Bras Cardiol. 2011; 96: 1-52.

53. Plana JC, Galderisi M, Barac A, Ewer MS, Ky B, Scherrer-Crosbie M, et al. Expert consensus for multimodality imaging evaluation of adult patients during and after cancer therapy: a report from the American Society of Echocardiography and the European Association of Cardiovascular Imaging. J Am Soc Echocardiogr. 2014; 27: 911-939.

54. Eidem BW. Identification of anthracycline cardiotoxicity: Left ventricular ejection fraction is not enough. J Am Soc Echocardiogr. 2008; 21: 1290-1292.

55. Sawaya H, Sebag IA, Plana JC, Januzzi JL, Ky B, Cohen V, et al. Early detection and prediction of cardiotoxicity in chemotherapy-treated patients. Am J Cardiol. 2011; 107: 1375–1380.

56. Zamorano JL, Lancellotti P, Rodriguez Muñoz D, Aboyans V, Asteggiano R, Galderisi M, et al. ESC Position Paper on cancer treatments and cardiovascular toxicity developed under the auspices of the ESC Committee for Practice Guidelines. The Task Force for cancer treatments and cardiovascular toxicity of the European Society of Cardiology. Eur Heart J. 2016; 37: 2768-2801.

57. Kato, TS, Noda A, Izawa H, Yamada A, Obata K, Nagata K, et al. Discrimination of nonobstructive hypertrophic cardiomyopathy from hypertensive left ventricular hypertrophy on the basis of strain rate imaging by tissue Doppler ultrasonography. Circulation. 2004; 110: 3808-3838.

58. Belém, LHJ, Salgado A, Felix A, Nascimento C. In: Ecocrdiografia atual, manual de novas tecnologias 1st edition. Rio de Janeiro. DiLivros. 2011.

59. Andrade A, Pinto SC, Oliveira RS. Animais de Laboratório: o criação e experimentação. 1° edn. Rio de Janeiro: Editora FIOCRUZ. 2002.

60. Takano H, Fujii Y, Yugeta N, Takeda S, Wakao Y. Assessment of left ventricular regional function in affected and carrier dogs with duchenne muscular dystrophy using speckle tracking echocardiography. BMC Cardiovascular Disorders. 2011; 11: 2-8.

61. Chetboul, V. Tissue Doppler imaging: a promising technique for quantifying regional myocardial function. Journal of Veterinary Cardiology. Bern. 2002; 2:7-12.

62. Smith DN, Bonagura JD, Culwell NM, Schober KE. Left Ventricular function quantified by myocardial strain imaging in small-breed dogs with chronic mitral regurgitation. J Vet Cardiol. 2012; 1: 231- 242.

63. Alvarez AG, Sitges M, Regueiro A, Poyatos S, Pinazo M J, Posada E, et al. Myocardial Deformation Analysis in Chagas Heart Disease With the Use of Speckle Tracking Echocardiography. J Card Fail. 2011; 12: 1028-1034.

64. Zois NE, Olsen NT, Moesgaard SG, Rasmussen CE, Falk T, Häggström J, et al. Left ventricular twist and circumferential strain in dogs with myxomatous mitral valve disease. J Vet Int Med. 2013; 4: 875-883.

65. Tidholm A, Ljungvall I, Hoglund AB, Westling AB, Haggstrom J. Tissue Doppler and Strain Imaging in Dogs with Myxomatous Mitral Valve Disease in Different Stages of Congestive Heart Failure. J Vet Int Med. 2009; 6: 1197-1207.

66. Muzzi RAL, Muzzi LAL, Pena JLB, Nogueira RB. Cardiomiopatia dilatada em cão – relato de caso. Ciência Rural, Santa Maria. 2000; 2: 355-358.

67. Oyama MA. Canine Cardiomyopathy. In: Miller MS, Tilley LP. (Editors). Manual of canine and feline cardiology. 4th edition. Saunders, Philadelphia. 2008; 139-150.

68. Fruganti A, Cerquetella M, Copponi I, Spaterna A, Tesei B. Preliminary study of the evaluation of m-mode, b-mode and X-Strain echocardiography indexes, before and during therapy, in dogs affected by dilated cardiomyopathy. 64º Veterinary Science Congress. 2012; 231.

69. Spalla I, Locatelli C, Riscazzi G, Brambilla P, Bussadori C. Speckle-Tracking Echocardiography in Dogs with Patent Ductus Arteriosus. J Vet Int Med. 2014; 2: 737.

70. Alves FR, Moura LS, Rodrigues RPS, Anais do. VIII Congresso Piauiense de Cardiologia, Teresina-PI. 2017.

71. Abdulrahman RM, Delgado V, Hoftijzer HC, Ng AC, Ewe SH, Marsan NA, et al. Both exogenous subclinical hyperthyroidism and short-term overt hypothyroidism affect myocardial strain in patients with differentiated thyroid carcinoma. Thyroid. 2011; 21: 471-476.

72. Stanton T, Leano R, Marwick TH. Prediction of all-cause mortality from global longitudinal speckle strain: Comparison with ejection fraction and wall motion scoring. Circ Cardiovasc Imaging. 2009; 2: 356-364.

J Cardiovasc Disord - Volume 4 Issue 2 - 2017
ISSN 2379-7991 | www.austinpublishinggroup.com

Citation: Alves FR, Pessoa GT, Rodrigues RPS, da Silva ABS, Moura LS, Alves JJRP, et al. Measurement of Strain by Speckle Tracking: Its Current use in Medicine and in Animal Models. J Cardiovasc Disord. 2017; 4(2): 1037.