

Case Report

A Specific Osteolytic Destruction of Lumbar Spine in a Young Girl

Baogan Peng* and Duanming Li

Department of Spinal Surgery, General Hospital of Armed Police Force, China

***Corresponding author:** Baogan Peng, Department of Spinal Surgery, Institute of Spinal Surgery of Armed Police Force, General Hospital of Armed Police Force, 69 Yongding Road, Beijing 100039, P.R. China

Received: August 06, 2014; **Accepted:** September 04, 2014; **Published:** September 06, 2014

Abstract

This report described a young child with osteolytic destruction in two adjacent vertebral bodies along with the intervertebral disc, and reveals its possible mechanism. CT scan with 2-dimensional reconstruction showed the osteolytic destruction in the upper third portion of L3 vertebral body and the lower endplate erosion of L2 vertebral body. The lesion has also involved L2/3 disc. A comprehensive preoperative evaluation did not identify a specific cause of vertebral destruction. In order to confirm the diagnosis and completely excise the lesion, we implemented a posterior lumbar interbody fusion. Low back pain disappeared immediately following the operation. Histopathological study showed a great deal of B-lymphocytes and macrophages infiltration. Studies of its pathogenesis reveal that it is likely to be a B-lymphocyte mediated local immune inflammatory reaction in the lumbar spine.

Keywords: Osteolytic destruction; Lumbar spine; B-lymphocyte; Macrophage; Inflammation; Immune reaction

Osteolytic destruction of vertebral body is commonly related to the pathologic process of spine tumors, or tumor-like lesions, infection, and avascular necrosis [1-3]. At present, we report a case of young girl with the osteolytic destruction in L2 and L3 two adjacent vertebral bodies along with L2/3 intervertebral disc. We ruled out the possibility of malignancy, infection, and avascular necrosis. To the best of our knowledge, no lesion of this type has been reported in a young child previously.

Case Presentation

A 3 years old girl had a history of low back pain for 6 months. She was delivered through a caesarean section at full term with normal intelligence. Pain consistently aggravated her as she stood and walked for a long time, and did not fade after various conservative therapies including lumbar immobilization using bracing, physical therapy and oral painkiller. The patient had no history of major illness and trauma in the past. There was no history of long term febrile or night sweat during the course of illness. Physical examination revealed a stiff lumbar spine. There were tenderness and percussion pain over the L2-L4 lumbar spine. After admission, all imaging examinations including lumbar plain radiography, CT, MRI, whole-body bone scan, and chest clairvoyance were carried out together with laboratory examinations. No abnormality was detected by chest clairvoyance or abdominal ultrasonic examination. Laboratory results were either negative or within normal range. The plain radiographs of lumbar spine showed irregular changes in the upper endplate of L3 vertebral body and narrowing in the L2/3 intervertebral space. CT scan with 2-dimensional reconstruction showed the osteolytic destruction in the upper 1/3 portion of L3 vertebral body and the lower endplate erosion of L2 vertebral body. The lesion had involved the L2/3 disc (Figure 1). T2-weighted MR images displayed irregular high signal intensity in the L3 vertebral body and the lower 1/2 portion of L2 vertebral body. Whole-body isotope bone scan demonstrated a high

uptake in the L2 and L3 vertebral bodies, especially in the L3 vertebral body (Figure 2).

Because of the severe back pain in this patient that was non-responsive to conservative therapies, making a definite diagnosis was required for such a young child. Utilizing a needle biopsy in so young a child would not be appropriate. First, a needle biopsy is subject to sampling error; second, it is difficult to put a child so young under local anesthesia in order to obtain the needle biopsy sample; finally, the lesion has involved the L2/3 disc, which shows severe degeneration and has a clear indication for fusion surgery. In order to

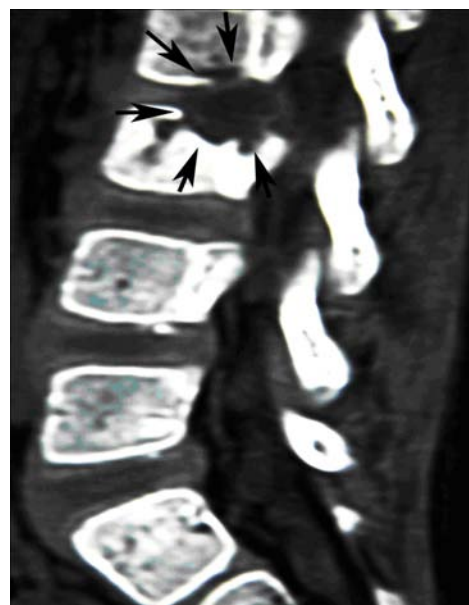


Figure 1: CT scan with 2-dimensional reconstruction showed the osteolytic destruction. The lesion has involved the L2/3 disc.

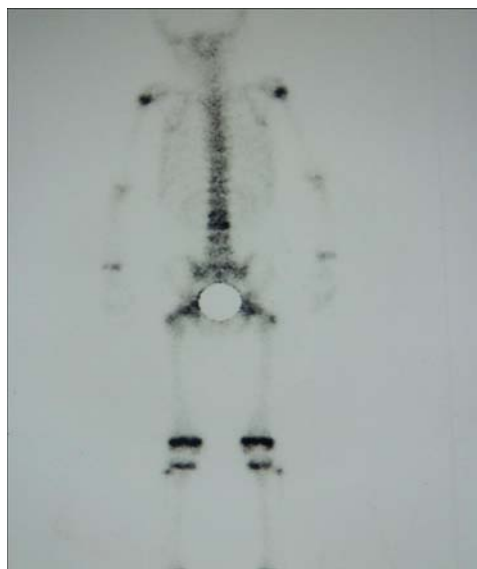


Figure 2: Whole-body bone scan revealed a high uptake in the L2 and L3 vertebral bodies.

confirm diagnosis and completely excise the lesion, we implemented a posterior pedicle screw fixation between L2 and L4 vertebrae and L2-L3 intervertebral body fusion with the use of allogeneic iliac bone graft. During the surgery, the lesions were removed for histopathologic examination with routine haematoxylin and eosin stain. Immunohistochemical examination was performed to identify infiltrated cell types in the specimens of the two contiguous vertebrae and the intervening disc. Low back pain disappeared following the operation. Bone fusion between L2 and L3 vertebral bodies was obtained in 2 years (Figure 3) before the pedicle screw system was eventually removed.

Histopathologic study showed a great deal of inflammatory cell infiltration, disappearance of fat cells and hematopoietic cells within marrow cavities, and disappearance, disruption or atrophy of bone trabeculae (Figure 4). In the adjacent degenerated discs, formation of vascularized granulation tissue in the nucleus pulposus was found. Further immunohistochemical staining showed large amount of B-lymphocytes and macrophages infiltration into the marrow cavities (Figure 5). No T-lymphocyte was found. No microorganisms and malignant cells were found under microscope. Gram, fungal, and acid-fast stains and cultures were all negative.

All these results of examinations mentioned above were consistent with a specific osteolytic destruction of lumbar spine which was reported recently [1].

Discussion

The major differential diagnostic consideration for the osteolytic destruction of vertebral bodies is spine tumor or tumor-like lesions, including spine metastases, lymphoma, leukemia, polyostotic fibrous dysplasia, generalized fibromatosis, multiple FFCD (focal fibrocartilaginous dysplasia), nonossifying fibromata including Jaffe-Campanacci syndrome, cystic angiomas, and multiple hemangiomas including Gorham disease [1]. Malignancy is most often expansile and commonly associated with soft tissue. MRI

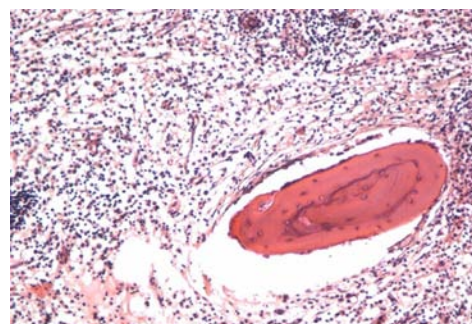


Figure 3: Pathological study showed a great deal of inflammatory cell infiltration within marrow cavities. Hematoxylin-eosin staining, original magnification $\times 100$.

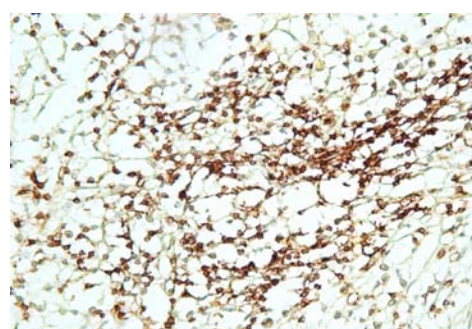

Figure 4: Immunohistochemical staining showed large amount of B-lymphocytes infiltration into the marrow cavities. S-P stain, original magnification $\times 200$.

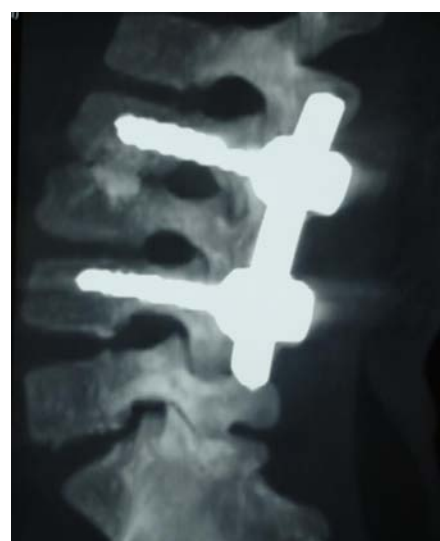

Figure 5: Bone fusion between L2 and L3 vertebral bodies was obtained.

shows homogeneous and diffuse vertebral signal abnormality, a convex vertebral border, pedicle involvement, and sparing of the intervertebral disc [2]. Spine benign tumors or tumor-like lesions mentioned above have their respective clinical findings and imaging characteristics. Percutaneous or open biopsy is desirable to clarify the diagnosis. Another possible disorder, Langerhans cell histiocytosis (LCH), needs to be differentiated with the osteolytic destruction of vertebral bodies. LCH is a rare condition that usually affects the pediatric population, characterized by clonal

proliferation of Langerhans cells and focal aggregates of variable numbers of eosinophils, lymphocytes, neutrophils, foamy histocytes and multinucleated giant cells. LCH tends to involve the skeletons and surrounding soft tissue, presenting with osteolytic lesions [3]. A definitive diagnosis requires that lesional cells exhibit positive staining with CD1a and S-100 protein [4]. Langerhans cells are antigen-presenting cells, belonging to T-lymphocytes, should exhibit positive staining with CD4 and CD8 [5]. In our case, lesional cells were CD20-positive and CD4-negative.

Other likely considerations in the differential diagnosis include spine infection and avascular necrosis. According to the clinical presentations, imaging studies, and laboratory examinations, infection is easily diagnosed. Vertebral osteomyelitis has a more precipitous presentation with severe pain, high fever, and profound clinical symptoms. The organism can be isolated either by a blood culture or from needle aspiration material [6]. Avascular necrosis has been associated with various risk factors and classified as either secondary or idiopathic. Renal diseases, exposure to steroids, and alcohol abuse account for more than 90% of all known associated risk factors [7,8]. Avascular necrosis of the vertebral body is thought to be the result of an injury, which is caused by either traumatic or nontraumatic mechanisms, at the anterior segment of the vertebral body in the area of a vascular watershed [9]. Our case had no any significant risk factors for vertebral avascular necrosis, and had also no history of trauma. Histopathologic study of the destructed vertebral bodies in the case revealed substantial differences from the changes of avascular necrosis. Main characteristic changes in our patients were the disruption or atrophy of bone trabeculae with infiltration of a large amount of B-lymphocytes and macrophages into the marrow cavities. Chou et al. [9] and Lee et al. [7,10] showed the no histological evidence of inflammation in the avascular necrosis of vertebral body.

Peng et al. [1] recently reported two cases of this disease which occurred in the young adults. The present study indicates that this disease also can occur in young children. This is an interesting disease. According to its clinical presentations, imaging, and pathology, we analyse that the lesion is a B-lymphocyte mediated local immune inflammatory reaction of lumbar spine. The lesion first appeared within L3 intervertebral body (main lesion), then it progressed into L2/3 disc, and finally spread to the L3 vertebral body. The exact cause

is not clear, and needs to be further clarified. Recognition of this pathogenic process is very important so that confusion with spine tumors, or tumor-like lesions, infection and avascular necrosis may be avoided. On its treatment, because conservative treatment failed, we took a complete surgical excision of the lesion, fixation and interbody fusion. Clinical practice shows that it is a very effective treatment.

Conclusion

The osteolytic destruction in this case is likely to be a B-lymphocyte mediated local immune inflammatory reaction of lumbar spine. The lesion first appeared within L3 intervertebral body (main lesion), then it progressed into L2/3 disc, and finally spread to the L3 vertebral body. Lumbar interbody fusion appeared to be an effective treatment.

References

1. Peng B, Chen J, Pang X, Hei Y. A kind of specific osteolytic destruction of the vertebral bodies. *BMJ Case Rep.* 2012; 2012.
2. Aprin H. Primary malignant tumors of the spine. In: Akbarnia BA, editor. *Spine: state of the art reviews.* Philadelphia: Hanley & Belfus. 1988: 289-299.
3. Cai S, Zhang S, Liu X, Lin Y, Wu C, Chen Y, et al. Solitary Langerhans cell histiocytosis of frontal lobe: a case report and literature review. *Chin J Cancer Res.* 2014; 26: 211-214.
4. Satter EK, High WA. Langerhans cell histiocytosis: a review of the current recommendations of the Histiocyte Society. *Pediatr Dermatol.* 2008; 25: 291-295.
5. Rabi S, Jacob TM, Lionel J, Indrasingh I. Different subsets of Langerhans cells in human uterine tubes and uterus. *J Obstet Gynaecol Res.* 2014; 40: 1833-1839.
6. Zimmerli W. Clinical practice. Vertebral osteomyelitis. *N Engl J Med.* 2010; 362: 1022-1029.
7. Mont MA, Jones LC, Einhorn TA, Hungerford DS, Reddi AH. Osteonecrosis of the femoral head. Potential treatment with growth and differentiation factors. *Clin Orthop Relat Res.* 1998; : S314-335.
8. Urbaniak JR, Harvey EJ. Revascularization of the femoral head in osteonecrosis. *J Am Acad Orthop Surg.* 1998; 6: 44-54.
9. Chou LH, Knight RQ. Idiopathic avascular necrosis of a vertebral body. Case report and literature review. *Spine (Phila Pa 1976).* 1997; 22: 1928-1932.
10. Lee JH, Kim KT, Suk KS, Lee SH, Jeong BO. Avascular necrosis of the spine in solid posterior fusion segments. *Spine (Phila Pa 1976).* 2009; 34: E158-161.