Austin Journal of Clinical Neurology

Open Access

Austin Publishing Group

Case Report

Development of Glioblastoma Multiforme in a Patient with Relapsing-Remitting Multiple Sclerosis

Myserlis P[1,2]*, Stachteas P[1,2], Dimitriadis I[3] and Tsolaki M[1,2]

[1]Department of Neurology, Aristotle University of Thessaloniki, Greece

[2]Greek Association of Alzheimer's Disease and Related Disorders, University of Thessaloniki, Greece

[3]Department of Pathology, G. Papanicolaou Hospital, Greece

***Corresponding author:** Myserlis P, Department of Neurology, Aristotle University of Thessaloniki, Chortiatis, 57010, Thessaloniki, Greece

Received: August 21, 2017; **Accepted:** October 23, 2017; **Published:** November 01, 2017

Abstract

Introduction: Multiple sclerosis (MS) and glioblastoma multiforme (GBM) are two conditions that rarely co-exist. Only 50 cases have been reported, mainly regarding to older patients. It is not uncommon that in these cases, glioma development lead to the passing of the patient, before appropriate diagnosis and management was introduced.

Case Presentation: A 37-year-old man with relapsing-remitting MS was presented to us, in whom annual brain MRI revealed a 5 cm circular, ring-enhancing lesion in the frontoparietal region of the right cerebral hemisphere. MRI, MR spectroscopy and biopsy were performed which revealed grade IV glioblastoma. He received standard treatment, consisting of surgical resection of the tumor, radiotherapy and chemotherapy with temozolomide, but experienced a recurrence after five months, leading to gradual loss of his motor and sensory functions, ataxia, speech difficulties and cognitive decline. He, almost three years after the diagnosis of GBM, currently scores 9 on Kurtzke Expended Disability Status Scale (EDSS), is confined to bed and can function with partial assistance.

Discussion: Several assumptions exist as to whether the concurrence of MS with glioma is incidental or not. Neoplastic transformation of reactive glial cells, chronic inflammation and involvement of neurotropic growth factors comprise mechanisms thought to be implicated in the pathogenesis of the diseases. In order for a glioma to be differentiated from a MS relapse, high level of clinical suspicion is of paramount importance. Our patient is one of the youngest patients with MS in the literature who developed GBM, was timely diagnosed for it, and properly handled.

Keywords: Multiple sclerosis; Relapsing-remitting; Malignant; Glioma; Glioblastoma; Primary brain tumor

Abbreviations

MS: Multiple Sclerosis; GBM: Glioblastoma Multiforme; MRI: Magnetic Resonance Imaging; EDSS: Expended Disability Status Scale; RR: Relapsing-Remitting; CNS: Central Nervous System

Introduction

Co-occurrence of multiple sclerosis (MS) and glioblastoma multiforme (GBM) is a very rare condition. It has recently been reported, that no more than 50 cases of MS patients with GBM have ever been recorded [1]. Close inspection of the literature reveals that there have been several cases in which the glioma was speculated before the death of the patient [2,3], many years after the onset of MS symptoms, while in others, existence of the tumor was confirmed only after autopsy [4]. The delay in diagnosis is mainly attributed to the resemblance of the neurological signs and symptoms of GBM with a MS relapse. Additional reasons include lack of scheduled neuroradiological examinations in MS patients and difficulty in differentiation of the lesions between the two diseases, due to perception of MS as a condition with a heterogenous clinical and radiological appearance, including tumefactive MS [5].

Case Presentation

A 37-year-old man with MS was presented to us with the following history. He had experienced a relapsing-remitting (RR) course of disease since 2000, when diagnosis was formulated in agreement with clinical, laboratory and radiological data. His symptoms consisted of mild numbness and tingling of the right side of the body and face. At the time of the diagnosis, brain MRI revealed 1-3 T2-weighted hyperintensities in the periventricular zones with irregular enhancement on T1 post-gadolinium scan of at least one lesion. There were also T2-weighted hyperintensities located in the cervical spine. Annual scheduled MRI scans showed progressive increase in the number of brain lesions with ultimately 14 subtentorial, subcortical and periventricular hyperintensities. He experienced two documented relapses in 2003 and 2006 with diplopia. The patient was never given any symptomatic or disease-specific therapy.

In December 2014, standard, annual brain MRI revealed a 5 cm circular, ring-enhancing lesion located in the frontoparietal region of the right cerebral hemisphere. The main diagnostic hypothesis was a glioblastoma; tumor-like plaque diagnosis was excluded due to lack of "open ring sign" in enhancement, and brain abscess was deemed

Myserlis et al. © All rights reserved

Citation: Myserlis P, Stachteas P, Dimitriadis I and Tsolaki M. Development of Glioblastoma Multiforme in a Patient with Relapsing-Remitting Multiple Sclerosis. Austin J Clin Neurol 2017; 4(7): 1128.

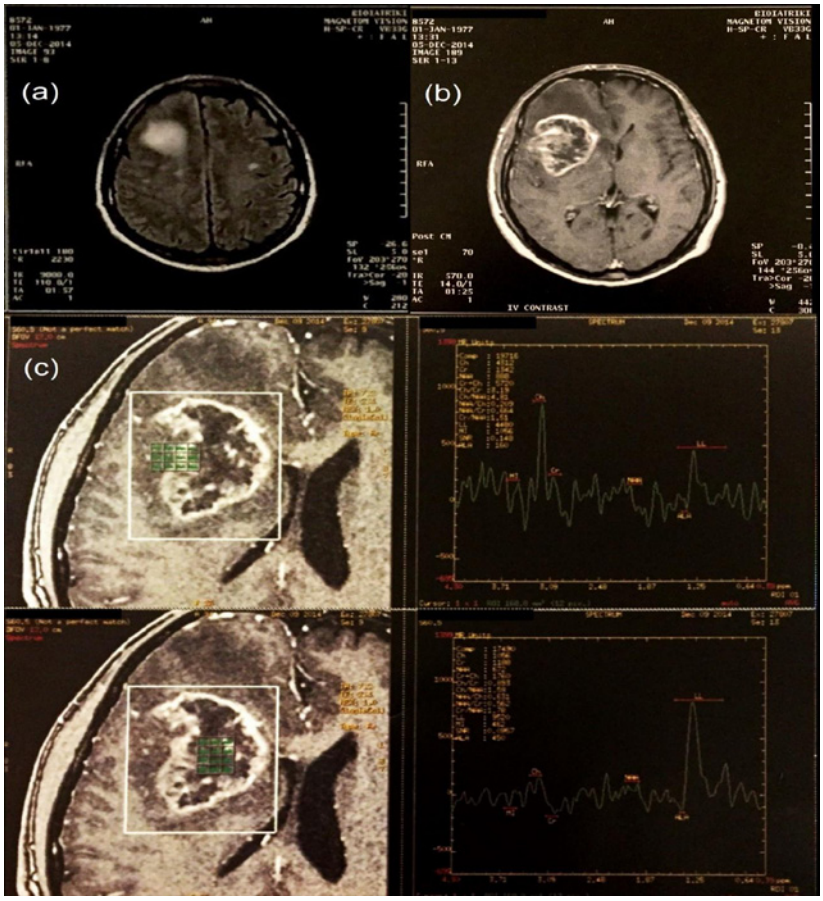

Figure 1: T2- and T1-weighted MRI and MR spectroscopy of the lesion. (a) T2-weighted axial MRI demonstrates the lesion, with notable edema, along with multiple subcortical and periventricular white matter lesions (total count: 14), typical for MS. (b) T1-weighted axial gadolinium-enhanced magnetic resonance image demonstrates an irregularly enhancing tumor of the right frontoparietal lobe. (c) MR spectroscopy of the lesion shows depression of the N-acetyl aspartate (NAA) (at 2.02 ppm) and creatine (Cr) (at 3.0 ppm) peaks, increased choline to creatine ratio (Ch/Cr 3.19) and elevation of the lactate and/or lipid (LL) (at 1.33 ppm) peak, suggestive of high-grade glioma (WHO grade IV) with central necrosis.

unlikely due to thickness and irregularity of contrast enhancement. MR spectroscopy was performed, with typical findings of a high-grade glioma (Figure 1). Biopsy was also performed, which revealed grade IV glioma (GBM) (Figures 2-4). The patient underwent surgical resection of the tumor, radiotherapy and adjuvant chemotherapy with temozolomide. He has been experiencing gradual loss of motor and sensory functions, ataxia, speech difficulties and cognitive decline since May 2015, due to recurrence of the GBM. He currently scores 9 on Kurtzke Expended Disability Status Scale (EDSS) and is confined to bed, can still communicate and eat with partial assistance.

Discussion

Several assumptions exist as to whether the concurrence of MS with glioma is incidental or not. It has long been hypothesized that neoplastic transformation of reactive glial cells in plaques might be the origin of the gliomas [6]. It has also been suggested that chronic inflammation might increase the risk of brain tumors in MS patients, via destruction of the myelin sheath of nerve fibers and hyperproliferation of oligodendrocytes and astrocytes [1]. Recent data support the involvement of neurotropic growth factors that promote the proliferation and survival of oligodendrocytes during the MS remyelination process, leading to transformation of MS lesions into a tumor [7]. Common associations of the two conditions with various environmental, genetic and epigenetic factors have also been postulated [7].

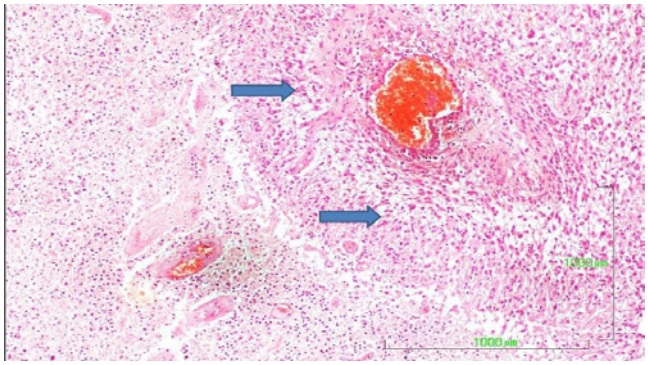

Figure 2: Pseudopalisading necrosis.

In order for a glioma to be successfully differentiated from a MS relapse, high level of clinical suspicion is of paramount importance. Steady neurological decline over 4 weeks or signs and symptoms uncommonly associated with MS course of disease should prompt

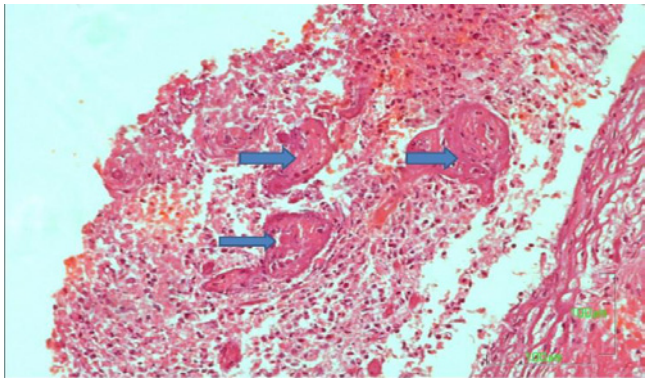

Figure 3: Thickened vascular walls due to endothelial cell hyperplasia.

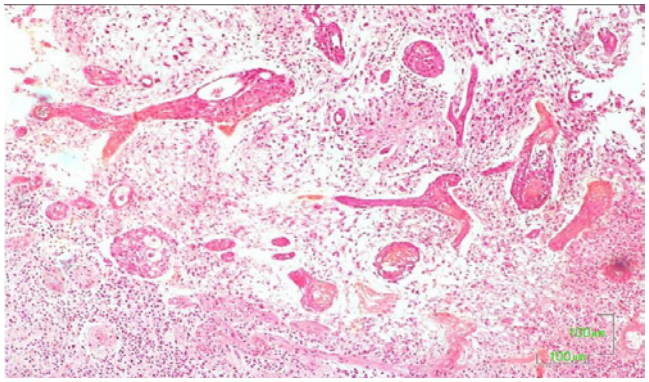

Figure 4: Prominent anaplasia, vascular proliferation, and palisading of tumor cells around necrosis.

for a more extensive diagnostic evaluation for underlying conditions [1]. Brain and spinal cord MRI constitute the initial assessment of such symptomatology, although not infrequently the findings are rendered inconclusive. In these cases, spectroscopy, positron emission tomography and eventually CNS biopsy have proven to be of significant value. Finally, studies have shown that transcription factors, such as T-bet, pSTAT1 and pSTAT3 could facilitate as markers for discrimination between a MS relapse and a non-inflammatory neurological disease, although additional studies are needed to confirm these results [2].

In conclusion, our case represents a severe manifestation of coexistence of MS and GBM, leading to serious functional decline and cognitive impairment, within a relatively short time. To the best of our knowledge, our patient is one of the youngest patients with MS in the medical literature that developed GBM. The presented case suggests that thorough clinical and radiological evaluation is of paramount importance for prompt exclusion of GBM diagnosis in MS patients with worsening symptoms.

References

1. Mantero V, Balgera R, Bianchi G, Rossi G, Rigamonti A, Fiumani A, et al. Brainstem glioblastoma in a patient with secondary progressive multiple sclerosis. Neurol Sci. 2015; 36: 1733-1735.
2. Frissulo G, Patanella AK, Nociti V, Cianfoni A, Iorio R, Bianco A, et al. Glioblastoma in multiple sclerosis: a case report. J Neuro-oncol 2009; 94: 141-144.
3. Paydarfar D, De la Monte SM. Case records of the Massachusetts General Hospital. Weekly clinicopathological exercises. Case 12-1997. A 50-year-old woman with multiple sclerosis and an enlarging frontal-lobe mass. N Eng J Med. 1997; 336: 1163-1171.
4. Pál E, Gömöri E, Gáti I. Neurofibromatosis and glioblastoma in a case of multiple sclerosis. Eur J Neurol. 2001; 8: 717-718.
5. Lucchinetti CF, Gavrilova RH, Metz I, Parisi JE, Scheithauer BW, Weigand S, et al. Clinical and radiographic spectrum of pathologically confirmed tumefactive multiple sclerosis. Brain. 2008; 131: 1759-1775.
6. Sega S, Horvat A, Popovic M. Anaplastic oligodendroglioma and gliomatosis type 2 in interferon-beta treated multiple sclerosis patients. Report of two cases. Clin Neurol Neurosurg. 2006; 108: 259-265.
7. Plantone D, Renna R, Sbardella E, Koudriavtseva T. Concurrence of multiple sclerosis and brain tumors. Front Neurol. 2015; 6: 40.

Austin J Clin Neurol - Volume 4 Issue 7 - 2017
ISSN : 2381-9154 | www.austinpublishinggroup.com
Myserlis et al. © All rights reserved

Citation: Myserlis P, Stachteas P, Dimitriadis I and Tsolaki M. Development of Glioblastoma Multiforme in a Patient with Relapsing-Remitting Multiple Sclerosis. Austin J Clin Neurol 2017; 4(7): 1128.