Austin Journal of Clinical Neurology

Open Access

Austin Publishing Group

Case Presentation

Fahr's Disease and Cerebrovascular Disease: A Case Report and a Literature Review

Migliano MT[1]*, Bergolari F[1], Donati D[2], Cesa F[2], Spampinato MD[3], Puddu GM[4], Muscari A[1], Trevisani F[1] and Gramenzi A[1]

[1]Department of Medical and Surgical Sciences, Sant'Orsola Hospital, University of Bologna, Italy

[2]Department of Biomedical and NeuroMotor Sciences, Sant'Orsola Hospital, University of Bologna, Italy

[3]Department of Emergency Medicine, University of Ferrara, Italy

[4]Stroke Unit, Sant'Orsola Malpighi Hospital, Italy

***Corresponding author:** Migliano MT, Department of Medical and Surgical Sciences, Sant'Orsola Hospital, University of Bologna, Via Massarenti 9, Bologna 40100, Italy

Received: September 03, 2018; **Accepted:** September 18, 2018; **Published:** September 25, 2018

Abstract

Background: Fahr Disease (FD) is a rare neurodegenerative disease characterized by symmetrical and bilateral calcifications of basal ganglia. The most common clinical symptoms are movement and behavioral disorders and cognitive impairment, probably due to the perivascular calcium deposition. It is still unclear if there is an association with an increased cerebrovascular risk.

Case Report: A 76-years-old woman, affected by hypertension and polygenic hypercholesterolemia, was admitted to our department because of progressive motor troubles and cognitive impairment. A diagnosis of FD was established. A right-hemiplegia and dysarthria suddenly appeared with the comparison at CT-scans of a macro-lacunar ictus in left corona radiata and lentiform nucleus.

Discussion: Even though the patient had known cerebrovascular risk factors, a correlation between FD and the macro-lacunar stroke cannot be excluded, especially because of the unusual size of the lesion. With this background, the existing literature has been reviewed. A marked reduction in cerebral flow, perhaps due to the perivascular calcium deposits, has been described not only in basal ganglia but also even in cortical regions. In addition, based on the occurrence of cerebrovascular disease in FD even without other risk factors, stroke could be a part of the disease's natural history, even if the pathophysiology remains unclear.

Conclusion: Although systematic studies are lacking, this case report further supports a potential pathogenetic role of FD in cerebrovascular diseases.

Keywords: Fahr disease; Cerebrovascular risk; Calcifications of basal ganglia

Abbreviations

FD: Fahr Disease; CT: Computerized Tomography; TORCH: Toxoplasma Rosolia Cimegalovirus; SPECT: Single Photon Emission Computerized Herpesvirus Tomography; SLE: Systemic Erythematous Lupus; TIA: transitory ischemic attack; NIHSS: National Institutes of Health Stroke Scale

Introduction

Fahr Disease (FD) is a rare neurodegenerative disease whose prevalence is unknown, arising between thirties and sixties [1-2] and characterized by a bilateral and symmetric calcification of basal ganglia. It is a familial condition with an autosomal inheritance. Main involved locus is on 14q, but several loci can contribute to its genesis (SLC20A2, PDGFRB, PDGFB) [2-3]. Non familial forms are defined as Fahr syndrome and they can be due to an altered calcium metabolism, mitochondriopathies, cerebral neoplasms [4], infections such as TORCH, brucellosis, inflammatory diseases (SLE, sarcoidosis) [5] and traumas.

Pathogenesis is still unclear but is probably linked to the perivascular deposition of calcium, caused by an altered neuronal metabolism or by a local destruction of the blood-brain barrier [1].

Clinical manifestations are various, but neuropsychiatric symptoms and movement disorders are the most representative features. Among the movement disorders, clumsiness, weakness, slurred speech, ataxia, bradykinesia, dyskinesia, rigidity are the most common, while attention deficit, personality and mood disorders, psychosis, cognitive impairment are the most common psychiatric symptoms.

Main diagnostic criteria are [1]:

Evidence of bilateral and symmetric calcification of basal ganglia;

The age at the onset (usually in the fourth or fifth decade even though earlier onset can occur);

Progressive neurological or neuropsychiatric manifestations;

No biochemical and/or clinical evidence of mitochondrial, metabolic, infectious, traumatic, toxic or other systemic disorders.

Family history of basal ganglia calcification consistent with autosomal dominant inheritance is an additional diagnostic criteria but it is not mandatory [6].

The role of FD as risk factor for cerebrovascular disorders is presently unknown. It should be pointed out that FD is a rare condition with polymorphous symptoms that can be under- or misrecognized without imaging. Therefore, the small number of cases

Migliano et al. © All rights reserved

Citation: Migliano MT, Bergolari F, Donati D, Cesa F, Spampinato MD, Puddu GM, et al. Fahr's Disease and Cerebrovascular Disease: A Case Report and a Literature Review. Austin J Clin Neurol 2018; 5(1): 1132.

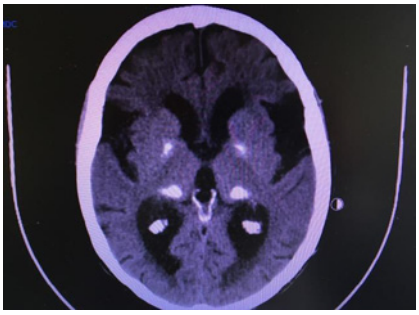

Figure 1:

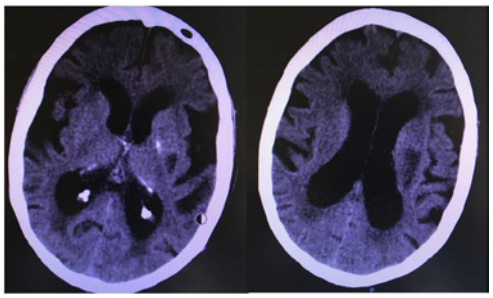

Figure 2:

make it difficult to clearly establish an association between FD and cerebrovascular diseases.

We report here the case of a woman with bilateral calcifications of basal ganglia compatible with FD whose hospital-stay was complicated by a lacunar ictus.

Case Report

A 76-years-old woman, affected by hypertension and polygenic hypercholesterolemia, was admitted for right hemiparesis. In the past she underwent quadrantectomy and radiotherapy for left breast tumor and vulvar resection for cancer. She had been suffering of mild ataxia for at least two years. In the last months she experienced a worsening of this movement disorder associated with behavioral and cognitive decline.

When she was admitted to our department, she had right hemiparesis and mild VII cranial nerve palsy (NIHSS 3). A Computed Tomography (CT) showed bilateral calcifications of globi pallidi and pulvinaris, typical of FD in absence of acute lesions (Figure 1).

During the hospital-stay neurologic symptoms suddenly worsened, with the appearance of right hemiplegia and dysarthria (NIHSS 15). An urgent neuroradiologic evaluation was carried out, showing no acute lesions, while after 72 hours a new CT scan revealed a macro-lacunar ischemic lesion in left corona radiata and lentiform nucleus (maximal diameter 2,5 cm) (Figure 2).

Echocolor-Doppler of supra-aortic vessels showed no hemodynamic stenosis. No arrhythmia was documented at electrocardiographic monitoring and echocardiography disclosed no atrial dilation. No alteration in calcium metabolism was found, confirming FD diagnosis.

Discussion

The case of our patient, in spite of the presence of known cerebrovascular risk factors, suggests a possible association between FD and cerebrovascular disease especially attributable to the large size of the lacunar lesion usually smaller in "pure" vascular patients.

To check this possible relationship a literature search was performed. Among the different causes of "Cerebral Small Vessels Disease", to date 7 monogenic conditions have been identified [7]. No association has been found with FD until now.

We wonder if the peri-vascular calcium deposition along cerebral vessels, typical of FD, can represent a risk factor for cerebrovascular disease. Shoyama et al. in a woman with asymmetric calcifications at basal ganglia, cerebral SPECT revealed a reduction of cerebral flow in more calcified areas, suggesting a correlation between calcifications and vascular changes [8]. This was confirmed by Uygur et al. in a patient with FD [9]. In addition, Cvjetko et al. in a 49-year woman affected by FD observed a chronic obliterative peripheral arteriopathy due to non-atherosclerothic calcification of aorta and iliac arteries bilaterally suggesting a linkage between calcium deposits typical of FD and extracerebral vascular damage [10].

Despite these scattered observations and case reports, studies focusing on the evaluation and quantification of cerebrovascular risk in patients with this neurodegenerative disease are still missing as documented by a literature search on PUBMED (Figure 3). Indeed,

History

Download history Clear history

Search	Add to builder	Query	Items found	Time
#12	Add	Search **((Familial idiopathic basal ganglia calcification[MeSH Terms]) AND cerebral small vessel disease[MeSH Terms]**	0	07:23:25
#11	Add	Search **(Familial idiopathic basal ganglia calcification[MeSH Terms]) AND lacunar stroke[MeSH Terms]**	0	07:10:23
#8	Add	Search **(Familial idiopathic basal ganglia calcification[MeSH Terms]) AND cerebrovascular stroke[MeSH Terms]**	1	06:45:39
#2	Add	Search **(fahr disease) AND cerebral stroke**	2	06:44:02
#7	Add	Search **(fahr disease) AND brain vascular injury** Schema: **all**	0	06:40:57
#6	Add	Search **(fahr disease) AND brain vascular injury**	0	06:40:57
#5	Add	Search **(fahr disease) AND vascular brain injury[MeSH Terms]**	0	06:40:33
#4	Add	Search **(fahr disease) AND brain vascular accidents[MeSH Terms]**	0	06:39:55
#1	Add	Search **(Fahr disease[MeSH Terms]) AND cerebral stroke[MeSH Terms]**	0	06:35:17

Figure 3:

Table 1:

String	Title	Author	Publication year
(fahr disease) AND	Familial idiopathic basal	Mufaddel AA et al [1]	2014
cerebral stroke	ganglia calcification		
	(Fahr`s disease)		
(fahr disease) AND	Mitochondrial	Younes-Mhenni S et al	2002
cerebral stroke	encephalomyopathy,	[11]	
	lactic acidosis and		
	stroke-like episodes		
	(Melas) associated with		
	a Fahr disease and		
	cerebellar calcifications.		
(Familial idiopathic basal	Ischemic stroke in a	Yang CS et al [12]	2016
ganglia	young patient with		
calcification[MeSH	Fahr's disease: a case		
Terms]) AND	report		
cerebrovascular			
stroke[MeSH Terms]			

Table 2:

Author	Publication year	Age, gender	Clinical manifestation
Bartecki [16]	1979	39 years-old, male	TIA
Asensio Moreno [17]	2008	71 years-old, male	TIA
Al-Jehani H [14]	2012	54 years-old, female	aneurysm rupture
Eroglu [15]	2016	42 years-old, female	multiple intracranial
			aneurysms
Yang [12]	2016	36 years-old, male	lacunar ictus
Sgulò [13]	2018	69 years-old, female	hemorrhagic stroke
Sgulò [13]	2018	72 years-old, female	cortical ischemic ictus
Present case report	2018	72 years-old, female	lacunar ictus

the following strings (Fahr disease [MeSH Terms]) AND cerebral stroke [MeSH Terms], (fahr disease) AND brain vascular accidents [MeSH Terms], (fahr disease) AND vascular brain injury [MeSH Terms], (Familial idiopathic basal ganglia calcification [MeSH Terms]) AND lacunar stroke [MeSH Terms], ((Familial idiopathic basal ganglia calcification [MeSH Terms]) AND cerebral small vessel disease [MeSH Terms] produced no results. On the contrary (fahr disease) AND cerebral stroke and (Familial idiopathic basal ganglia calcification [MeSH Terms]) AND cerebrovascular stroke [MeSH Terms] produced 3 articles summarized in (Table 1). In the first, Mufaddel et al. [1] reviewed the pathogenesis of neuropsychiatric symptoms in FD. Younes et al. [11] reported a case of MELAS

(Mitochondrial Myopathy, Encephalopathy, Lactic Acidosis and Stroke) syndrome associated with basal ganglia calcifications. This article was excluded since it was related to Fahr Syndrome due to a mitochondriopathy rather than idiopathic FD. Yang CS et al. described a 36-year man with FD and ischemic stroke in absence of other cerebrovascular risk factors [12].

In addition, other case reports were found using free terms, screening reference lists and employing a "snowball" research strategy (Table 2). In particular, Sgulò el al. described the case of a 72-years-woman with multiple left cortical ischemic strokes [13-15], Bartecki et al. the case of a 39-years-old man with Transitory Ischemic Attacks (TIA) characterized by right hemiparesis and aphasia [16], Asensio et al. the case of a 71-years-old man with TIA and the sole hypertension as risk factor [17]. All these reports highlighted an association between FD and cerebrovascular events, both hemorrhagic [13-15] and ischemic, even in young people without known or few risk factors. Therefore it cannot be excluded that FD plays a pathogenetic role in this kind of events as in our case report.

Conclusion

FD is still a poorly understood condition mainly because of its rarity. Even though there are some evidence of a possible association with cerebrovascular diseases, no definitive conclusion. Our report adds one more piece in this still fragmented literature suggesting collecting a proper sample size of FD cases to better look into this "risk" relationship in order to prevent and treat related complications.

References

1. Mufaddel AA, Al-Hassani GA. Familial idiopathic basal ganglia calcification (Fahr`s disease). Neurosciences (Riyadh). 2014; 19: 171-177.
2. Ramos EM, Oliveira J, Sobrido MJ. Primary Familial Brain Calcification. Gene Reviews. 2017.
3. Tadic V, Westenberger A, Domingo A. Primary familial brain calcification with known gene mutations: a systematic review and challenges of phenotypic characterization. JAMA Neurol. 2015; 72: 460-467.
4. Lin Q, Piao Y, Ling F. Concurrence of Fahr's disease and brain tumor: A case report and review of the literature. Exp Ther Med. 2015; 10: 1915-1917.
5. Chang RS, Leung CY, Leong HS. Bilateral Striatopallidodentate Calcinosis associated with Systemic Lupus Erythematosus: Case report and review of literature. J Neurol Sci. 2015; 358: 518-519.
6. Lazăr M, Ion DA, Streinu-Cercel A. Fahr's syndrome: diagnosis issues in patients with unknown family history of disease. Rom J Morphol Embryol. 2009; 50: 425-428.
7. Søndergaard CB, Nielsen JE, Hansen CK. Hereditary cerebral small vessel disease and stroke. Clin Neurol Neurosurg. 2017; 155: 45-57.
8. Shoyama M, Ukai S, Shinosaki K. Evaluation of regional cerebral blood flow in patient with atypical senile dementia with asymmetrical calcification. Psychogeriatrics. 2015; 15: 272-276.
9. Uygur GA, Liu Y, Hellman RS. Evaluation of regional cerebral blood flow in massive intracerebral calcifications. J Nucl Med. 1995; 36: 610–702.
10. Cvjetko I, Lubina ZI, Pazur. Porcelain aorta and peripheral arterial disease in a patient with Fahr disease. J Vasc Surg. 2015; 62: 1073.
11. Younes-Mhenni S, Thobois S, Streichenberger N. Mitochondrial encephalomyopathy, lactic acidosis and stroke-like episodes (Melas) associated with a Fahr disease and cerebellar calcifications. Rev Med Interne. 2002; 23:1027-1029.
12. Yang CS, Lo CP et Wu MC. Ischemic stroke in a young patient with Fahr's disease: a case report. BMC Neurol. 2016; 16: 33.
13. Sgulò FG, Di Nuzzo G, De Notaris M. Cerebrovascular disorders and Fahr's disease: report of two cases and literature review. J Clin Neurosci. 2018.
14. Al-Jehani H, Ajlan A, Sinclair D. Fahr's Disease Presenting with Aneurysmal Subarachnoid Hemorrhage. J Clin Imaging Sci. 2012; 2: 27.
15. Eroglu U, Kahilogullari G, Demirel A. Fahr's Syndrome Associated with Multiple Intracranial Aneurysms: A Case Report. Turk Neurosurg. 2016; 26: 643-645.
16. Bartecki BF, Kamienowski J. Transient focal ischemia in Fahr's disease. Neurologia i neurochirurgia polska. 1979; 13: 443-447.
17. Asensio Moreno C, Arias Jiménez JL, Aramburu Bodas O. Transient ischemic attack associated with a calcinosis cerebri syndrome. An Med Interna. 2008; 25: 33-35.

Austin J Clin Neurol - Volume 5 Issue 1 - 2018
ISSN : 2381-9154 | www.austinpublishinggroup.com
Migliano et al. © All rights reserved

Citation: Migliano MT, Bergolari F, Donati D, Cesa F, Spampinato MD, Puddu GM, et al. Fahr's Disease and Cerebrovascular Disease: A Case Report and a Literature Review. Austin J Clin Neurol 2018; 5(1): 1132.