Journal of Dental Applications

Open Access

Austin Publishing Group

Case Report

Free Gingival Grafting Before Implant Placement In A Geriatric Patient : A Case Report

Cakmak O[1]*, Alkan BA[2], Tasdemir Z[3], Kilinc HI[4] and Atalay Y[5]

[1]Department of Periodontology, Kocatepe University, Turkey

[2]Department of Periodontology, Erciyes University, Turkey

[3]Department of Periodontology, Erciyes University, Turkey

[4]Department of Prosthodontics, Erciyes University, Turkey

[5]Department of Oral and Maxillofacial Surgery, Kocatepe University, Turkey

***Corresponding author:** Cakmak O, Department of Periodontology, Kocatepe University, Guvenevler Street, Inonu Boulevard, 03030, Afyon, Turkey, Tel: +90 272 2167900 - 1037; Fax: +90 272 2167080; E-mail: cakmakomer@hotmail.com

Received: September 10, 2014; **Accepted:** September 20, 2014; **Published:** September 22, 2014

Abstract

Geriatric patients generally suffer from edentulism or partial edentulism, and those without a dental prosthesis can experience siginificant health issues, mostly due to inadequate nutrition. There are various techniques for rehabilitation of total or partial edentulism. Implant-supported overdentures have become an effective treatment alternative for edentulous patient. In this case report, a free gingival graft technique was used to increase the width of keratinized tissue before implant placement to improve long-term implant-supported prosthesis prognosis in a geriatric patient.

Keywords: Gingiva; Dental implantation; Dental Implants; Maintenance; Dental Prosthesis; Implant-Supported

Introduction

In years of 2000, there were approximately 600 million geriatrics in the world, and that number is increasing due to advances in medical science [1]. In recent years, geriatrics have become more susceptible to chronic illnesses such as cancer, diabetes mellitus, and oral diseases [2]. Among oral diseases, periodontal disease is the most prevalent among geriatrics [3]. There may be several possible causes of this. First, a decrease in hand flexibility of geriatric patients often causes a decline in oral hygiene , which can contribute to periodontal disease. Second, they often experience a compromised immune system, which can also contribute to periodontal disease [4]. Oral status directly affects general health. Geriatric patients generally have edentulism or partial edentulism, and those without a dental prosthesis can experience siginificant health issues, mostly due to inadequate nutrition [5].

There are various techniques for rehabilitation of total or partial edentulism. Implant-supported overdentures have become an effective treatment alternative for edentulous patient [6]. The success and maintenance of implant rehabilitation depends on many factors. The amount of keratinized tissue (KT) around implants may be important for peri-implant tissue health. A recent systematic review concluded that lack of adequate KT around dental implants is associated with more plaque accumulation, tissue inflammation, mucosal recession, and attachment loss [7]. A complete absence of KT, especially with non-optimal oral hygiene status, may negatively influence the long-term maintenance of restored teeth and/or dental implants.

Various methods have been described for increasing KT width around the implants [8-11]. In the presence of both shallow vestibules and inadequate KT, free gingival graft (FGG) can be performed successfully [12]. This procedure can be done either before, after, or at the time of implant placement [13].

In this case report, a FGG technique was used to increase the width of KT before implant placement to improve long-term prognosis of the implant-supported overdenture in a geriatric patient.

Case Presentation

A 73-year-old female patient who was edentulous for approximately 20 years received a total prosthesis at Erciyes University, Faculty of Dentistry, Department of Prosthodontics. She did not have any medical problems and was not taking any medication. Two implants with ball attachments supporting the overdenture were planned, and the patient was referred to the Department of Periodontology. After a clinical examination, a lack of KT, a shallow vestibular sulcus, and alveolar bone loss on the mandibular anterior region were determined (Figure 1 and 2). A preoperative cone-beam computed tomography (CBCT) scan was conducted to examine the bone before deciding on periodontal plastic surgery. The CBCT images revealed that bone length and size were suitable for implants. A bilaterally FGG was

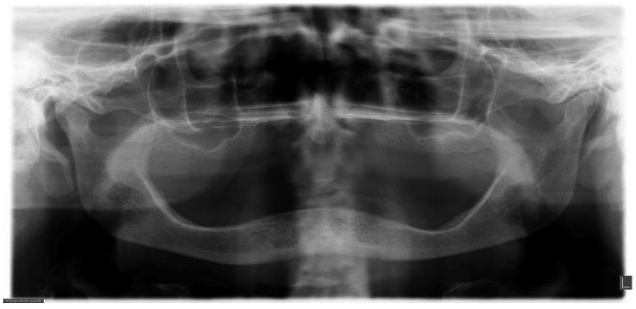

Figure 1: Panoramic radiograph before treatment.

Cakmak et al. © All rights reserved

Citation: Cakmak O, Alkan BA, Tasdemir Z, Kilinc HI and Atalay Y. Free Gingival Grafting Before Implant Placement In A Geriatric Patient : A Case Report. J Dent App. 2014;1(5): 91-94.

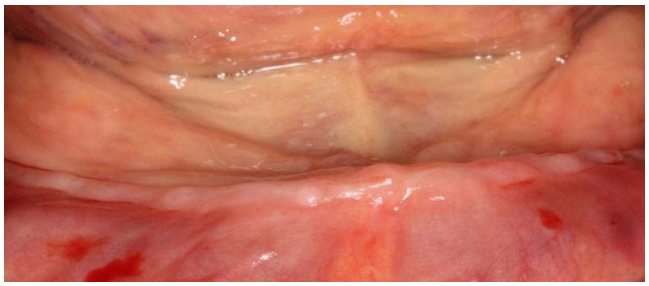

Figure 2: Preoperative clinical situation: Absence of adequate KT, decreased vestibular depth and severely resorbed ridge.

planned to provide KT prior to implant and prosthetic rehabilitation. A signed informed consent form was obtained after the patient was provided with detailed information describing the nature and duration of the surgical and prosthetic procedures.

All surgical procedures were performed by the same clinician (OC) under local anesthesia. The patient was instructed to rinse with 0.12% chlorhexidine mouthwash prior to surgery. Following the administration of local anesthesia to recipient and donor sites, the recipient sites were prepared in the canine regions (Figure 3). Tissue tags were removed and bleeding was controlled using sterile gauze dampened with saline. The desired graft size was harvested from the palate without rugae and divided into two pieces. A prefabricated acrylic stent was placed to protect the donor site. Subsequently, grafts were sutured to the recipient sites with non-resorbable and resorbable 4-0 round sutures (Dogsan, Yalincak, Trabzon, Turkey) (Figure 4a and 4b). Firm pressure was applied over the grafted areas with a saline-soaked gauge to enhance close approximation. The patient was prescribed an antibiotic (amoxicicilin/clavulanate 1000 mg, two times daily for one week), analgesic (diclofenac, 50 mg every six hours), and mouthwash (0.2% chlorhexidine-digluconate, twice a day for two weeks). The sutures were removed 10 days later (Figure 5a and 5b) and follow-up visits were carried out every two weeks during the two months (Figure 6a and 6b). The healing period was uneventful. The patient was allowed to wear a temporary total prosthesis after four weeks. After two months, an adequate amount of non-moveable KT and deep vestibular sulcus were observed at the canine regions with no signs of inflammation, and the patient was scheduled for implant surgery (Figure 7).

Implant placement was performed by routine procedures. After local anesthesia was administered, a crestal incision over the canine areas were made and the mucoperiosteal flap was raised. The osteotomies were prepared using the manufacturer's protocol and evaluated with a probe to ensure that all bony walls were intact. Then, two implants (4.1x12mm, Dentium®, Implantium, Seoul, Korea) were

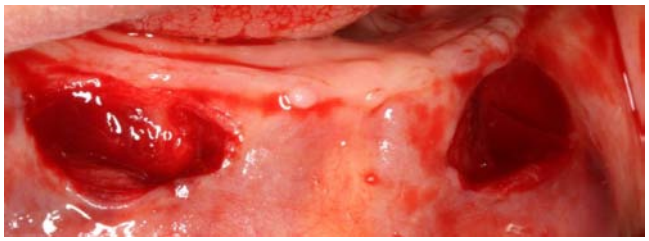

Figure 3: Recipient sites were prepared in the mandibular canine regions.

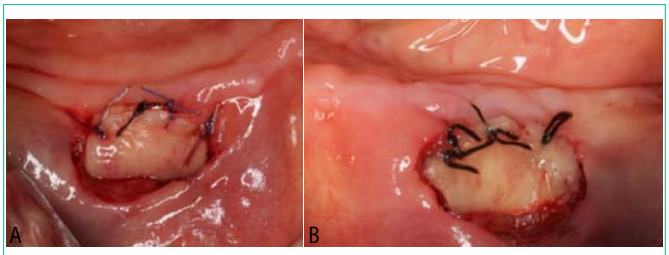

Figure 4a: Free gingival graft was sutured: right mandibular canine region.
Figure 4b: Free gingival graft was sutured: left mandibular canine region.

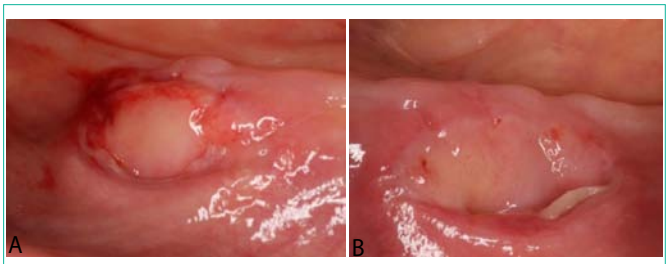

Figure 5a: Ten days after surgery after suture removal: right mandibular canine region.
Figure 5b: Ten days after surgery after suture removal: left mandibular canine region.

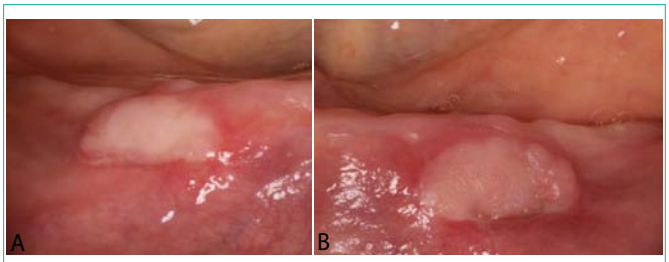

Figure 6a: Twenty-one days after surgery: right mandibular canine region.
Figure 6b: Twenty-one days after surgery: left mandibular canine region.

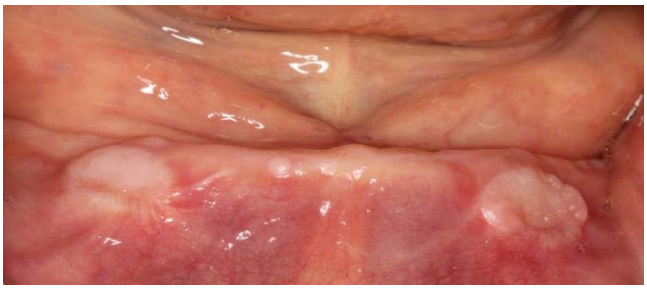

Figure 7: Two-month postoperative healing of the FGG. Note presence of enough KT and deep vestibular sulcus.

placed in the canine regions (Figure 8). The implants were placed using a two-stage surgical procedure. The flap was repositioned and sutured with 3.0 non-resorbable round sutures (Dogsan, Yalincak, Trabzon, Turkey) (Figure 9). The same medications and mouthwash were prescribed, and the sutures were removed after seven days. Healing was uneventful (Figure 10). Aproximately 3 months after implant placement, a panoramic radiograph was taken and reviewed, which showed that the implants were osseointegrated and completely healthy (Figure 12). After gingiva formers were placed (Figure 11a and 11b), oral hygiene instructions were provided and the patient was referred to the Department of Prosthodontics for permanent

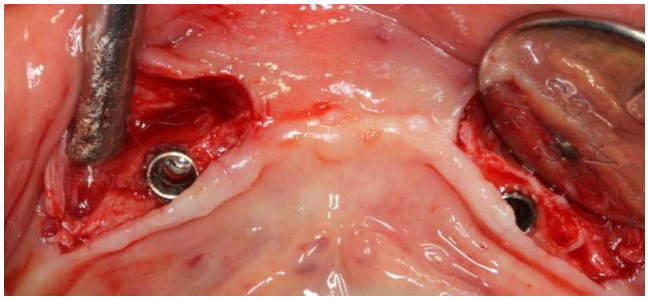

Figure 8: Implants were placed at the mandibular canine regions.

Figure 9: Primary and tension-free closure of flaps.

Figure 10: One month after implant surgery.

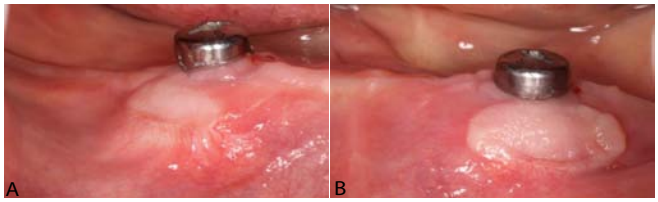

Figure 11a: Three months after implant surgery: right mandibular canine region.
Figure 11b: Three months after implant surgery: left mandibular canine region.

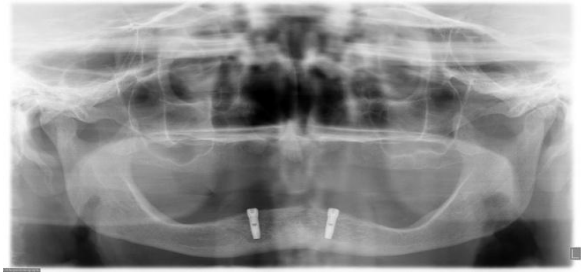

Figure 12: Panoramic radiograph: three months after implant surgery.

dentures. The treatment was finalized by providing a maxillary total prosthesis and a mandibular implant-supported overdenture. Patient was followed for 18 months without any problem (Figure 13 and 14).

Discussion

This clinical case report presents the treatment of a geriatric patient with atrophic mandible, shallow vestibular depth, and inadequate KT. The patient's chief complaint was the lack of retention of her mandibular complete denture. A FGG and two implants with ball attachments supporting the overdenture were performed, respectively.

It is known that the implant to bone and the KT interface are weaker than that of natural teeth [10]. Altthough the bacteria that causes peri-implantitis and peri-implant mucositis is similar to the bacteria that causes periodontal disease, the magnitude of destruction in dental implants may be more devastating [10]. Thus, soft tissue surrounding implants may play an important factor in disease initiation and progression. There are varying opinions regarding the influence of KT surrounding dental implants. Wennstrom and Derks have claimed that, in good oral hygiene conditions, the marginal gingiva around dental implants is clinically healthy, even when there is an absence of KT [14]. However, Bouri et al. [15], reported a relationship between implant survival rate and KT width. A recent systematic review concluded that lack of adequate KT around dental implants is associated with more plaque accumulation, tissue inflammation, mucosal recession, and attachment loss [7]. Indeed, proper oral hygiene practices are very difficult to achieve around dental implants without the protection of KT, especially in geriatric patients who are not able to maintain adequate oral hygiene.

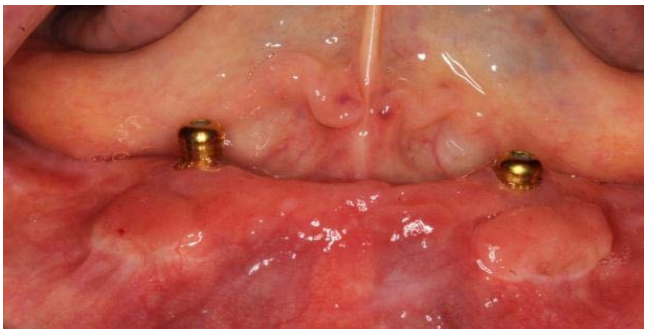

Figure 13: Stable peri-implant soft tissue, 16 months after implant placement.

Figure 14: The final intraoral view at 18 months.

In addition, a shallow vestibule may cause food retention, impaired quality of oral hygiene procedures, and mobility of the peri-implant mucosa [16]. Therefore, to enhance long-term peri-implant health and prognosis of the prosthesis, FGGs in conjunction with vestibuloplasty was performed before implant placement in this case report.

Various surgical methods, such as an apically positioned flaps, laterally positioned flaps, FGGs, or connective tissue grafts, can be applied to maximize the width of KT [11]. To our knowledge, the most indicated procedure to increase the width of KT and depth of the vestibular sulcus seems to be FGGs, which is a predictable and reliable surgical procedure. However, this procedure may cause some problems for the patient, such as the need for a donor site, two surgical sites with a possibility of pain after surgery, and a longer treatment period [17]. Moreover, wound healing may be another risk factor for geriatric patients. However, in this case study, the healing period was uneventful and the patient's compliance was excellent. An acceptable amount of non-moveable KT and deep vestibular sulcus was observed at the canine regions with no signs of inflammation after periodontal plastic surgery.

A FGG procedure may be performed before, after, or at the time of implant placement [13]. The grafting procedure was carried out before the implant surgery to facilitate tissue manipulation at the time of implant placement by increasing the width of KT around the implants. A wider zone of KT may provide easier flap reflection and suturing and a decreased surgical time. This situation may be important in the post-operative period for geriatric patients because of the possibility of compromised healing. However, obtained KT may be moveable if a FGG operation is performed after implant placement.

It has been reported that ball attachments are less costly, less technique sensitive, and easier to clean than bars [18]. In addition, the probability of gingival hyperplasia reportedly is more easily reduced with ball attachments [19]. Thus, ball attachments were used in this case report.

Conclusion

Using FGGs is a safe and predictable method to increase KT, thus allowing for better oral hygiene for the patient. Maintaining proper oral hygene is especially important for geriatric patients beause of the possibility of decreased hand flexibility. Mucogingival surgery resulted in an appropriate environment for proper oral hygiene procedures for the geriatric patient. However, the patient was informed that the long-term prognosis of the prosthesis would depend on the supporting periodontal therapy. The prognosis was highly favorable and no significant soft or hard tissue changes were observed during the follow-up period. It was observed that the results were maintained and the patient was satisfied by the esthetic and functional outcomes of her overdenture after 18 months.

Acknowledgment

The authors report no conflicts of interest related to this case report.

References

1. Turkyilmaz I, Company AM, McGlumphy EA. Should edentulous patients be constrained to removable complete dentures? The use of dental implants to improve the quality of life for edentulous patients. Gerodontology. 2010; 27: 3-10.
2. Petersen PE, Yamamoto T. Improving the oral health of older people: the approach of the WHO Global Oral Health Programme. Community Dent Oral Epidemiol. 2005; 33: 81-92.
3. Krustrup U, Erik Petersen P. Periodontal conditions in 35-44 and 65-74-year-old adults in Denmark. Acta Odontol Scand. 2006; 64: 65-73.
4. Artnik B, Premik M, Zaletel-Kragelj L. Population groups at high risk for poor oral self care: the basis for oral health promotion. Int J Public Health. 2008; 53:195-203.
5. Polzer I, Schimmel M, Muller F, Biffar R. Edentulism as part of the general health problems of elderly adults. Int Dent J. 2010; 60: 143-155.
6. Meijer HJ, Geertman ME, Raghoebar GM, Kwakman JM. Implant-retained mandibular overdentures: 6-year results of a multicenter clinical trial on 3 different implant systems. J Oral Maxillofac Surg. 2001; 59: 1260-1268; discussion 1269-1270.
7. Lin GH, Chan HL, Wang HL. The significance of keratinized mucosa on implant health: a systematic review. J Periodontol. 2013; 84: 1755-1767.
8. Zigdon H, Machtei EE. The dimensions of keratinized mucosa around implants affect clinical and immunological parameters. Clin Oral Implants Res. 2008; 19: 387-392.
9. Nemcovsky CE, Moses O. Rotated palatal flap. A surgical approach to increase keratinized tissue width in maxillary implant uncovering: technique and clinical evaluation. Int J Periodontics Restorative Dent. 2002; 22: 607-612.
10. Maksoud MA. Manipulation of the peri-implant tissue for better maintenance: a periodontal perspective. J Oral Implantol. 2003; 29: 120-123.
11. Thoma DS, Benic GI, Zwahlen M, Hammerle CH, Jung RE. A systematic review assessing soft tissue augmentation techniques. Clin Oral Implants Res. 2009; 20 Suppl 4: 146-165.
12. Metin M, Dolanmaz D, Alkan A. Evaluation of autogenous grafts used in vestibuloplasty. J Int Med Res 2003; 31: 335-339.
13. Misch CE, Al-Shammari KF, Wang HL. Creation of interimplant papillae through a split-finger technique. Implant Dent. 2004; 13: 20-27.
14. Wennstrom JL, Derks J. Is there a need for keratinized mucosa around implants to maintain health and tissue stability? Clin Oral Implants Res. 2012; 23 Suppl 6: 136-146.
15. Bouri A Jr., Bissada N, Al-Zahrani MS, Faddoul F, Nouneh I. Width of keratinized gingiva and the health status of the supporting tissues around dental implants. Int J Oral Maxillofac Implants. 2008; 23: 323-326.
16. Ono YNM, Cappetta EG. The importance of keratinized tissue for implants. In: Nevins M, Mellonig JT, editors Implant therapy– clinical approaches and evidence of success, Chicago: Quintessence. 2003: 227-237.
17. Haghighati F, Mousavi M, Moslemi N, Kebria MM, Golestan B. A comparative study of two root-coverage techniques with regard to interdental papilla dimension as a prognostic factor. Int J Periodontics Restorative Dent. 2009; 29: 179-189.
18. Batenburg RH, Raghoebar GM, Van Oort RP, Heijdenrijk K, Boering G. Mandibular overdentures supported by two or four endosteal implants. A prospective, comparative study. Int J Oral Maxillofac Surg. 1998; 27: 435-439.
19. Krennmair G, Ulm C. The symphyseal single-tooth implant for anchorage of a mandibular complete denture in geriatric patients: a clinical report. Int J Oral Maxillofac Implants. 2001; 16: 98-104.

J Dent App - Volume 1 Issue 5 - 2014
ISSN : 2381-9049 | www.austinpublishinggroup.com
Cakmak et al. © All rights reserved

Citation: Cakmak O, Alkan BA, Tasdemir Z, Kilinc HI and Atalay Y. Free Gingival Grafting Before Implant Placement In A Geriatric Patient : A Case Report. J Dent App. 2014;1(5): 91-94.