

Case Report

Post Traumatic Foreign Body Implantation of Mandible Masquerading as Dentoalveolar Abscess-A Case Report

Deepa JP*, Dheeraj S, Gagan P, Aravinda K, Avani D and Rajesh G

Department of Oral Medicine, Diagnosis and Radiology, Swami Devi Dyal Dental College and Hospital, India

*Corresponding author: Deepa Jatti Patil, Department of Oral Medicine, Diagnosis and Radiology, Swami Devi Dyal Dental College and Hospital, Golpura, Panchkula, Haryana, India

Received: March 12, 2016; Accepted: May 23, 2016;

Published: May 25, 2016

Abstract

Background: Foreign body implantation in the oral cavity can be exogenous and endogenous in origin. After trauma they can instigate an array of biological reactions such as inflammation, infections, allergic reactions, toxic events and tissue alterations. If the foreign body is not removed it can cause delayed healing with superimposed infections. Such foreign bodies can be missed during examination.

Case Details: A 35 year old male patient, reported with a chief complaint of pain, swelling and recurrent pus discharge in the lower right back region of the jaw since 2 months. He had a history of trauma six months back and was treated for the same by a local surgeon. With the help of meticulous history, clinical examination and imaging techniques presence of foreign body was detected which caused persistent infection.

Conclusion: A careful history, clinical examination and imaging techniques should be considered for patients with any traumatic injuries. Intraosseous and extraosseous foreign body implantation should be included in the differential diagnosis of the soft tissue masses, mainly in the presence of previous surgery or accidental trauma history.

Keywords: Foreign body implantation; Trauma; Stones; Dysesthesia; Radiographs

Introduction

The term foreign body reaction is used for the tissue response to extraneous materials that becomes implanted in or beneath dermis. Such reactions occur as a result of direct accidental penetration of the exogenous materials or due to iatrogenic cause, both inducing an inflammatory reaction [1]. Road Traffic Accident (RTA) is one of the common causes of exogenous implantation [2].

Foreign-bodies can penetrate soft tissues in connection with accidents through open wounds and lacerations [3]. The presence of a foreign-body impairs the healing of the tissues, inducing biological reactions like inflammation, infections, allergic reactions, toxic events and tissue alterations. Manuscripts on foreign-body reactions instigating from a traumatic Implantation with different objects, including fish bones, teeth and metallic material have been well documented in the literature [4,5].

This case report describes an unusual manifestation of foreign body implantation after trauma, which masqueraded as a dental infection. With the help of careful history, clinical examination and imaging techniques presence of foreign body was detected. On surgical exploration the foreign bodies were multiple stones which evoked an inflammatory reaction resulting in delayed healing and recurrent infection.

Case Presentation

A 35 year old male patient reported to the Department of Oral Medicine & Radiology with a chief complaint of pain and swelling in the lower right back region of the jaw since 2 months. The patient was

apparently normal 6 months back after which he met with an accident and suffered trauma to the right side of the lower jaw. He was treated by a local practitioner, who placed sutures on the right angle of the mandible. Two months back he noticed pus discharge in the same region. Pain is sudden in onset, sharp and radiating to the ear of the same side. No sign of fever or dysphasia is present. He also complains of altered sensation of the lower lip since 2-3 months which affected his daily activities. His medical history was non contributory. On extraoral examination, there was dysesthesia of the right side of the lower lip. On intraoral examination a solitary, erythematous, well defined, oval swelling is seen extending from mesial surface of the 46 to the mesial surface of lower right second molar. It is non tender and hard in consistency. A draining sinus is also present in the buccal vestibule of 47 (Figure 1). Right sub mandibular lymph nodes were palpable, soft in consistency and mobile A provisional diagnosis

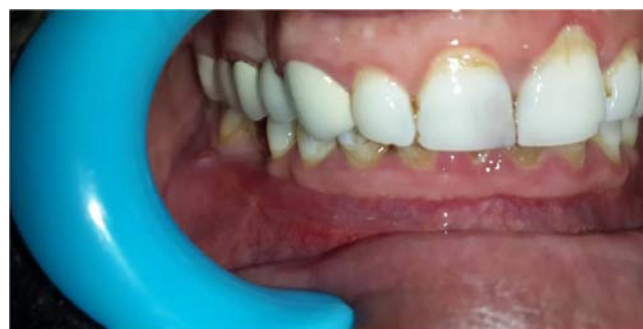

Figure 1: Intraoral swelling with sinus formation.

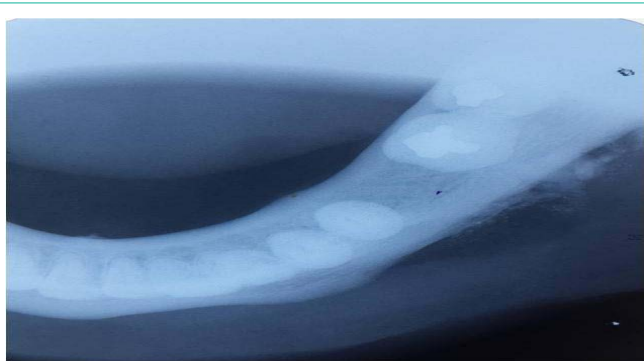


Figure 2: Right lateral occlusal radiograph showing multiple radio-opacities along the periosteal surface.

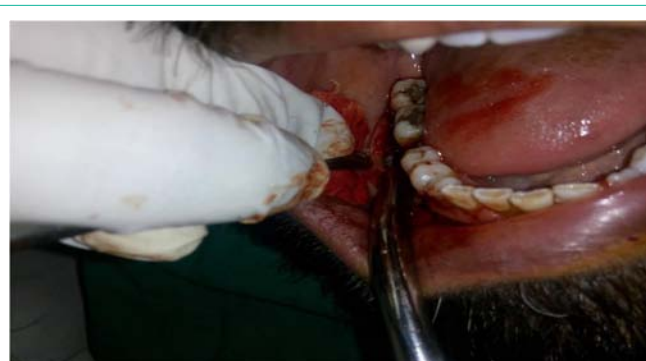

Figure 4: Surgical exploration of the foreign bodies.

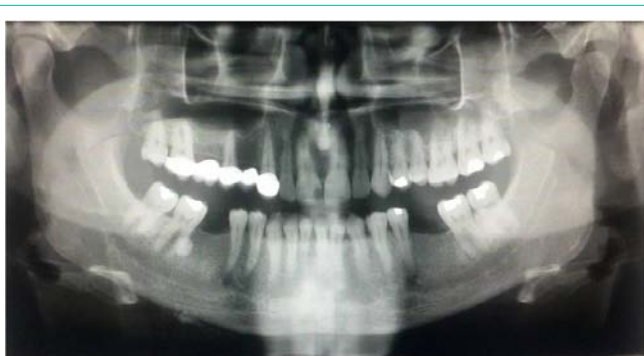

Figure 3: Panoramic radiograph depicting the multiple radio-opacities along the periosteal surface.

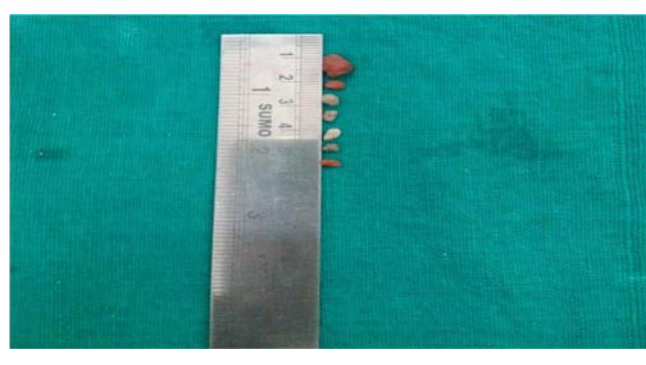


Figure 5: Multiple stones excised from the lesion.

of Dentoalveolar abscess secondary to trauma was given. Chronic osteomyelitis was considered under differential diagnosis. An Intra oral periapical radiograph (IOPA) with 47, 48, right lateral occlusal radiograph and panoramic radiograph was advised. IOPA radiograph revealed a well defined round radio-opacity with comparable radio-density as enamel overlying the mesial root of 47 above the inferior alveolar canal. Right lateral lower occlusal radiograph revealed multiple irregular shaped radio-opacities along the inferior border of mandible on the periosteal surface around 46, 47 regions with no expansion of the cortical plate (Figure 2). Panoramic radiograph also revealed multiple well defined radio-opacity overlying 47 and multiple ill defined radio-opacities along the inferior border of mandible (Figure 3). After radiological investigations, a differential diagnosis of chronic osteomyelitis, foreign body implantation, dystrophic calcification and soft tissue radio-opacities was given. The differential

diagnosis is discussed in (Table 1). Pus was aspirated and sent for culture and sensitivity. It showed the presence of staphylococcus albus micro-organism. Due to the previous history of trauma and the radiographic presentation a final diagnosis of dentoalveolar abscess secondary to foreign body implantation was given.

Patient was prescribed Capsule Amoxicillin and clavulanic acid (625 mg) twice daily for five days and Tablet Ibuprofen 400 mg and Paracetamol 325 mg for 3 days. Surgical exploration under local anaesthesia revealed the presence of a stone, implanted in the buccal mucosa, the shadow of which was seen overlying the mesial root of 47 (Figure 4). External excision was given in the sub mandibular region along the right lower border of mandible. On exploration multiple hard glistening stones were seen. The wound was irrigated and sutures were placed (Figure 5).

Thus, the dentoalveolar abscess was due to the presence of the stones which were embedded since six months and invoked a

Table 1: Radiographic differential diagnosis of soft tissue radio-opacities in posterior mandibular region on plain film radiography.

S. No	LESION	RADIOGRAPHIC FEATURES
1	Foreign body radio-opacities	Stones, splints, glass occurring as homogenous radio-opacities of varying degree.
2	Dystrophic calcifications occurring in chronic inflammation or dead and dying tissues	Multiple fine to large size of irregular radio-opacities.
3	Lymph node calcification	Single or multiple in number. Located commonly either at or below the inferior border of mandible. Well defined, irregular shaped with varying degrees of radio-opacities.
4	Sialoliths with signs of infection in the duct orifice and salivary glands	Single / multiple, located most commonly overlying the teeth in the body and ramus of the mandible, well defined and with homogenous radio-opacities.
5	Phlebolith associated with vascular lesions	Located in the body and ramus of the mandible. Usually multiple in number. Round or oval shaped with homogenous radio-opacity with presence of laminations giving a Bull's eye appearance or target appearance.
6	Tonsilloliths	Single or multiple radio-opacities over the mid portion of mandibular ramus. Cluster of multiple, small, ill defined radio-opacities.
7	Chronic Osteomyelitis with sinus formation	Moth eaten radiolucency with Multiple radio-opacities of sequestra internally. Periosteal deposition in onion skin pattern

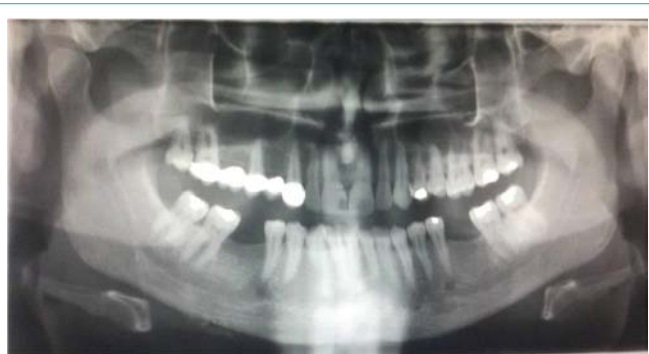

Figure 6: Post-operative Panoramic radiograph after removal of the stones.

foreign body reaction. The patient was recalled after 1 week and post operative radiograph was taken (Figure 6). The patient is presently under observation.

Discussion

Foreign body implantation in the oral cavity can be exogenous and endogenous in origin. Endogenous substances like impression and restorative material, implants, etc can be implanted iatrogenically. These foreign bodies get dislodged and produce a foreign body reaction or compress the adjacent anatomic structures. Exogenous implantations occur commonly after trauma and include wood, glass splinters, sharp metallic objects and stones near the trauma site [3].

When exogenous materials penetrate body tissue, there is usually a phase of acute inflammation in response to the injury. Persistent presence of such inert substance within tissue results in a granulomatous reaction (it consisting of an accumulation of monocytes, tissue macrophages, epithelioid histocytes and giant cells with fibroblastic reaction to lay down new connective tissue around the area of foreign body deposition). Thus, penetration injuries may result in formation of implanted cysts mixed with granulomatous response. Such response is different from immune specific granulomatous inflammatory reactions based on duration, dynamics, severity and evolution. The clinical presentation of body reaction may vary based on physical composition of material, size, their non digestible characteristics and site of injury [6].

In the present case, due to the size and non degradable characteristic of the stones, these particles didn't in volute and were found in the lesion. They incited a foreign body reaction with infection by anaerobic and mycotic organisms. This led to the formation of abscess and sinus in the present case.

Due to the presence of stones for a long duration, it caused compression of inferior alveolar nerve. Foreign body (inflammatory) reaction or injury of inferior alveolar nerve (IAN)/mental nerve may be classified into metallic or non-metallic, temporary or permanent, chemico-mechanical or thermal [7]. Steddon has classified peripheral nerve injuries as neurapraxia, axonotmesis and neurotmesis [8]. Neurapraxia is a temporary conduction block after mild compression of the nerve trunk (i.e. parasthesia or dysaesthesia of the lip and chin region in case of IAN/mental nerve) [9]. Axonotmesis, a more serious condition, results from degeneration of the afferent fibers as a result of internal/external irritation (i.e. anaesthesia) [10]. While, in neurotmesis the nerve is completely severed which results

in permanent paraesthesia, which can be corrected with micro neurosurgical interventions with variable prognosis [8]. In our patient, dysaesthesia (neurapraxia) in the distribution of inferior alveolar nerve resulted from compression of the nerve with no structural damage; symptoms can be worsened with chronic irritation and perineural inflammation. Reports of dysesthesia and neuralgia after foreign body implantation of restorative materials, after surgery and RTA has been well documented in the literature [11,12].

Tissue reactions to foreign materials are commonly encountered in oral cavity against large number of dental materials. The more common iatrogenic instances such as accidental penetration of metallic restoration or endodontic sealers and fillers are already reported in literature which induces toxic reaction [13,14]. Occurrence of pyogenic infections with vegetative matters is also common in oral cavity [15]. Review of the literature indicates foreign body reaction with aluminum silicate and black plastic tapes in oral cavity. A case of foreign body reaction to wood pieces after a RTA has been reported [16]. Review of the literature indicates foreign body reaction with aluminium silicate and plastic tapes in the oral cavity [17].

Diagnosis in such cases should include thorough history taking supplement by radiologic examination. In our case plain film radiography played an important role in detecting the nature of the lesion. The foreign body could be seen as well defined radio-opacities of varying size. Table 1 discusses the various soft tissue radio-opacities in posterior mandibular region on plain film radiography.

In case of inert materials like wood ultrasonography or computed tomography can be performed. Imaging technique may be helpful but may not yield consistent results in certain radiolucent materials like glass, wooden splinters or vegetative matters [18].

Occurrence of foreign bodies in the head and neck are common. Thorough search of literature did not reveal any case of implantation of stones in the mandible causing an inflammatory reaction and dysaesthesia. Ours is the first case reported.

To conclude, identification of such lesions is important for proper evaluation and patient management. It is suggested that after trauma the involved bone and traumatized soft tissue must be thoroughly cleaned and irrigated to remove any residual bodies. Intraosseous and extraosseous foreign body implantation should be included in the differential diagnosis of the soft tissue masses, mainly in the presence of previous surgery or accidental trauma history.

References

1. Burns T, Breathnach S, Cox N, Griffiths C. Rook's Text book on dermatology, 8th edition. 2013; 2: 28-39.
2. Paden M, McGee K, Krug E. Injury: A leading cause of the global burden of disease. World Health Organization. 2000; 2002.
3. Silveira VAS, Carmo ED, Colombo CED, Cavalcante ASR, YR Carvalho. Intraosseous foreign-body granuloma in the mandible subsequent to a 20-year-old work-related accident. Med Oral Patol Oral Cir Bucal. 2008; 13: e657-660.
4. Baldwin JK, Newton GM. A tooth located in the tongue. Oral Surg Oral Med Oral Pathol. 1978; 45: 860-862.
5. Girdler NM. Unusual delayed sequel to facial trauma. Oral Surg Oral Med Oral Pathol. 1993; 75: 264.
6. Aggrawal J, Shenai KP, Chatra L, Kumar Rao P, Veena KM. Foreign body

- penetration: A missed diagnosis. *Pacific Journal of Medical Sciences*. 2012; 9: 81-86.
7. Gallas-Torreira MM, Reboiras-López MD, García-García A, Gándara- Rey J: Mandibular nerve paresthesia caused by endodontic treatment. *Med Oral*. 2003, 8: 299-303.
 8. Seddon HJ: Three types of nerve injury. *Brain*. 1943; 66: 237-288.
 9. Donoff RB: Nerve regeneration: basic and applied aspects. *Crit Rev Oral Biol Med*. 1995; 6:18-24.
 10. Becelli R, Renzi G, Carboni A, Cerulli G, Gasparini G: Inferior alveolar nerve impairment after mandibular sagittal split osteotomy: an analysis of spontaneous recovery patterns observed in 60 patients. *J Craniofac Surg*. 2002; 13: 315-320.
 11. Kafas P, Upile T, Angouridakis N, Stavrianos C, Dabarakis N, Jerjes W. Dysaesthesia in the mental nerve distribution triggered by a foreign body: a case report. *Cases J*. 2009; 2: 1-4.
 12. S. Padmashree, Chaitra H. Ramprakash, and Rema Jayalekshmy. Foreign Body Induced Neuralgia: A Diagnostic Challenge. *Case Reports in Dentistry*. 2013; 1-4.
 13. Eley BM. The fate of amalgam implanted in soft tissue - An experimental study. *J Dent Res*. 1979; 58: 1146-1152.
 14. Ektefaie MR, David HT, Poh CF. Surgical resolution of chronic tissue irritation caused by extruded endodontic filling material. *J Can Dent Assoc*. 2005; 71: 487-490.
 15. Scivetti M, Lucchese A, Ficarra G, Giuliani M, Lajolo C, Maiorano E, et al. Oral pulse granuloma: histological findings by confocal laser scanning microscopy. *Ultrastruct Pathol*. 2009; 33: 155-159.
 16. Aniece C, Parmod K, Sanjeet S, Des Raj B, Noor A, Rashid A. Foreign Body in the Wharton's Duct, a case report. *JK Sci*. 2005; 7: 61-62.
 17. Shehata E, Moussa K, Al-Gorashi A. A foreign body in the floor of the mouth. *Saudi Dent J*. 2010; 22: 141-143.
 18. Hunter TB, Taljanovic MS. Foreign Bodies. *Radiographics*. 2003; 23: 731-757.