

Clinical Image

Stafne's Bone Cavity

Cameron Y. S. Lee*

Department of Oral Maxillofacial and Reconstructive Surgery, Temple University, USA

***Corresponding author:** Cameron Y. S. Lee, Department of Oral Maxillofacial and Reconstructive Surgery, Temple University, Kornberg School of Dentistry, Philadelphia, PA, USA

Received: February 12, 2017; **Accepted:** February 27, 2017; **Published:** March 01, 2017

Clinical Image

A 51-year old Asian male presented to the office for evaluation of a radiolucency of the right posterior mandible. The radiographic lesion was observed during a dental implant consultation with his dentist to replace several missing teeth in the left posterior mandible. Panoramic radiograph revealed a well-defined unilocular radiolucency in the right posterior mandible between the inferior alveolar canal and the inferior border of the mandible (Figure 1). Cone beam CT scan was completed to obtain a definitive diagnosis which was consistent with Stafne's Bone Cavity (SBC).

SBC, also known as Stafne's cyst and lingual salivary gland inclusion defect is a lingual (medial) cortical defect of the molar region between the inferior alveolar canal and inferior border of the mandible (Figure 2,3). It is often observed during a dental examination. It represents remodeling of the bone on the medial aspect of the mandible from pressure of the submandibular salivary gland. No treatment is indicated for this benign pathologic entity.

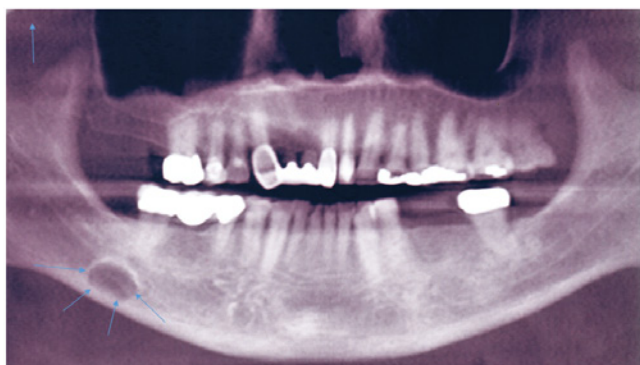


Figure 1: Panoramic radiographic showing elliptical shaped radiolucent lesion (arrows) in molar region of right posterior mandible between inferior alveolar canal and inferior border of mandible.

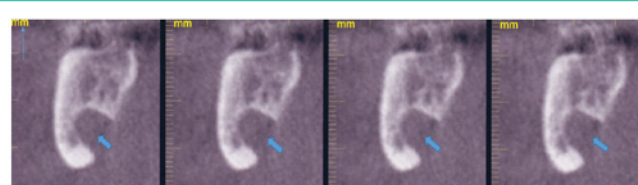


Figure 2: Lingual cortical concavity of the mandible (arrow head) observed with sagittal views of cone beam CT scan consistent with Stafne's bone cavity.

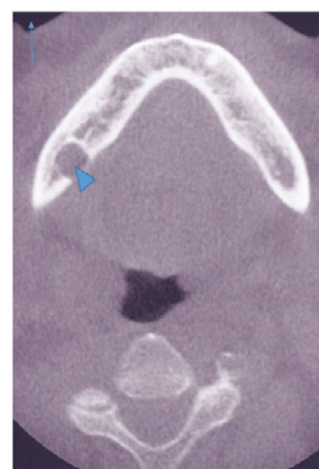

Figure 3: Cone beam CT scan axial view illustrating the lingual osseous concavity (arrow head) characteristic of Stafne's bone cavity.