

## Review Article

# Guiding Template for Direct Bracket Placement: A Hybrid Technique

Eduardo Yugo Suzuki and Boonsiva Suzuki\*

Department of Orthodontics, Bangkok Thonburi University, Bangkok

\*Corresponding author: Boonsiva Suzuki, Department of Orthodontics, Faculty of Dentistry, Thonburi University, Taweewattana, Bangkok

Received: January 30, 2019; Accepted: March 04, 2019; Published: March 11, 2019

## Abstract

A simple technique is proposed to transfer the bracket positioning planning from the dental model to the patient's mouth: Guiding Template for Direct Bracket Placement. Bracket positioning guidelines that are carefully drawn on dental models are accurately transferred to a highly transparent thermoplastic material. Small slots are then created on the guiding template to allow enough space for bracket placement in the desired position. The custom-made guiding template is then placed in the patient's mouth to guide the precise direct bracket placement, therefore facilitating appliance fixation and reducing chair time. Moreover, it has advantages over indirect bracket transfer trays since it allows freedom to the orthodontist to perform any additional bracket positioning adjustments when necessary and to carefully clean up adhesive remnants. In this procedure, the direct bonding technique is completely under the Orthodontist's control.

## Introduction

Precise bracket placement is mandatory with pre-adjusted appliances, since different prescriptions and all the information required to position the teeth in the three axes, are built into the bracket [1-3]. Moreover, correct bracket positioning during bonding results in less brackets repositioning, and minimizes additional archwire bending during the subsequent phases of orthodontic treatment, thus increasing the predictability of results [3-5]. Therefore, several types of bracket-positioning gauges have been developed and recommended to improve accurate and reproducible bracket positioning [3-9]. However, precise bracket placement still relies on the professional's individual skills and the accuracy of bonding procedures [1-3]. Moreover, considering inexperienced students in the beginning of their orthodontic clinical training, the accurate direct bracket placement procedure can be even more challenging, strenuous and time-consuming than for experienced orthodontists.

In order to achieve a more precise bracket positioning, several indirect bonding techniques have been proposed [10-13]. The main advantage of indirect bonding techniques over direct bonding techniques is to allow a precise and controlled preparation of bracket positioning in a laboratory setting. Individualized transfer trays are fabricated from a wide range of materials, such as vacuum-formed thermoplastics and silicone impression materials, and optimize bracket placement in the clinical setting, therefore reducing significantly chairtime [2-8]. The process is laborious and requires an experienced laboratory technician or a computer operator to allow the correct bracket positioning [6-8]. Moreover, indirect bonding technique still cannot be considered a gold standard for correct bracket placement because of numerous variable factors that might compromise the final accurate placement [10]. Any distortion or misalignment of brackets in the transfer tray or incorrect tray fit or lack of stability in the patient's mouth might cause errors in the final bracket positioning [11,12]. However, indirect bonding is not the most desirable technique to be used in an academic orthodontic

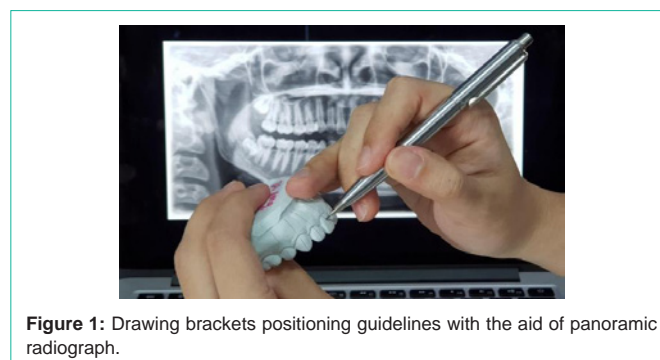

Figure 1: Drawing brackets positioning guidelines with the aid of panoramic radiograph.

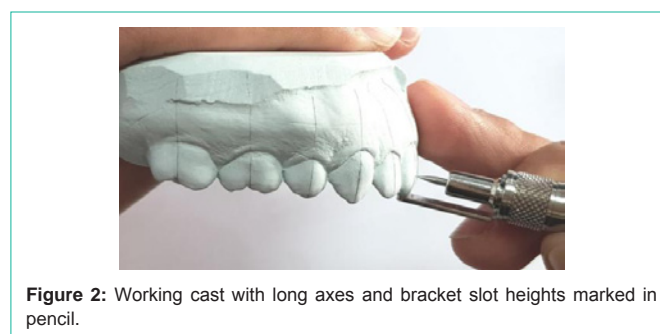
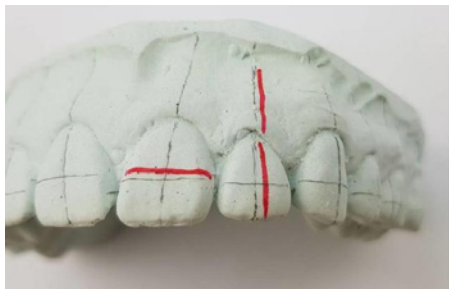


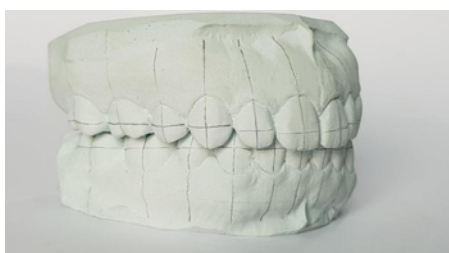Figure 2: Working cast with long axes and bracket slot heights marked in pencil.

program with students in the beginning of their clinical training.

Therefore, in order to obtain improved accuracy in bracket positioning, as observed in the indirect bonding technique, and to simplify direct bonding procedures, the authors have developed a hybrid technique: guiding template for direct bracket placement. The guiding template incorporates all features of the planned vertical and horizontal bracket positioning guidelines that are carefully drawn on the working models and accurately transferred to a highly transparent thermoplastic material. This guiding template technique allows for precise direct bracket placement in the previously-planned position,



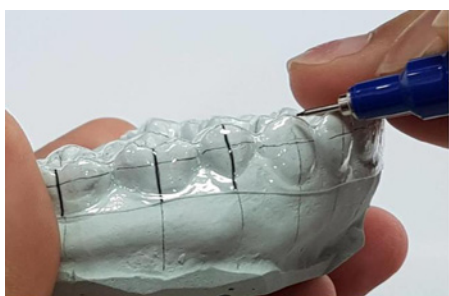**Figure 3:** Corrections can be performed during the planning phase using red marker pencil.



**Figure 4:** Cast in occlusion to ensure enough space for bracket placement.



**Figure 5:** Highly transparent thermoplastic trays.



**Figure 6:** Planned bracket positioning guidelines are transferred to the tray.

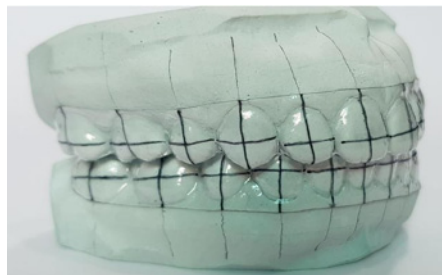therefore offering a valuable tool for inexperienced students in the beginning of their clinical orthodontic training.

Detailed step-by-step information regarding the preparation of the proposed guiding template for direct bracket placement is presented.

## Guiding Template Fabrication

### Laboratory setting

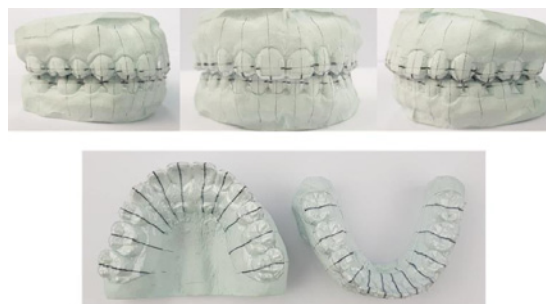
- Maxillary and mandibular working models of a patient are



**Figure 7:** Guiding template on the working cast.



**Figure 8:** Creation of small slots for easy bracket placement.



**Figure 9:** Guiding template with slots on the working cast.

obtained. All defects and imperfections are removed.

- Bracket positioning guidelines, including vertical and horizontal reference lines are carefully drawn on the working models using a sharp pencil. The vertical reference guideline must coincide with the tooth long axis (Figure 1). The accuracy of these vertical guidelines can be obtained by assessing panoramic radiographs. Horizontal guidelines or bracket slot height positions are drawn using gauges and bracket positioning charts (Figure 2).

- Any corrections of planning reference lines are performed using a sharp red pencil for educational purposes (Figure 3).

- The treatment plan should be reviewed with working casts in occlusion to ensure that bracket placement does not interfere with the patient's occlusion (Figure 4).

- Highly transparent vacuum-formed thermoplastic material 0.5 mm-thick (Duran, Scheu Dental GmbH, Iserlohn, Germany) is obtained (Figure 5).

- Planned bracket positioning guidelines are transferred to the thermoplastic material using permanent markers (thickness 0.3 mm) (Figures 6,7).



Figure 10: Guiding templates.

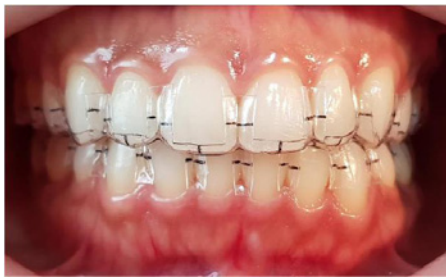

Figure 11: Guiding template on the patient's mouth.

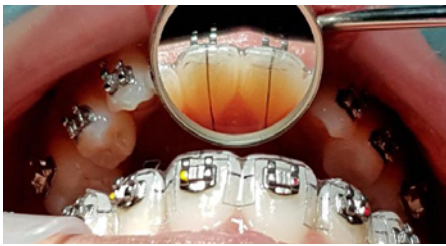

Figure 12: Bracket placement aided with the guiding template.

- Small slots are created on the tray to allow enough space for free bracket placement in the desired position. Any material excess is removed to avoid interference during insertion and removal of the guiding template (Figure 8).

- The guiding template is inserted on the working model to assure that the planned guidelines are correctly transferred (Figures 9,10).

#### Clinical setting

- The guiding template is inserted in the patient's mouth for verification of its fit. The guiding template is removed to allow tooth preparation for bonding (Figure 11).

- Teeth are prepared for direct bonding using the standard procedures: pumice and etching with phosphoric acid and rinsing with water.

- Brackets are placed into the desired positions, aided by the guiding template. Gentle pressure is applied on the bracket to ensure a uniform bracket base-enamel adhesive layer and to increase mechanical strength.<sup>13</sup> All bonding excess is carefully cleaned up to avoid plaque accumulation [14] (Figures 12,14).

- Fine bracket adjustment is performed with the guiding template in position. Lingual and palatal vertical guidelines are useful to ensure correct positioning (Figure 15).

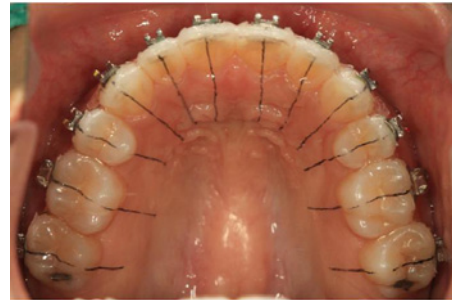

Figure 13: Occlusal view.

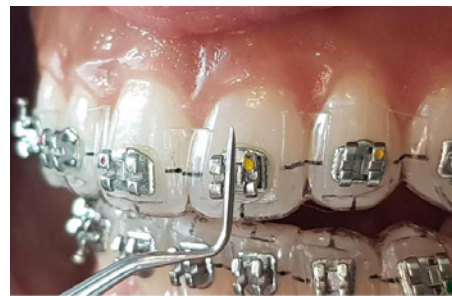

Figure 14: Fine bracket adjustment aided with the guiding template.

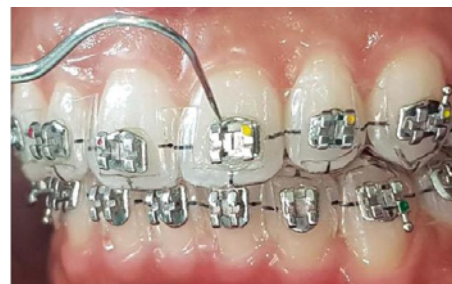

Figure 15: Adhesive remnant clean up.

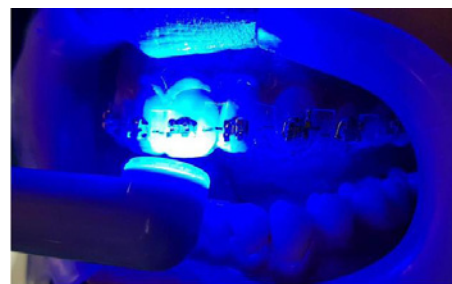

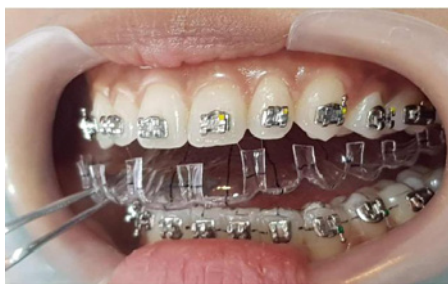Figure 16: Guiding template allows efficient polymerization.

- Direct light curing is performed with the guiding template in position. Light cure is performed on mesial and distal surfaces, following standard procedures (Figure 16).

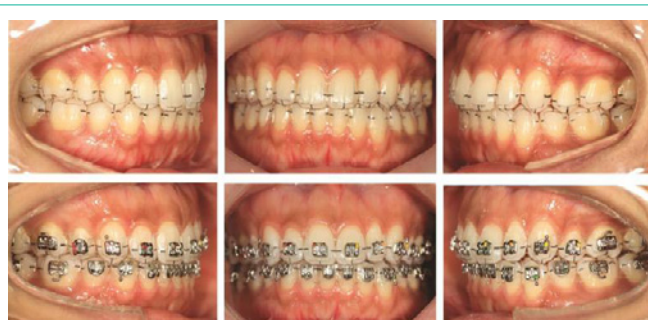- The guiding template is removed. Brackets are accurately placed according to laboratory-planned position (Figures 17,18).

#### Discussion

This article describes the step-by-step fabrication of a custom-



**Figure 17:** Guiding template removal.



**Figure 18:** Bracket placement with the guiding template.

made guiding template for direct bracket placement. The main purpose of this technique is to facilitate the transfer to the patient's teeth of the laboratory-planned bracket positioning guidelines. With the guiding template, the use of additional positioning-brackets to orient the practitioner during the bracket placement is eliminated, consequently simplifying and reducing chairtime.

Several indirect bonding techniques have been developed in order to simplify bracket placement and reduce chairtime [6-13]. These techniques also claim to increase the accuracy and precision of bracket positioning, since the bracket positioning guidelines are carefully drawn on the working models [4]. Direct visualization of the working model confirms correct assessment of any particular crown rotation, chipped or worn teeth and any particular anatomical variation, therefore allowing adequate site for bracket placement [5]. Moreover, with the careful assessment of panoramic radiographs it is also possible to ensure the correct inclination of the long axis of each tooth.

In this article, the guiding template technique takes advantage of the indirect bonding procedures, such as the careful planning of the bracket guidelines that are drawn on working casts and the transfer trays. However, in the present article, the bracket transfer tray is replaced by the custom-made guiding template for direct bracket. Therefore, simplifying bracket placement while reducing chair time and increasing patient comfort during the procedure.

The proposed guiding template technique also takes full advantage of the direct bonding procedures, advantages such as applying gentle pressure on the bracket to allow a uniform layer of adhesive on the bracket base-enamel surface to ensure correct placement. Moreover, it allows the careful removal of excess adhesive flash that contributes to plaque accumulation, potentially risks the occurrence of white spot

lesions [14]. Additionally, direct bonding avoids any undesirable move of transfer trays and consequently the bracket adhesive gel and allows for direct application of light curing to the adhesive. These conditions are often critical for the success of most of the indirect bonding techniques.

Another important advantage of the presented technique is the possibility of carefully reviewing the plan of each guideline on the working model before transferring this information to the definitive guiding template.

These beneficial features presented with the guiding template described in this article are extremely important for achieving confidence of the practitioner during the setting the fixed appliance. This is particularly important for orthodontic training purposes, where inexperienced students still require a long time to build up their confidence and knowledge for correct diagnosis and treatment planning. And the setting up the fixed appliance with accurate bracket placement should not be ignored. Therefore, the guiding template for direct bracket placement has been successfully incorporated in our orthodontic graduate program as an important preparation aspect before bracket placement.

The authors take time and care to achieve maximum accuracy in bracket positioning at the planning phase of the treatment. During treatment, bracket position is monitored and reviewed at adjustment visits. Using the guiding template described in this article, it is possible, in most cases, to avoid the need to reposition the brackets in the latter phases of treatment. This optimizes the efficiency of the treatment and improves consistency of results.

## Acknowledgement

The authors acknowledge the assistance of Dr. M. Kevin O Carroll, Professor Emeritus of the University of Mississippi School of Dentistry, USA, and Faculty Dentistry Bangkok Thonburi University, Thailand, in the preparation of the manuscript. This study was supported by grants MRG5080344 and MRG5080347 from Thailand Research Funding.

## References

- McLaughlin RP, Bennett JC, Trevisi H. Systemized orthodontic treatment mechanics. Edinburgh, Scotland: Mosby; 2001.
- Sondhi A. Efficient and effective indirect bonding. *Am J Orthod Dentofacial Orthop.* 1999; 115: 352-359.
- White LW. An expedited indirect bonding technique. *J Clin Orthod.* 2001; 35: 36-41.
- Nojima LI, Araújo AS, Alves Júnior M. Indirect orthodontic bonding—a modified technique for improved efficiency and precision. *Dental Press J Orthod.* 2015; 20: 109-117.
- Guenther TA, Larson BE. Indirect bonding: a technique for precision and efficiency. *Semin Orthod.* 2007; 13: 58-63.
- Kalange JT, Thomas RG. Indirect bonding: a comprehensive review of the literature. *Semin Orthod.* 2007; 13: 3-10.
- Koo BC, Chung CH, Vanarsdall RL. Comparison of the accuracy of bracket placement between direct and indirect bonding techniques. *Am J Orthod Dentofacial Orthop.* 1999; 116: 346-351.
- Aguirre MJ, King GJ, Waldron JM. Assessment of bracket placement and bond strength when comparing direct bonding to indirect bonding techniques. *Am J Orthod.* 1982; 82: 269-276.

9. Fortini A, Giuntoli F, Franchi L. A simplified indirect bonding technique. *J Clin Orthod.* 2007; 41: 680-683.
10. Ciuffolo F, Tenisci N, Pollutri L. Modified bonding technique for a standardized and effective indirect bonding procedure. *Am J Orthod Dentofacial Orthop.* 2012; 141: 504-509.
11. Wendl B, Droschl H, Muchitsch P. Indirect bonding: a new transfer method. *Eur J Orthod.* 2008; 30: 100-107.
12. Castilla AE, Crowe JJ, Moses JR, Wang M, Ferracane JL, Covell DA Jr. Measurement and comparison of bracket transfer accuracy of five indirect bonding techniques. *Angle Orthod.* 2014; 84: 607-614.
13. Zachrisson BU, Brobakken BO. Clinical comparison of direct versus indirect bonding with different bracket types and adhesives. *Am J Orthod.* 1978; 74: 62-78.
14. Armstrong D, Shen G, Petocz P, Darendeliler MA. Excess adhesive flash upon bracket placement. A typodont study comparing APC PLUS and Trans bond XT. *Angle Orthod.* 2007; 77: 1101-1108.