Austin Journal of Dermatology

Open Access

Austin Publishing Group

Clinical Image

Dermoscopy in Molluscum Contagiosum: A Novel Diagnostic Aide

Mahajabeen M, Ankad BS*, Alekhya R and Saipriya G

Department of Dermatology, S. Nijalingappa Medical College, India

***Corresponding author:** Ankad BS, Associate Professor, Department of Dermatology, S. Nijalingappa Medical College, Bagalkot-587103, Karnataka State, India

Received: June 02, 2016; **Accepted:** June 09, 2016; **Published:** June 10, 2016

Keywords

Molluscum contagiosum; Dermoscopy; Telangiectasia; White structureless areas

Clinical Image

Molluscum Contagiosum (MC) is a viral infection of the epidermal keratinocytes that results in a skin lesion with characteristic intracytoplasmic inclusions caused by pox virus. This common disease is confined to the skin and mucous membranes and produces benign, self limited, multiple umbilicated papular eruptions [1]. Although MC can be diagnosed easily, some factors such as lack of central umbilication, associations with other types of dermatological lesions, atypical lesions, small, single, initial lesions, inflammatory lesions and lesions with perilesional eczema may hamper diagnosis of MC [2]. Therefore, there is a need for early and easy diagnosis of MC. Dermoscopy serves best as a rapid diagnostic aide in such situations. It is a non-invasive diagnostic tool which visualizes subtle clinical patterns of skin lesions and subsurface skin structures that are normally invisible to the naked eyes [3]. A 25 year female presented with asymptomatic, slow growing, skin colored solitary swelling over left upper eyelid since 2 months (Figure 1). There was no history of trauma. Differential diagnosis of sebaceous cyst, inflamed milia, giant MC, nodular basal cell carcinoma and trichilemmoma was made. Dermoscopy showed polylobular whitish structureless areas in the centre surrounded by elongated telangiectasias. Telangiectasias were in serpiginous and arborizing patterns which typically do not cross midline (Figure 2). Excision biopsy was done and histopathology showed pronounced infundibular hyperplasia and papillomatosis with central umbilication. Millions of virions that have proliferated in the cytoplasm of affected epithelial cells result in the characteristic intracytoplasmic bodies that compress the keratinocyte nucleus (Figure 3). The polylobular whitish structureless areas correlate

Figure 1: Single umbilicated skin colored nodule on the left upper eyelid.

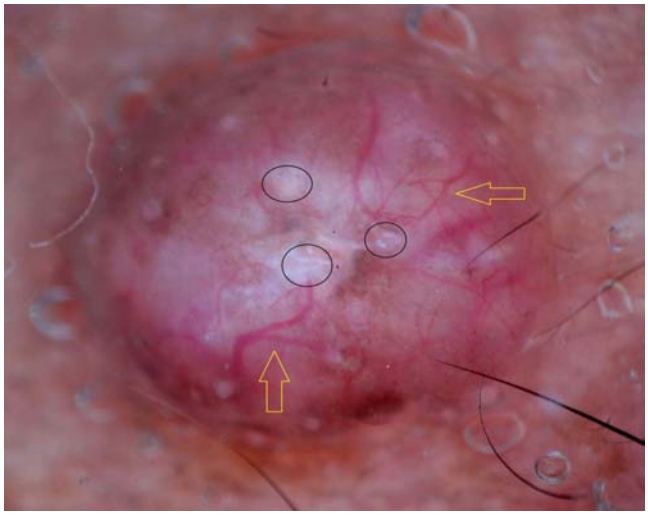

Figure 2: Dermoscopy shows polylobular white structureless areas (black circles) in the centre and serpiginous telangiectasias (yellow arrows) at the periphery.

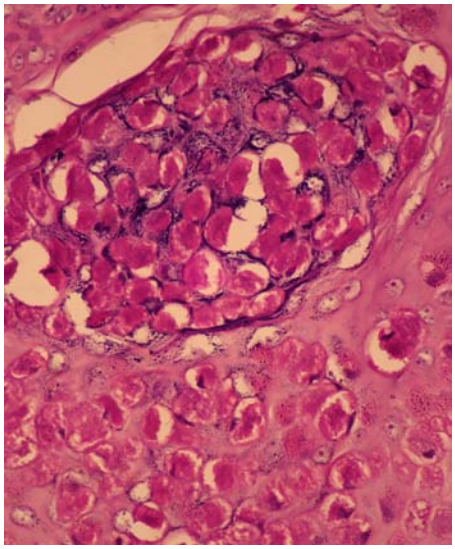

Figure 3: Histopathology shows characteristic intracytoplasmic bodies that compress the keratinocyte nucleus. (H& E, 40x).

Ankad et al. © All rights reserved

Citation: Mahajabeen M, Ankad BS, Alekhya R and Saipriya G. Dermoscopy in Molluscum Contagiosum: A Novel Diagnostic Aide. Austin J Dermatolog. 2016; 3(3): 1054.

histologically to hyperkeratosis, epidermal hyperplasia, and keratotic molluscum bodies; telangectasia correspond to dilated vessels. Hence, we conclude that dermoscopy plays important role in diagnosing complicated morphology of MC.

References

1. Brown J, Janniger CK, Schwartz RA, Silverberg NB. Childhood molluscum contagiosum. Int J Dermatol. 2006; 45: 93-99.
2. Ianhez M, Cestari Sda C, Enokihara MY, Seize MB. Dermoscopic patterns of molluscum contagiosum: a study of 211 lesions confirmed by histopathology. An Bras Dermatol. 2011; 86: 74-79.
3. Bowling J. Non-melanocytic lesions. Bowling J, editor. In: Diagnostic Dermoscopy - The Illustrated Guide. 1st edn. West Sussex: Wiley-Blackwell. 2012; 59-91.

Austin J Dermatolog - Volume 3 Issue 3 - 2016
ISSN : 2381-9197 | www.austinpublishinggroup.com
Ankad et al. © All rights reserved

Citation: Mahajabeen M, Ankad BS, Alekhya R and Saipriya G. Dermoscopy in Molluscum Contagiosum: A Novel Diagnostic Aide. Austin J Dermatolog. 2016; 3(3): 1054.