

Case Report

Sixth Nerve Palsy, Abducens Palsy

Peris ME^{1*}, Sas MTA² and Yarrin HA²¹MIR Family Physician, ABS4 Santa Coloma de Gramenet, Hospital Esperit Sant - ICS, Spain²Family Physician, ABS4 Santa Coloma de Gramenet, Institut Català de la Salut, Spain

*Corresponding author: M. Escofet Peris, MIR Family Physician, ABS4 Santa Coloma de Gramenet, Hospital Esperit Sant - ICS, Spain

Received: October 10, 2016; Accepted: November 09, 2016; Published: November 11, 2016

The Case

A 45-year-old female patient comes to the out-of-hours service of the Health centre with a 3-day history of binocular horizontal diplopia and holocraneal migraine. The patient has no history of trauma. Past medical history without relevance. The patient presents double vision producing a side-by-side image with both eyes open. In the physical exploration, diplopia to levo, supra and infraversion of his gaze is apparent. The rest of the neurological exploration was normal.

The Diagnosis

She was immediately referred to an ophthalmologist for examination. Ocular fundus examination and campimetry results were normal. There is a limitation of the abduction of the left eye. The patient is referred to Neurology; a cranial TAC is performed and results show no intracranial injuries. Upon analysis, all parameters are normal. The diagnostic orientation was idiopathic sixth nerve palsy.

Abduction limitations which mimic sixth nerve palsy may be a secondary effect of surgery, trauma or as a result of other conditions such as myasthenia gravis or thyroid eye disease. Other possible diagnosis: Mobius syndrome or Duane's syndrome [1-3].

Discussion

The sixth nerve has the longest subarachnoid course of all cranial

nerves and innervates the ipsilateral lateral rectus which abducts the eye. Lesions within each section are frequently recognizable by involvement of contiguous structures. Symptoms include binocular horizontal diplopia when looking to the side of the paretic eye (Figure 1).

Because the tonic action of the medial rectus muscle is unopposed, the eye is slightly adducted when the patient looks straight ahead. Diplopia is typically experienced by adults with sixth nerve palsies (Figure 2). The deviation is constant and is usually greater at distance fixation than at near, and also greater when the patient is looking toward the affected side.

All the patients with abducens nerve palsy need anophthalmologic examination: visual acuity, binocular function and stereopsis, motility evaluations and evaluation of ocular structures. In cases of sixth nerve palsy due to raised intracranial pressure, patients may experience headache.

General etiology (Etiology, Table 1): The most common causes of sixth nerve palsy in adults are vasculopathic (diabetes, hypertension, atherosclerosis), trauma and idiopathic. Less common increased intracranial pressure, giant cell arteritis, cavernous sinus mass, Glioblastoma, aneurysm, metastasis, multiple sclerosis, vasculitis, Chiari Malformation and intracranial hypertension. If the abducens nerve palsy presents together with other ipsilateral cranial nerve palsies, etiology could be a lesion involving the meninges, superior orbital fissure or cavernous sinus. Presence of orbital signs or pulse synchronous tinnitus suggest arteriovenous fistula.

The prognosis depends on the etiology. Palsy caused by viral infection usually resolves completely, whereas palsy caused by trauma is associated with incomplete resolution. The maximum improvement occurs during the first six months.

There is an article of the Department of Ophthalmology (Mayo Clinic, Rochester, Minnesota, USA) about the associations of sixth nerve palsy. They identified 137 new cases of sixth nerve palsy. Causes

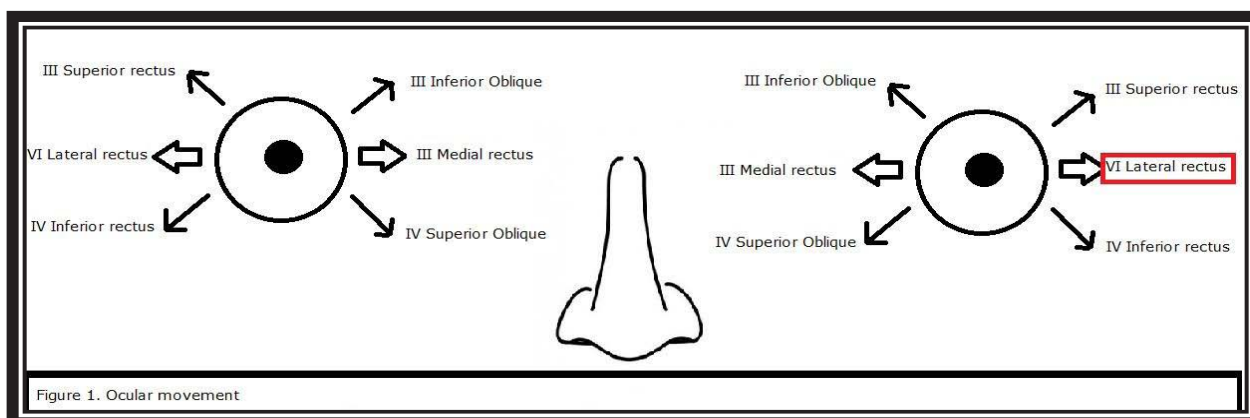


Figure 1: Ocular movement.

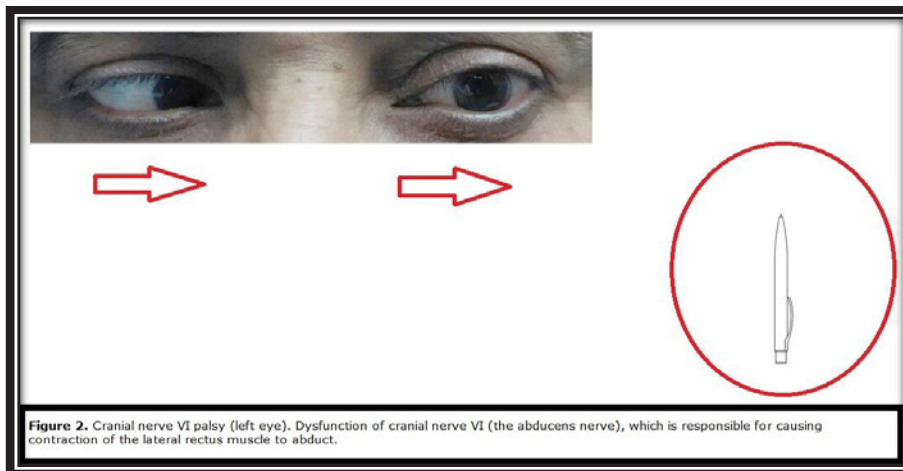


Figure 2. Cranial nerve VI palsy (left eye). Dysfunction of cranial nerve VI (the abducens nerve), which is responsible for causing contraction of the lateral rectus muscle to abduct.

Figure 2: Cranial nerve VI palsy (left eye). Dysfunction of cranial nerve VI (the abducens nerve), which is responsible for causing contraction of the lateral rectus muscle to abduct.

Table 1: Etiology: sixth nerve palsy.

Vasculopathy: Diabetes, Hypertension
Trauma
Multiple sclerosis
Neoplasm
Ischemic: Cerebrovascular accident
Aneurysm
Idiopathic

and associations were: undetermined (26%), hypertension alone (19%), coexistent hypertension and diabetes (12%), cerebrovascular accident (4%), post-neurosurgery (3%), aneurysm (2%) and other (8%).

Treatment depends on etiology: systemic conditions are treated primarily. Most patients with microvascular abducens nerve palsy are simply observed and usually recover within 3-6 months. There can be used occlusion to improve diplopia, torticollis and headache. Surgical intervention is only reserved for patients that had no improved in 3-6 months of conservative management. Botulinum toxin can be considered too.

The Takeaway

The sixth cranial nerve innervates extraocular muscle (ipsilateral lateral rectus) that action is abduction of the eye. The most common symptom of the sixth nerve palsy is diplopia. There is usually less double vision on near fixation than on distant fixation. It can be caused by diabetes, hypertension, atherosclerosis, trauma and idiopathic. All the patients with abducens nerve palsy need neurological evaluation and ophthalmologic examination.

References

1. The Six Syndromes of the Sixth Cranial Nerve. Mohsen Azarmina, MD1 and Hossein Azarmina, MD2.
2. Shrader EC, Schlezinger NS Neuro-ophthalmologic evaluation of abducens nerve paralysis. Arch Ophthalmol. 1960; 63: 84–91.
3. Rucker JC. Cranial neuropathies. In: Daroff RB, Fenichel GM, Jankovic J, Mazziotta JC, eds. Bradley's Neurology in Clinical Practice. 6th ed. Philadelphia, PA: Elsevier Saunders; 2012: chap 70.