

Special Article – Pediatric Healthcare

An Infant with Erythema Multiform: A Case Report

Gharib B, Memarian S, Saidi M, Mohsenipour R, Gorji M, Monajemzadeh M, Moradi L and Parvaneh N*

Children's Medical Center, Tehran University of Medical Sciences, Tehran, Iran

*Corresponding author: Nima Parvaneh, Children's Medical Center, Tehran University of Medical Sciences, Tehran, Iran

Received: December 15, 2017; Accepted: January 05, 2018; Published: January 12, 2018

Abstract

Erythema Multiform (EM) is a rare disease in infancy. We present an infant with EM who was first considered to have immunodeficiency or a serious infectious disease because of the strange appearance of the cutaneous lesions at presentation. Erythema multiform (EM) is a muco-cutaneous hypersensitivity reaction that appears acutely but is self-limiting, and it is triggered by infections, drugs, immune conditions and food additives. Twenty percent of EM cases happen in children. It is important for the clinicians to be familiar with the presentation of this disease to avoid unnecessary work-ups and mismanagement.

Keywords: Erythema Multiform; Hypersensitivity reaction; Papulovesicular lesions

Introduction

Erythema multiform (EM) is a mucocutaneous hypersensitivity reaction that appears acutely but is self-limiting, and it is triggered by infections, drugs, immune conditions and food additives. 20 percent of EM cases happen in children [1]. Herpes simplex virus (HSV) is the most common etiology of EM and HSV infection is the trigger of almost all of the recurrent EM cases which is frequently associated with sun exposure [2].

EM is presented as target-like lesions, distributed acrally, sometimes with oral, genital, mucosal and eye lesions. If mucosal tissues are involved, it is called EM major, and in EM minor, no mucosal involvement is seen [3]. The common presentation of the disease with the other prevalent illnesses make the diagnosis difficult for the clinicians and misdiagnosis and mismanagement (as happened in this case) may happen if they are not familiar with EM.

Case Presentation

A 75- day-old boy was brought to the emergency clinic, presented with bullous lesions in face (Figure 1), papules and erythema on genitalia (Figure 2), and bullae and aphthous like lesions in the lips (Figure 1). The mucosa of eyes was not involved.

The lesions appeared about 10 days ago as papulovesicular rash, firstly on face and then on the back of the hands, the lesions changed to bulla gradually and enlarged, the base of the lesions changed to red-purple color in a few days, the bulls' roof ruptured and a scar with well-defined edge, hemorrhagic base and necrotic center remained (Figure 1), he also had popular lesions on the back of the hands (Figure 3).

He had had occasionally low grade fever in the recent days, but he didn't have poor feeding or lethargy. About one week before of having the skin lesions, he had mild upper viral respiratory symptoms such as, mild fever, runny nose and coryza and received amoxicillin and diphenhydramine. His last vaccination was at birth time which he had received Hepatitis B, oral Poliomyelitis, and BCG (Bacille Calmette-Guerin).

In the previous medical visits, he had received cephalexin, with the impression of impetigo, without any improvement. Tzanksmear,

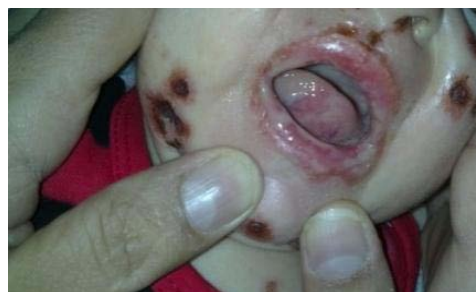

Figure 1: Facial lesions with a well-defined edge, hemorrhagic base and necrotic center.

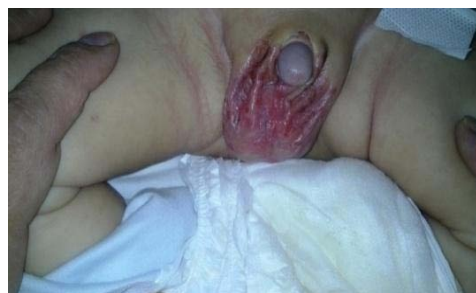

Figure 2: Papules and erythema on genitalia.

HSV Antigen 1 and 2 test of the lesion, and VDRL test were negative. Erythrocyte sediment rate was 15mm/hour and white blood cells were 12200/milliliter, with lymphocyte predominance.

In the first assessment in CMC, he wasn't ill-appeared but was restless. Vital signs were as follows: respiratory rate=40 breaths per minute, pulse rate=142 beats per minute, and temperature=36.7 centigrade degrees. The anthropometric measures were on the 50th percentile. He was transferred to the Immunology ward. The liver and kidney function tests, coagulation assessment, blood and urine cultures reported normal. Immunoglobulins levels, NBT, flow-cytometry of CD markers (CD3, CD16-56, CD19, CD20, CD4, and CD8) have also been assessed and were normal. Blood and urine bacterial and fungal cultures were negative for infections. C-reactive

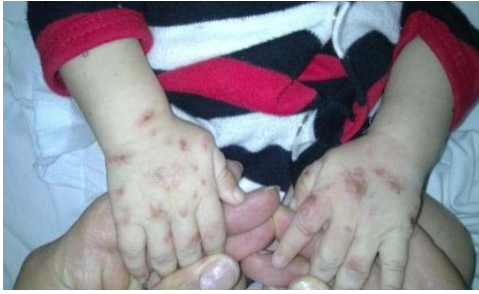

Figure 3: Popular lesions on the back of his hands.

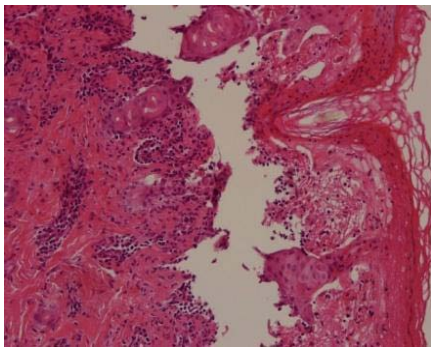


Figure 4: Erythema multiforme, with high density of necrotic tissues that can be suggestive of some degree of Toxic Epidermal Necrolysis (TEN) and without any viral inclusions.

protein (CRP) was 5.2 milligram per liter (mg/l) (reference range up to 6mg/l) and erythrocyte sediment rate (ESR) was 15 milliliter per hour (ml/h) (reference range up to 10ml/h). The complete blood cells test reported as follows: white blood cells=14630/milliliter, neutrophil=22.7%, lymphocyte=68.5%, hemoglobin=9.7 gram per deciliter, platelet=522000/milliliter.

During the hospitalization period (about 17 days after beginning of the illness) the popular lesions of the hand changed to vesicles and ruptured and crusted papules remained and healed gradually. He had also afflicted by oral candida lesions of mouth that treated by local nystatin.

Dermatologist consultants suggested a range of differential diagnosis from bullous viral infectious lesions (Echovirus, Coxsackievirus, and varicella), erythema multiforme following previous viral disease, idiopathic, autoimmune bullous disease, congenital bullous lupus and leukocytoclastic vasculitis and recommended to perform a skin biopsy, starting acyclovir for varicella, assessing lupus serology and antiphospholipid antibody in blood. Only the antiphospholipid antibody serology (IgM and IgG) was checked and reported normal.

Skin biopsy was performed (Figure 4) and the result was Erythema Multiforme, with high density of necrotic tissues that can be suggestive of some degree of Toxic Epidermal Necrolysis (TEN) and without any viral inclusions.

Discussion

The initial lesion of erythema multiforme usually appears as round, erythematous plaques with edema that are similar to insect

bites or popular urticaria [3]. The skin lesions are most common between the ages of 10 and 40-year-old. Cutaneous eruption is usually asymptomatic but sometimes a burning sensation or itching is present. Symmetric skin lesion most common on the extensor surface of the upper limbs with abrupt onset is characteristic. Skin eruptions are relatively scant on the legs, trunks and face. Palms and soles can also be involved. The initial lesion often appears as red macules or urticarial plaques [2]. Lesions in mouth are often erythematous macules on the lips and oral mucosa that change to epithelial necrosis, bullae, ulceration and maybe with bloody encrustation on the lips [1]. Oral lesion more commonly occur on the buccal mucosa and vermilion border of the lips. Skin eruptions often resolve in about 2 weeks without sequelae. EM doesn't progress to Steven Johnson Syndrome [2].

Rarely, involvement of mucosal membrane without cutaneous lesion occurs. Oral mucosa is the most common involved mucosal membrane [3].

Prodromal symptoms such as malaise, fever and myalgia are not prominent in most cases of EM, but may occur a week or more before the onset of EM and are common in EM with mucosal involvement [3].

Some of the causes of EM include: HSV, mycoplasma pneumonia, non steroid anti-inflammatory agents (NSAIDs), sulfonamides, antiepileptics, and antibiotics. Recurrent EM causes are; HSV, mycoplasma pneumonia, hepatitis C virus, vulvovaginal candidiasis, complex aphthous, polymorphous light eruption, menstruation and benzoic acid (food additive) digestion, and causes of continuous episodes of EM include; HSV, Epstein-Barr virus, influenza virus, inflammatory bowel disease and malignancy [3].

Mycoplasma pneumonia infection can present with several skin manifestations such as exanthematous skin eruption, erythema nodosum, urticaria, Stevens-Johnson syndrome (SJS), Bullous EM, Thrombotic Thrombocytopenic Purpura, Kawasaki disease and Urticarial vasculitis [4].

The mechanism of EM is partly due to type 4 hypersensitivity immune response, which is mediated through T cell lymphocytes [5].

EM is very rare in infancy. In a case report, a male preterm neonate, born at 35 weeks and 6 days of gestational age, afflicted by several annular, erythematous patches with target lesion, figure over the body at the 36th day of age (corrected age was 7th day), and BCG and Hepatitis B vaccination were the only known triggering factors and was treated with intravenous methyl prednisolone [6].

EM has a wide range of differential diagnosis like: Stevens-Johnson syndrome, Sweet's syndrome, urticaria, bullous pemphigoid, paraneoplastic pemphigus, Rowell's syndrome (cutaneous lupus erythematous), cutaneous small vessel vasculitis and polymorphous light eruption [3]. It has also been reported as a rare cutaneous presentation of incomplete Kawasaki disease [7], following HPV vaccination [8], following HBV vaccination [9], after ethanol ingestion [10], after urinary tract infection with candida albicans infection in a preterm neonate [11], and due to parainfluenza virus in a newborn [12].

Diagnosis of EM is often clinical and cutaneous biopsy can

confirm the diagnosis [9].

Topical steroids in EM minor may be helpful and the administration of systemic corticosteroids in EM major is controversial [5]. Symptomatic comfort may be provided by administration of systemic antihistamine, topical emollients or NSAIDs, but the course of the disease is not changed. The pain of severe mucosal disease can be controlled by opioids [2]. In case of recurrent HSV-associated EM, antiviral prophylaxis is required [3]. EM after vaccination is not a contraindication for the subsequent vaccination [9].

In the case presented here, the first impression of the emergency doctors were serious skin infection and immune deficiency, a thorough viral and infectious investigation was not made, as the patient's general condition was fair and the lesion were not active or oozing. The immunologist consultant suggested EM. EM is very rare in infancy, so other diagnosis should always be kept in mind and assessed for.

Infectious disease (in this case viral upper respiratory one) and the medication (amoxicillin) he had received could be responsible for this case of EM. However it could have a frightening appearance the course is usually self limited and benign. Our patient didn't receive any medication other than cutaneous emollients, wound care and nystatin for oral thrush.

References

1. Kamala KA, Ashok L, Annigeri RG. Herpes associated erythema multiforme. *Contemporary Clinical Dentistry*. 2011; 2: 372-375.
2. Joel C. Joyce. Erythema Multiforme. In: Robert M. Kliegman, Bonita F. Stanton, Joseph W. St. Geme III, Nina F. Schor, Richard E. Behrman, et al, editors. *Nelson Textbook of Pediatrics*, 20th Edition. Philadelphia, United States of America: Saunders; 2016: 3141-3142.
3. O Sokumbi, and DA Wetter. Clinical features, diagnosis, and treatment of erythemamultiforme: a review for the practicing dermatologist. *International Journal of Dermatology*. 2012; 51: 889–902.
4. Shimizu M, Hamaguchi Y, Matsushita T, Sakakibara Y, Yachie A. Sequentially appearing erythema nodosum, erythema multiforme and Henoch-Schönleinpurpura in a patient with *Mycoplasma pneumoniae* infection: a case report. *Journal of Medical Case Reports*. 2012; 6: 398.
5. Chan M, Goldman RD. Erythema multiforme in children. The steroid debate. *Canadian Family Physician Le Médecin de famillecanadien*. 2013; 59: 635-636.
6. Cho YJ, Huh SY, Hong JS, Jung JY, Suh DH. Neonatal Erythema Multiforme: A Case Report. *Ann Dermatol*. 2011; 23: 382-385.
7. Vierucci F, Tuoni C, Moscuza F, Saggese G, Consolini R. Erythema multiforme as first sign of incomplete Kawasaki disease. *Italian Journal of Pediatrics*. 2013; 39: 11.
8. Pérez-Carmona L, Aguayo-Leiva I, González-García C, Jaén-Olasolo P. The Quadrivalent Human Papillomavirus Vaccine: Erythema Multiforme and Cutaneous Side Effects after Administration. *Dermatology*. 2010; 221: 197–200.
9. Tan ZH, Thoon KC, Koh MJ. Case Series of Three Infants with ErythemaMultiforme Following Hepatitis B Vaccination. Tan ZH, et al. Case Series of Three Infants with Erythema Multiforme Following Hepatitis B Vaccination. *Pediatrics and Neonatology*. 2016; 57: 72-75.
10. Kohli PS, Kaur J. Erythema Multiforme-Oral Variant: Case Report and Review of Literature. *Indian J Otolaryngol Head Neck Surg*. 2011; 63: S9–S12.
11. Shilpa K, Pradeep S, Umesh V. Erythema Multiforme, a rare presentation of neonatal fungal UTI. *Pediatric oncall journal*. 2015; 4: 288-289.
12. Kahvecioglu D, Erdeve O, Atasay B, Yildiz D. Erythema multiforme due to parainfluenza virus in a newborn: A case report and review of the literature. *Indian J Paediatr Dermatol*. 2014; 15: 117-119.