Austin Journal of Nephrology and Hypertension

Open Access

Austin Publishing Group

Special Article - Chronic Kidney Disease

Major Kidney Trauma and Conservative Management: Case Report and Follow Up

Diaz B, Fernández-Pello S*, Baldissera JV, Blanco R, Pérez C, Rúger L and Mosquera J

Department of Urology, Hospital de Cabueñes. Spain

***Corresponding author:** Sergio Fernández-Pello, Department of Urology, Hospital de Cabueñes. Spain, Email: spello84@hotmail.com

Received: December 22, 2014; **Accepted:** February 09, 2015; **Published:** February 11, 2015

Abstract

Introduction: About 10% of all patients with trauma have urogenital injuries; half of them are caused by blunt trauma and involve the kidney. The treatment of renal trauma is still controversial, but conservative management is increasingly accepted as the preferred approach to most renal injuries.

Patients and Methods: Here we present two cases of young men with different types of major renal injuries, with conservative management and their follow up.

Discussion / Conclusion: Both patients evolved favorably, one of them needed the placement of a ureteral stent and the other required blood transfusion.

The conservative treatment for major renal treatment is appropriate when the patient is thermodynamically stable, but a strict follow up is necessary to reduce the complications.

Keywords: Kidney; Renal trauma; Conservative management

Introduction

About 10% of all patients with trauma have urogenital injuries; half of them are caused by blunt trauma and involve the kidney. The kidney is the most commonly injured genitourinary organ in all ages, with the male-to-female ratio being 3:1. In the majority of cases, renal injuries are minor and self-limiting. During the past 20 years, advances in imaging and treatment strategies have increased the ability to achieve renal preservation, and decreased the need for surgical intervention. The treatment of renal trauma is still controversial, but conservative management is increasingly accepted as the preferred approach to most renal injuries. Renal injuries are classified by their mechanism as blunt or penetrating. In rural settings, 90-95% of renal injuries are comprised of blunt trauma injuries, where in urban settings 40% of renal injuries are comprised of penetrating injuries. The most commonly used system for classifying renal traumas is that proposed by the American Association for the Surgery of Trauma (AAST) (Table 1) and abdominal computed tomography (CT) or direct exploration is used to classify injuries [1].

Patients and Methods

Case 1

A 27 years old male patient is brought by emergency services after a motorcycle accident. On physical examination, there are abdominal pain, two incised wounds in right abdomen and haematuria. On arrival to the emergency department, the patient remained hemodynamically stable and laboratory parameters in the blood analysis within normal limits.

The CT scan showed multiple lacerations on right renal parenchyma with integrity of vascular pedicle and urinary tract. No urinary leakage was noticed. Likewise, there were perirenal and retroperitoneal haematoma with blood collections in the right posterior pararenal space.

With the result of the CT and the patient's clinically stable status, a conservative approach was decided on, with constant patient surveillance and repeated blood analysis in critical care. Oral intake started on the third day and bed rest recommended until the seventh day. In the following days the clinical response was positive, remaining a febrile, stable and with the pain under control.

After three days a control CT was ordered and the same images of renal parenchyma were observed, with intravenous contrast uptake and elimination. There was a urinary leakage noticed with contrast extravasation through the anterior perirenal space (Figure 1); corresponding to a Grade IV renal injury. For this reason, in order

Table 1: American Association for the Surgery of Trauma. Organ injury severity scale for the kidney.

Grade	Type	Description
I	Contusion Hematoma	Microscopic or gross hematuria, urologic studies normal. Subcapsular, noexpanding without parenchymal laceration
II	Hematoma Laceration	Nonexpanding perirenal hematoma confined to renal retroperitoneum <1 cm parenchymal depth of renal cortex without urinary extravasation
III	Laceration	>1 cm parenchymal depth of renal cortex without collecting system rupture or urinary extravasation
IV	Laceration Vascular	Parenchymal laceration extending through renal cortex, medulla, and collecting system Main renal artery or vein injury with contained hemorrhage
V	Laceration Vascular	Completely shattered kidney Avulsion of renal hilum, devascularizing the kidney

Díaz et al. © All rights are reserved

Citation: Diaz B, Fernández-Pello S, Baldissera JV, Blanco R, Pérez C, Rúger L and Mosquera J. Major Kidney Trauma and Conservative Management: Case Report and Follow Up. Austin J Nephrol Hypertens. 2015;2(2): 1037.

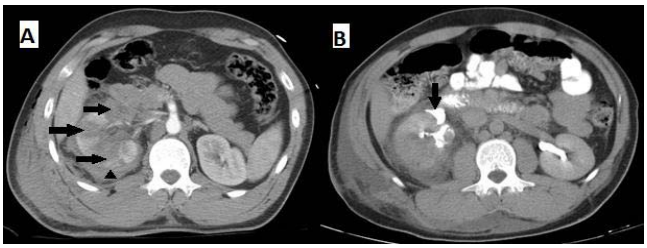

Figure 1: Case 1. A) CT scan accomplished after the trauma. Contrast-enhanced nephrographic-phase helical CT scan shows several deep lacerations of the interpolar region of the right kidney (arrows) and perinephric hematoma (arrowhead).
B) CT scan performed three days after trauma. Contrast-enhanced excretory-phase CT scan shows extravasation of contrast in the kidney Upper Right (arrow).

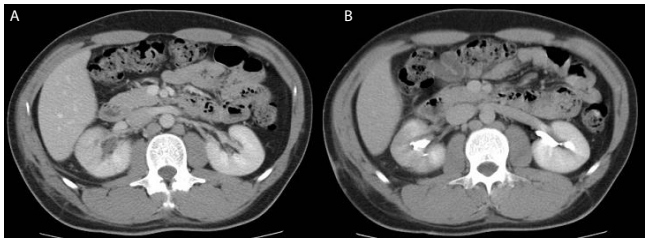

Figure 2: Case 1. CT scan obtained 2 months after renal injury. A) Contrast-enhanced nephrographic-phase helical CT scan shows good uptake of right renal parenchyma. The renal laceration has disappeared.
B) Contrast-enhanced excretory-phase CT scan shows good excretion of the right kidney. No contrast extravasation.

to minimize the observed urinoma and to promote healing of urinary tract, a right ureteral stent placement was recommended.

After nine days the patient was uneventfully discharged, during his admission the patient required six days of total repose, antibiotics to prevent infection and analgesics to control the pain, with no requirement of blood transfusion. The ureteral stent was removed in forty days.

An abdominal CT was requested at two months, showing an almost complete recovery of renal parenchyma and disappearance of the laceration (Figure 2).

Case 2

A 16 years old boy arrived to emergency room with low-back pain and haematuria, he had received a blunt injury in the left side of the abdomen during a football match ten hours before.

Physical examination revealed low-back pain and haematuria. The CT scan showed perinephric hematoma, with complete renal laceration with integrity of vascular pedicle and urinary tract; it corresponded to a Grade IV renal injury (Figure 3).

The patient was hemodynamically stable, so conservative management was decided on, with continuous hemodynamic monitoring, serial analytical determination and strict bed rest in critical care.

Within the first forty eight hours, the hematocrit and the hemoglobin levels decreased, and as a consequence the patient received two units of packed red cell transfusions. A new CT scan was completed without any changes.

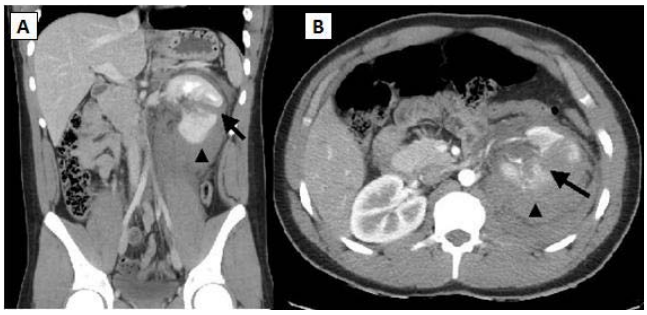

Figure 3: Case 2.CT scan performed immediately after the trauma. Contrast-enhanced nephrographic-phase helical CT scan shows a complete laceration of left renal parenchyma (arrows) and perirenal collection which corresponds to a hematoma (arrowheads).

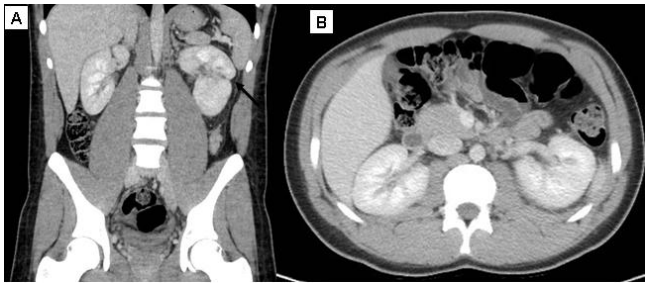

Figure 4: Case 2. Control contrast-enhanced helical CT scan performed 45 days after the renal injury. It has decreased renal laceration (arrow) and perirenal hematoma is gone.

Oral intake started at second day and the patient start walking at tenth day.

He was hemodynamically stable and the hemoglobin analysis within normal limits. Ten days after the trauma another CT was accomplished, the hematoma had decreased and the laceration was similar to the previous one. During the admission, the patient developed an hematogenous infection, possibly related to the venous catheter, produced by Acinetobacter baumannii and Candida parapsilosis, so he was treated for twenty days with Imipenem and Anidulafungin and was discharged on the 21st day.

The follow up CT scan was performed 45 days after the renal injury and it showed decrease in size of the left perirenal hematoma and an improvement of the renal laceration previously described (Figure 4). Renal function, in terms of serum creatinine, within normal limits.

Discussion

Renal injuries occur in 1 to 10 % of trauma patients, the 90-95 % of them is caused to blunt trauma, most often incurred in motor vehicles accidents, but another cause is a direct blow to the flank or abdomen during sports activities [1].

Haematuria following flank trauma is the leading symptom in all patients [2]. In our two cases both patients have gross haematuria and low-back pain.

The treatment of renal trauma has been discussed in the literature, but conservative treatment is increasingly accepted as the preferred approach to most blunt renal injuries; the treatment of penetrating and high-grade blunt injuries is more controversial [3,4,5]. Renal

Table 2: Patients data.

	CASE 1	CASE 2
SYMPTOMS	HAEMATURIA + PAIN	HAEMATURIA + PAIN
TYPE OF TRAUMA	PENETRATING	BLUNT
GRADE OF TRAUMA	IV	IV
URINARY LEAKAGE	YES	NO
URETERAL STENT	YES	NO
DAYS OF HOSPITALIZATION	9	21
BLOOD TRANSFUSION	NO	YES
DAYS OF BED REST	6	10
RENAL FUNCTION (Creatinine) 1st DAY	1.38 mg/dl	0.8 mg/dl
RENAL FUNCTION (Creatinine) AFTER 1 MONTH	1.14 mg/dl	1 mg/dl
ANTIBIOTICS	CEFUROXIME	ANIDULAFUNGIN + IMIPENEM
DAYS OF ANTIBIOTIC TREATMENT	10 (Prophylaxis)	20

exploration is necessary in only 2% of blunt injuries and in 57% of penetrating injuries [6].

There are several classifications of renal injury but the most widespread is the proposal by the American Association for the Surgery of Trauma's Organ Injury Scaling Committee [7] (Table 1).

Major renal injuries correspond to lesions grade IV and V, they often require surgery but even these injuries could be treated without surgery. The only absolute indications for surgical exploration are life-threatening renal bleeding with associated instability; expanding, pulsatile, or uncontained retroperitoneal hematoma; and complete ureteropelvic junction–ureteral avulsion [2,6,8].

Conservative treatment consisted in bed rest, analgesia, hydration, broad spectrum antibiotics in the presence of urinoma; follow up with continuous hemodynamic monitoring and serial hematocrit determination. The placement of a ureteral catheter prevents the formation of urinoma [2,9]. A Close follow up is necessary to determine the early and late complications such as hypertension [2,10].

Our patients had grade IV injuries, a blunt renal trauma and a penetrating renal trauma and both were treated with conservative management, one of them required the placement of a ureteral catheter to reduce the urinoma and the other needed blood transfusion, this patient had fever secondary to hematogenous infection associated with the venous catheter so he required antibiotics as well (Table 2). In our cases, no patient had renal abscess or infected hematoma. There were no late complications like hypertension.

Conclusion

The conservative treatment for major renal trauma is appropriated when the patient is hemodynamically stable and the CT image does not demonstrate hilium or ureteropelvic avulsion but it is necessary a strict follow up to reduce early and late complications.

References

1. Serafetinides E, Kitrey ND, Djakovic N, Kuehhas FE, Lumen N, Sharma DM, et al. A Review of the Current Management of Upper Urinary Tract Injuries by the EAU Trauma Guidelines Panel. Eur Urol. 2015 .
2. Dinkel HP, Danuser H, Triller J. Blunt renal trauma: minimally invasive management with microcatheter embolization experience in nine patients. Radiology. 2002; 223: 723-730.
3. Danuser H, Wille S, Zöscher G, Studer U. How to treat blunt kidney ruptures: primary open surgery or conservative treatment with deferred surgery when necessary? Eur Urol. 2001; 39: 9-14.
4. Gourgiotis S, Germanos S, Dimopoulos N, Vougas V, Anastasiou T, Baratsis S. Renal injury: 5-year experience and literature review. Urol Int. 2006; 77: 97-103.
5. Prasad NH, Devraj R, Chandriah GR, Sagar SV, Reddy ChR, Murthy PV. Predictors of nephrectomy in high grade blunt renal trauma patients treated primarily with conservative intent. Indian J Urol. 2014; 30: 158-160.
6. Metro MJ, McAninch JW. Surgical exploration of the injured kidney: current indications and techniques. Int Braz J Urol. 2003; 29: 98-105.
7. Moore EE, Shackford SR, Pachter HL, McAninch JW, Browner BD, Champion HR, et al. Organ injury scaling: spleen, liver, and kidney. J Trauma. 1989; 29: 1664-1666.
8. Caballero Romeu JP, Megías Garrigós J, Leivar Tamayo A, Galiano Baena JF, Pérez Tomás C, Herrero Polo E. Stab wounds of the kidney: conservative management. Two new cases and review of the literature. Actas Urol Esp. 2009; 33 :830-834.
9. Delgado Oliva FJ, Bonillo García MA, Gómez Pérez L, Oliver Amorós F, Gimeno Argente V, Jiménez Cruz JF . Conservative approach in major renal trauma. Actas Urol Esp. 2007; 31: 132-139.
10. Deepak J, Khanday ZS, Bagdi RK, Balagopal S, Agarwal P, Madhu R, et al. Three cases of blunt renal trauma in children. Sri ramachandra. 2007; 62.

Austin J Nephrol Hypertens - Volume 2 Issue 2 - 2015
ISSN : 2381-8964 | www.austinpublishinggroup.com
Díaz et al. © All rights reserved

Citation: Diaz B, Fernández-Pello S, Baldissera JV, Blanco R, Pérez C, Rúger L and Mosquera J. Major Kidney Trauma and Conservative Management: Case Report and Follow Up. Austin J Nephrol Hypertens. 2015;2(2): 1037.