Austin Journal of Orthopedics & Rheumatology

Open Access

Austin Publishing Group

Case Report

A Widely Displaced Galeazzi Equivalent Lesion with Median Nerve Compromise

Athar MS[1]*, Galanopoulos1 I[1], Fogg Q[2] and Ashwood N[1]

[1]Department of Trauma and Orthopaedics, Queens Hospital, Burton-on-Trent, UK

[2]Laboratory of Human Anatomy, School of Life Sciences, University of Glasgow, UK

***Corresponding author:** M Sajjad Athar, Department of Trauma and Orthopaedics, Queen's Hospital, Burton-on-Trent, UK

Received: November 28, 2017; **Accepted:** January 31, 2018; **Published:** February 08, 2018

Abstract

We present the case of a 14-year-old patient with a right distal radial fracture accompanied by a severely displaced complete distal ulnar physeal separation and associated median nerve compromise. This injury is known as Galeazzi-equivalent lesion in children and is an extremely rare injury associated with growth arrest. Recognition of the lesion can be difficult but wide displacement may be associated with other significant injuries such as neurovascular compromise.

Prompt intervention reversed the neurological symptoms. At ten months after the operation, neither growth arrest nor loss of range of motion has occurred. A review of the literature identifies a number of important reasons that dictate prompt reduction when there is complete separation of the ulna physis mainly because of soft tissue interposition or capsule problems.

Keywords: Physeal ulna injury; Salter–Harris; Galeazzi-equivalent

Introduction

Physeal fractures account for about 18% of all fractures in children and are usually classified according to the Salter-Harris classification system. The majority of these injuries are type II in Salter–Harris classification. About 3.3% of all physeal injuries involve the distal ulna. In 11–50% of the cases, distal radius fractures are accompanied with fractures of the ulna [1].

Some Salter–Harris type I and II distal ulnar epiphyseal injuries have been reported as needing open reduction [2-5] due to either tendon interposition [3]. or a rupture in the capsule [4].

The Galeazzi fracture-dislocation is a well-known injury including fracture of the distal radial shaft and dislocation of the Distal Radioulnar Joint (DRUJ). It is rare in adults and even more uncommon in children. A variant of the classic injury, the Galeazzi-equivalent fracture, consists of a fracture at the distal radial metadiaphyseal area with complete distal ulnar epiphyseal separation instead of the more common pattern of DRUJ dislocation [6-7].

This is the first case noted to have neurological compromise within the literature requiring urgent treatment.

Case Presentation

A 14-year-old boy presented to the accident and emergency department after a fall on his right outstretched hand whilst playing handball. On examination the right wrist was swollen and deformed, with tenderness over the distal radius and ulna on palpation. The skin was intact and the elbow and proximal forearm were non-tender. There was reduced sensation over the area of the median nerve distribution but with no distal vascular compromise. Antero-posterior and lateral radiographs of the right wrist showed a dorsally displaced and rotated Salter–Harris type I fracture of the distal ulnar epiphysis with a dorsally displaced metaphyseal fracture of the distal radius (Figure 1). These findings suggested the so-called paediatric Galeazzi-equivalent fracture, which is very rare among this population.

Figure 1: Initial radiographs showing a distal radial fracture with complete distal ulnar epiphyseal separation with evidence of preservation of the DRUJ.

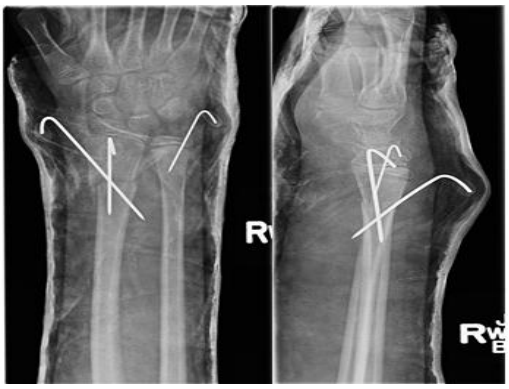

Figure 2: Post-operative radiographs with the arm immobilized in plaster.

Closed reduction was achieved under general anaesthesia and Kirschner wires were used to stabilise the fracture fragments (Figure 2). The first K-wire was inserted in the radius using the Kapandji technique and another K-wire was then inserted from the radial side

Citation: Athar MS, Galanopoulos I, Fogg Q and Ashwood N. Case Report: A Widely Displaced Galeazzi Equivalent Lesion with Median Nerve Compromise. Austin J Orthopade & Rheumatol. 2018; 5(1): 1063.

Figure 3: Radiographs after removal of K-wires show complete healing of fractures with excellent alignment in both anteroposterior and lateral views.

to offer more stability. Finally, the ulnar physeal fracture was fixed with one fine K-wire which was passed across the growth plate. An above-elbow cast was applied and left in place for 6 weeks to allow the fractures and the soft tissue injuries to heal.

Urgent reduction was necessary because of median nerve involvement and internal fixation using Kirschner wires also performed to maintain the mechanics of the distal radio-ulnar joint, and also to reduce the incidence of growth disturbance. The importance of the latter is related to the fact that 70–80% of the growth of the ulna is from the distal growth plate and epiphyseal injuries have been reported to cause growth disturbance in more than 50% of cases [2].

At follow-up ten months post surgery the mean active range of motion nearly equals to the contralateral wrist in flexion/extension, pronation/supination, and ulnar/radial deviation. There was also equivalent grip and pinch strength compared to the contralateral side and no evidence of median nerve disturbance. Radiographic evaluation did not show any signs of growth arrest at ten months (Figure 3) but continued radiographic assessment until skeletal maturity to monitor for possible growth disturbance of the Distal Ulnar Physis has been advised to both parents and the injured individual.

Discussion

The uncommon paediatric Galeazzi-equivalent injury usually involves an ulnar physeal fracture with distal radioulnar joint preservation rather than a soft tissue disruption through the distal radioulnar joint. Therefore, there is no rupture of the distal ligamentous stabilizing system between the radius and ulna, which includes the triangular fibrocartilage complex, interosseous ligaments and the ulnar periosteal tube.

In this paper we presented a completely displaced Salter–Harris type I injury of the distal ulna epiphysis accompanied by a displaced distal radial metadiaphyseal fracture, thus a Galeazzi-equivalent type of injury, which is extremely rare. The level of displacement may have contributed to the soft tissue injury and nerve compromise. Previous case illustrations have not shown such a wide displacement. There was nothing unique about the mechanism of injury, although the described cases occur around adolescence when the growth plate is starting to fuse and the forces required to shear the ulna growth plate off may lead to severe tissue disruption, hence the higher rate of open reduction and risk of nerve compromise.

It is also important to carefully assess distal radial-ulnar paediatric injuries when they occur, as they can lead to poor long-term results if misdiagnosed or maltreated. These traumatic lesions are misdiagnosed in around 41% of the cases. This can lead to growth plate problems and may result in instability, functional loss of range of motion, loss of strength and occasionally cosmetically poor outcomes [8,9].

Physeal growth arrest is frequent with distal ulnar physeal fractures occurring in 21% to 55%. Cannata et al., [10] showed in a large series of patients with distal ulnar physeal injuries treated with manipulation under anaesthesia and plaster, that growth disturbances occurred regardless of the classification type. However, all patients were fully asymptomatic at long-term follow-up, except for those who had forearm bone growth discrepancy of more than 1 cm.

Despite anatomical reduction and stable fixation of the fracture, premature partial fusion of the distal ulnar physis might still occur especially in younger patients and so follow up until skeletal maturity is advisable.

Emergent closed reduction and internal fixation is suggested as the treatment of choice for a displaced Salter–Harris type I fracture of the distal ulna to avoid nerve compromise in the short term. Accurate reduction is required to prevent growth disturbances and distal radio-ulnar joint malfunction in the long term. Occasionally, closed reduction cannot be achieved because of soft tissue interposition and in these cases an open reduction is required [9,11].

In this case, we considered the Kapandji technique as a safe and effective method of K-wire fixation with all the advantages of a minimally invasive procedure, although it has not been described as a means of fixation in a paediatric Galeazzi-equivalent injury.

References

1. Peterson HA. Epiphyseal growth plate fractures. Springer, Berlin. 2007.
2. Golz RJ, Grogan DP, Greene TL, Belsole RJ, Ogden JA. Distal ulnar physeal injury. J Pediatr Orthop. 1991; 11: 318–326.
3. Evans DL, Stauber M, Frykman GK. Irreducible epiphyseal plate fracture of the distal ulna due to interposition of the extensor carpi ulnaris tendon. Clin Orthop Relat Res. 1990; 251: 162–165.
4. Engber WD, Keene JS. Irreducible fracture separation of the distal ulnar epiphysis. J Bone Joint Surg Am. 1985; 67: 1130–1132.
5. Mizuta T, Benson WM, Foster BK, Paterson DC, Morris LL. Statistical analysis of physeal injuries. J Paediatr Orthop. 1987; 7: 518–523.
6. Abid A, Accadbled F, Kany J, de Gauzy JS, Darodes P, Cahuzac JP. Ulnar styloid fracture in children: a retrospective study of 46 cases. J Pediatr Orthop B. 2008; 17: 15-19.
7. Bley L, Seitz WH. Jr. Injuries about the distal ulna in children. Hand Clin. 1998; 14: 231-237.
8. Walsh HP, McLaren CA, Owen R. Galeazzi fractures in children. J Bone Joint Surg (Br). 1987; 69: 730-733.
9. Waters PM, Bae DS, Montgomery KD. Surgical management of posttraumatic distal radial growth arrest in adolescents. J Pediatr Orthop. 2002; 22: 717–724.
10. Cannata G, De Maio F, Mancini F, Ippolito E. Physeal fractures of the distal radius and ulna: long-term prognosis. J Orthop Trauma. 2003; 17: 179-180.
11. Yukihiro F, Makoto S, Ikuhumi N, Tatsuo M, Tatsuya M, Takanori S, et al. A case of Galeazzi-equivalent lesion. Orthop and Traumatol. 2006; 55: 368-371.