Austin Journal of Otolaryngology

Open Access

Austin Publishing Group

Case Report

Thyroid Isthmus Agenesis Diagnosed During Total Laryngectomy

Ismi O[1], Vayisoglu Y[1]*, Ozcan C[1], Erdogan O[1], Gen R[2] and Gorur K[1]

[1]Department of Otorhinolaryngology, University of Mersin, Turkey

[2]Department of Endocrinology and Metabolism, University of Mersin, Turkey

***Corresponding author:** Yusuf Vayisoglu, Department of Otorhinolaryngology, University of Mersin, Kulak Burun Boğaz A.D Çiftlikköy Kampüsü, Çiftlikköy/ Yenişehir-Mersin, Turkey

Received: November 10, 2015; **Accepted:** December 22, 2015; **Published:** December 28, 2015

Abstract

Although thyroid gland is a well-known endocrine organ both surgically and medically; it has multiple congenital anomalies seen from rare to common. Various anomalies reported and of these anomalies thyroid isthmus agenesis is very rarely seen. In this article we presented a case of thyroid isthmus agenesis diagnosed during surgery for a total laryngectomy in 52 years of male patient. We discussed the case with associated current literature emphasizing importance of knowing anomalies preoperatively to avoid complications during thyroid surgery.

Introduction

Thyroid gland is the endocrine organ responsible for production of thyroid hormones located in the lower neck between fifth cervical to first thoracic vertebrae ensheathed by pretracheal layer of deep cervical fascia. It has right and left lobes connected by a narrow median isthmus [1]. In 50 percent of cases thyroid gland has a pyramidal lobe extending from isthmus superiorly [2].

Wide spectrum of congenital anomalies and anatomic variations can occur regarding thyroid gland. Common anomalies include thyroglossal ductus cyst and persistent pyramidal lobe and rare anomalies such as agenesis, hemiagenesis of thyroid gland, aberrant thyroid glands can also be seen [3]. Of these anomalies the incidence of agenesis of isthmus (AGEIS) rare and very few cases have been reported. We presented the first case of AGEIS diagnosed during total laryngectomy for surgical treatment of laryngeal cancer in a 52 years old male patient.

Case Presentation

Squamous cell carcinoma of larynx was diagnosed in a 52 years old male patient. Tumor was transglottic with a subglottic extension of nearly 1,5 cm. He had no history of thyroid gland diseases. Preoperative thyroid hormone levels were in normal limits. During surgery for total laryngectomy; when strap muscles were retracted to skeletonize larynx, thyroid gland was seen. The thyroid gland had separate right and left lobes without interconnecting isthmus (Figure 1). Pyramidal lobe was not seen. There were no palpable nodules in thyroid lobes or nearby ectopic thyroid tissue. Total laryngectomy was done without complication and postoperative period was uneventful. Patient was discharged from hospital on postoperative eleventh day.

Discussion

Thyroid gland has left and right lobes connected by midline isthmus. Each lobe is approximately 5 cm in long axis. Isthmus connects the lower part of lobes and is 1,25 cm long transversely and vertically located anterior to second and third tracheal cartilages. Surgical proximity of isthmus to vascular structures is important to avoid major complications during thyroid surgery. Superior thyroid arteries anastomose along its upper border and at its lower border inferior thyroid veins leave the gland [1,4]. Near surgical proximity; thyroid isthmus is also important for deciding the type of thyroid surgery. It is resected with one of the lobes for unilateral thyroid nodules (unilateral lobectomy with isthmusectomy), and thyroid isthmusectomy without lobectomy can be done for nodules confined to isthmus. Isthmus preserving total bilobectomy may be an alternative surgery for C-cell hyperplasia of thyroid gland [5].

During embryological development some anomalies of thyroid gland such as hypoplasia, ectopy, hemiagenesis and agenesis of the gland can occur [4]. Among these AGEIS can be rarely seen with an average incidence of 5-10% [6]. For some species birds, amphibians, many mammals have separate thyroid lobes without isthmus. In rhesus monkeys, thyroid glands are normal in position without an isthmus [7]. For human beings; embryologically thyroglossal ductus arises from the endodermic epithelium at level of second and third pharyngeal arch. During descending from foramen caecum, its caudal end bifurcates and gives origin to thyroid lobes and isthmus. Cephalic end of the duct degenerates. Rarely, a higher separation of the ductus can result in separate right and left lobes without interconnecting thyroid isthmus [3]. Since thyroid isthmus formation is a late stage during embryogenesis, an insult affecting development prior to, can cause AGEIS [7,8]. Although AGEIS can be alone, it can be with additional anomalies such as absence of either lobe or presence of ectopic thyroid tissue at nearby cervical region, can also be seen with levator glandula thyroidea [3]. AGEIS can also accompany some benign and malignant thyroid diseases such as nodular goiter, Graves basedow disease with solitary nodule, thyroid papillary carcinoma, thyroiditis, neoplastic metastases and amyloidosis deposition [1,4,9,10]. For our case; there was no an additional anomaly or diseases about thyroid gland. The only known disease was laryngeal cancer.

Diagnosis of AGEIS is difficult since most cases are euthyroid [9] like in our case. Most of the patients are diagnosed incidentally during evaluation of a thyroid disease [9]. There is no known

Vayisoglu et al. © All rights are reserved

Citation: Ismi O, Vayisoglu Y, Ozcan C, Erdogan O, Gen R and Gorur K. Thyroid Isthmus Agenesis Diagnosed During Total Laryngectomy. Austin J Otolaryngol. 2015; 2(9): 1066.

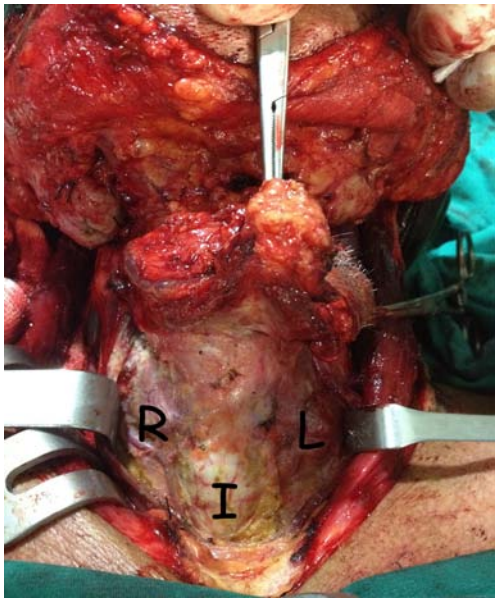

Figure 1: Thyroid isthmus agenesis during laryngectomy was shown. (R: Right Thyroid Lobe; L: Left Thyroid Lobe; I: Thyroid Isthmus Agenesis).

predisposing factor, but trisomy of chromosome 22 was supposed to be a possible related factor [11]. Diagnosis of AGEIS can be achieved by ultrasonography, computerized tomography, magnetic resonance imaging, and scintigraphy or during a thyroid related surgery [4] like in our case.

True incidence of AGEIS is hard to determine since most of the patients are euthyroid and most are diagnosed incidentally [9]. Although average incidence can be accepted as 5-10% [6] there are great variations among authors [2,7,12-15]. Braun et al. found a 6,8% incidence [12], whereas Dixit et al. found 14,6% [13] in cadaver studies. Marshall investigated thyroid anomalies in 60 children less than 10 years of age. AGEIS was detected in 10 % of cases [14]. Prakash et al. found 8,5 % of AGEIS in totally 70 cadavers [7]. Joshi et al. diagnosed a slightly higher percentage (16,6%) among 90 cadavers [15]. For Ranade et al. incidence was much higher (33%) comparing other authors [2]. AGEIS can also be seen with different percentages among different races. Among korean adults Won and Chung published a 3 % incidence [16] whereas Harjeet et al. found 7,9% incidence [17] among northwest Indians.

Head and neck surgeon dealing with thyroid gland must be aware of anomalies and variations to avoid serious complications such as recurrent laryngeal nerve and major vascular damage. Thyroid isthmus has proximity with superior thyroid arteries and inferior thyroid veins. Since most of the cases are diagnosed incidentally; thyroid isthmus agenesis must also be kept in mind during dissection to prevent hazardous complications.

References

1. Kumar GP, Satyanarayana N, Vishwakarma N, Guha R, Dutta AK, Sunitha P. Agenesis of isthmus of thyroid gland, its embryological basis and clinical significance--a case report. Nepal Med Coll J. 2010; 12: 272-274.
2. Ranade AV, Rai R, Pai MM, Nayak SR, Prakash, Krisnamurthy A, et al. Anatomical variations of the thyroid gland: possible surgical implications. Singapore Med J. 2008; 49: 831-834.
3. Devi Sankar K, SharmilaBanu P, Susan PJ, et al. Agenesis of isthmus of thyroid gland with bilateral levator glandulae thyroideae. IJAV. 2009; 2: 29-30.
4. Vayisoglu Y, Ozcan C, Gen R, Eti CM, Sut H, Gorur K. Thyroid isthmus agenesis associated with thyroid papillary carcinoma. [corrected]. J Craniofac Surg. 2013; 24: e428-429.
5. Won HS, Han SH, Oh CS, Chung IH, Won HJ, Kim JH. Location and morphometry of the thyroid isthmus in adult Korean cadavers. Anat Sci Int. 2013; 88: 212-216.
6. Pastor Vàzquez JF, Gil Verona JA, De Paz Fernàndez FJ. Agenesis of the thyroid isthmus. Eur J Anat. 2006; 10: 83-84.
7. Prakash, Rajini T, Ramachandran A, Savalgi GB, Venkata SP, Mokhasi V. Variations in the anatomy of the thyroid gland: clinical implications of a cadaver study. Anat Sci Int. 2012; 87: 45-49.
8. Hájovská K. Prenatal thyroid gland in sheep with regard to the presence of isthmus. Anat Histol Embryol. 2002; 31: 300-302.
9. Schanaider A, de Oliveira PJ Jr. Thyroid isthmus agenesis associated with solitary nodule: A case report. Cases J. 2008; 1: 211.
10. Ozkan OF, Asık M, Toman H, Ozkul F, Cıkman O, Karaayvaz M. Agenesis of isthmus of the thyroid gland in a patient with graves-basedow disease and a solitary nodule. Case Rep Surg. 2013; 2013: 608481.
11. Gangbo E, Lacombe D, Alberti EM, Taine L, Saura R, Carles D. Trisomy 22 with thyroid isthmus agenesis and absent gall bladder. Genet Couns. 2004; 15: 311-315.
12. Braun EM, Windisch G, Wolf G, Hausleitner L, Anderhuber F. The pyramidal lobe: clinical anatomy and its importance in thyroid surgery. Surg Radiol Anat. 2007; 29: 21-27.
13. Dixit D, Shilpa MB, Harsh MP, Ravishankar MV. Agenesis of isthmus of thyroid gland in adult human cadavers: a case series. Cases J. 2009; 2: 6640.
14. Marshall CF. Variations in the Form of the Thyroid Gland in Man. J Anat Physiol. 1895; 29: 234-239.
15. Joshi SD, Joshi SS, Daimi SR, Athavale SA. The thyroid gland and its variations: a cadaveric study. Folia Morphol (Warsz). 2010; 69: 47-50.
16. Won HS, Chung IH. Morphologic variations of the thyroid gland in Korean adults. Korean J PhysAntropol. 2002; 15: 119-125.
17. Harjeet A, Sahni D, Jit I, Aggarwal AK. Shape, measurements and weight of the thyroid gland in northwest Indians. Surg Radiol Anat. 2004; 26: 91-95.

Austin J Otolaryngol - Volume 2 Issue 9 - 2015
ISSN : 2473-0645 | www.austinpublishinggroup.com
Vayisoglu et al. © All rights reserved

Citation: Ismi O, Vayisoglu Y, Ozcan C, Erdogan O, Gen R and Gorur K. Thyroid Isthmus Agenesis Diagnosed During Total Laryngectomy. Austin J Otolaryngol. 2015; 2(9): 1066.