

## Special Article - Colorectal Surgery

## Resection of Colorectal Cancer

Elroy Patrick Weledji\*

Department of Surgery, Faculty of Health Sciences,  
University of Buea, Cameroon\*Corresponding author: Elroy Patrick Weledji,  
Department of Surgery, Faculty of Health Sciences,  
University of Buea, PO Box 126, Limbe, S.W. Region,  
Cameroon

Received: May 22, 2017; Accepted: July 04, 2017;

Published: July 11, 2017

## Abstract

The outcome of the surgical management of colorectal cancer is biologically predetermined by the presence or absence of occult metastases. The preoperative staging is the key to treatment decisions. However, the two diseases are biologically different and the rectal cancer patient requires in addition, a general assessment of the bulk of the tumour, the accessibility of the pelvis, the quality of the anus and the potential of improving tumour characteristics by the application of preoperative chemo-radiotherapy. Treatment is loco-regional control only but 'cure' is in addition the elimination of the putative micrometastases with adjuvant systemic chemotherapy. In rectal cancer surgery quality of life issues include preservation of continence, preservation of reasonable bowel frequency and avoidance as far as possible, of permanent sexual and urinary disturbance.

**Keywords:** Colorectal; Cancer; Resection; Locoregional; Lymphovascular; Mesorectum; Adjuvant Therapy

## Introduction

Colorectal cancer is a major health problem being one of the most prevalent malignancies in the Western world with the mean age of 60 years. The incidence is rising in younger individuals in the developing world due to adoption of the western diet and lifestyle [1]. Although the incidence is rising in younger individuals with more poorly differentiated and advanced tumours [2], colorectal carcinoma in individuals without genetic or disease-related risk factors is unusual before 45 years of age [1]. In 2002 in the UK there were approximately 35,000 new cases of which about 13,000 were rectal and 22,000 colonic [3]. The 5-year relative survival rate is currently about 50% and has improved over the last 30 years from 20% in 1971-75 [4]. This is because of better preoperative staging, perioperative management, multimodal therapy facilitated by the better understanding and application of surgical oncological principles [1,5]. Although the colon comprises the large bowel proximal to the rectum, the definition of the rectum is unclear. The UK definition is a tumour within 15cm of the anal verge on rigid sigmoidoscopy [6], where as authorities from the USA have preferred 11cm or 12cm [7,8]. Perhaps the simplest definition is the intraoperative identification of the fusion between the two antimesenteric taenia into an amorphous area where the true rectum begins which is roughly at the level of the third sacral vertebrae where the sigmoid mesocolon ends [9]. Although surgery is the only curative option for both colon and rectal cancer, these distinctions are important for two reasons. First, the diseases are different and carcinoma of the rectum presents a different challenge because of the narrow confines of the pelvis. The tight anatomical space both invites invasion into adjacent structures and limits the extent of circumferential dissection. Proximity to the anal orifice frequently mandates sphincter sacrifice and the creation of a permanent colostomy. In case of lymph node metastases, adjuvant chemotherapy is applied to both in order to increase the disease-free survival and five-year survival rate. In case of rectal cancer, if pathological lymph nodes and/or an involved meso-rectal fascia are present neo-adjuvant chemo-radiation is recommended [10,11]. Even at the cost of increased incidence of complications this reduces the incidence of local pelvic

recurrence with the unpleasant effects [10,11]. Adjuvant radiotherapy is not appropriate for colonic tumours due to the dose-limiting effects of the small bowel in the abdominal cavity, and the problems that can arise treating more mobile targets outside the pelvis. Secondly, comparisons between outcomes for colorectal cancer surgery are impossible unless uniform definitions are adopted. Longer-term survival in colorectal cancer patients is outside the control of the colorectal surgeon, being dependent on the presence or absence of occult hepatic metastases at the time of presentation. However, the surgeon can control (a) death in hospital, (b) local recurrence and (c) quality of life.

## Natural History and Implications on Surgical Resection

Within the colon, about 50% of cancers arise in the left side and 25% in the right probably due to the process of carcinogenesis completing on the left side and stasis. There is about a 3% chance of a synchronous cancer at the time of the original resection and, about 3% risk of a metachronous tumour although higher in cases where there is a family history. Thus, the importance of preoperative and surveillance colonoscopy after resection. The majority of colonic cancers arise from pre-existing adenomatous polyps and the incidence of colorectal cancer has been shown to fall with a long-term screening programme involving colonoscopy and polypectomy [12,13]. CT colography or 'virtual colonoscopy' effective in detecting polypoid lesions down to 6mm in diameter is replacing the barium enema as the radiological investigation of choice [14]. When invasion has taken place, colorectal cancer can spread directly and via the lymphatic, blood and transcoelomic route. Direct spread occurs longitudinally, transversely and radially, but as adequate proximal and distal clearance is technically feasible in the majority of colonic cancers, it is radial spread which is of most importance. In a retroperitoneal colonic cancer, radial spread may involve the ureter, duodenum and muscles of the posterior abdominal wall whereas the intraperitoneal tumour may involve small intestine, stomach, pelvic organs or the anterior abdominal wall. The lymphatic spread of colonic cancer progresses from the paracolic nodes along the main colonic vessels

**Table 1:** Dukes' staging (based on histological examination of the resection specimen).

<b>A</b>	<b>Invasive carcinoma not breaching the muscularis propria</b>
<b>B</b>	Invasive carcinoma breaching the muscularis propria, but not involving regional lymph nodes
<b>C1</b>	Invasive carcinoma involving regional lymph nodes (apical node negative)
<b>C2</b>	Invasive carcinoma involving regional lymph nodes (apical node positive)

**Table 2:** TNM staging.

<b>T</b>	<b>Primary tumour</b>
<b>TX</b>	<b>Primary tumour cannot be assessed</b>
<b>T0</b>	No evidence of primary tumour
<b>Tis</b>	Carcinoma in situ
<b>T1</b>	Tumour invades submucosa
<b>T2</b>	Tumour invades muscularis propria
<b>T3</b>	Tumour invades through muscularis propria into subserosa or into non-peritonealised pericolic or perirectal tissues
<b>T4</b>	Tumour perforates the visceral peritoneum or directly invades other organs or structures
<b>N</b>	Regional lymph nodes
<b>NX</b>	Regional lymph nodes cannot be assessed
<b>N0</b>	No regional lymph node metastasis
<b>N1</b>	Metastasis in 1-3 pericolic or perirectal lymph nodes
<b>N2</b>	Metastasis in 4 or more pericolic or perirectal lymph nodes
<b>N3</b>	Metastasis in any lymph node along the course of a named vascular trunk
<b>M</b>	Distant metastases
<b>M0</b>	No distant metastases
<b>M1</b>	Distant metastases

(Dukes C1 or N1/N2 on TNM staging) to the nodes associated with either cephalad or caudal vessels, eventually reaching the para-aortic glands in advanced disease (Duke's C2 or N3 on TNM staging) [15] (Table 1 and 2). This orderly process does not always occur. In 30% of cases nodal involvement can skip a tier of glands [16,17]. In contrast to rectal disease it is rare for a colonic cancer which has not breached the muscle wall (Dukes A) to exhibit lymph node metastases [18,19]. A well-differentiated tumour has about a 25% chance of having lymph node involvement whereas a poorly differentiated tumour has a greater than 50% chance. Thus a well differentiated tumour confined to the bowel wall (Dukes A) would have a low prospect of lymph node involvement and best prognosis [20,21]. Thus, the biology of the tumour is paramount at predicting prognosis and explains why after curative resection, the age-adjusted 5 year survival for Dukes' stage A colonic cancer is 85%, for stage B 67% and for stage C 37% (C1 40%, C2 26.5%) [15-17,20-22]. Because right-sided carcinomas do not often cause obstructive symptoms and bleed slowly, they are likely to be discovered at a later advanced stage when poorly-differentiated than carcinomas of the distal colon which are likely to cause symptoms and thus be found at an earlier stage. Despite this, the survival rate after surgical removal of right colon carcinoma was better than that after removal of left-sided tumours [22,23]. In rectal cancer, discontinuous spread into the mesorectum to form circumscribed nests of tumour occurs [24,25]. Histopathological examination of the rectum showed foci of adenocarcinoma often well distal to the lower border of the tumour [25]. The presence of this potential source of local recurrence has led to the doctrine that total mesorectal excision (TME) should accompany anterior resection of rectal cancer as a routine [24]. However, this manoeuvre cannot eradicate local recurrence completely (<5% recurrence rate) as it will not deal with metastatic nodes on the lateral pelvic wall which occur in 10% to 30% of cases [24,26]. The most common site for blood-borne spread of colorectal cancer is the liver, presumably arriving by the portal venous system. Up to 37% of patients may have synchronous liver metastases at time of operation [27]. The lung is the next most common site with about 10% of patients developing lung

metastases at some stage although with usually better biology than liver metastases [28]. Other reported sites include ovary, adrenal, bone, brain and kidney. Transcoelomic spread via the subperitoneal lymphatics or viable cells shed from the serosal surface of a tumour giving rise to malignant ascites is relatively rare.

## Elective versus Emergency Setting

### Elective

When the diagnosis has been made most usually from colonoscopic biopsy, multislice CT of the chest and abdomen is the staging modality of choice [13,22]. In rectal cancer, a general assessment of the bulk of the tumour, the accessibility of the pelvis, the quality of the anus and the potential of improving tumour characteristics by the application of preoperative radiotherapy are important [13,22]. Recognition of the importance of the colorectal margin (CRM) in predicting local recurrence of rectal cancer has led to pelvic magnetic resonance imaging (MRI) being a standard pre-operative technique for demonstrating the relationship of the tumour to the mesorectal fascia (the intended 'CRM' for a mesorectal excision) [29,30]. It allows informed decisions on those most likely to benefit from preoperative chemoradiotherapy (CRT) regimens to downsize the tumour and facilitate complete excision at subsequent surgery [11,31-33] or those males with anterior encroachment sufficient to warrant primary exenteration [34]. Given that a patient is fit for surgery, and does not have advanced disseminated disease, resection of a colonic cancer is the only advisable primary treatment, whereas an elderly patient with a relatively asymptomatic primary and evidence of widespread dissemination may escape resection. Elective surgery under the age of 80 years has an overall in-hospital mortality of 8% compared with 16% mortality in those over the age of 80 [20]. Informed consent from the patient following discussion of the risks of death, complications such as anastomotic dehiscence, venous thromboembolism, wound infection, urinary and sexual disturbance following rectal excision, and disease recurrence must be obtained [35]. Mechanical bowel preparation before surgery is no longer obligatory except where an upstream stoma is planned with

risk of stercoral perforation. This is rare with colonic tumours and more applicable to total mesorectal excision surgery in rectal cancer. The effects of an early leak (usually due to poor technique) would probably be obviated by bowel preparation, but most leaks occur late after the patient has recommenced oral feeding [35,36]. However, the use of a combined isosmotic mechanical bowel preparation with oral antibiotics before elective colorectal surgery is currently recommended for reducing postoperative (surgical site) infection even within the enhanced recovery pathway [37]. All patients should receive intravenous antibiotic prophylaxis as several randomized trials have demonstrated the reduction of the risk of sepsis after colorectal surgery [38]. A single dose of cephalosporin plus metronidazole at time of surgery is effective in preventing wound infection [39]. Subcutaneous heparin or intermittent compression is employed as thromboembolism prophylaxis in surgery for colorectal cancer [40,41]. The patient must have blood taken for cross-match, but the amount of blood requested will depend on the individual procedure. Group and save alone will be suitable for most right hemicolectomies. Although there is still some debate on the effects of blood transfusion on prognosis of colorectal cancer [42], it is prudent to have at least two units of blood available for other types of colectomy [35]. The use of predeposited autologous and allogenic blood in patients undergoing resection for colorectal cancer has shown no difference in prognosis [43]. For this reason and because of the case mix in previous studies, the observed immunosuppressive effects of blood transfusion on recurrence must be treated with caution [35].

### Emergency

The most important prognostic factors in emergency colorectal surgery are the pre-operative status, age and faecal peritonitis [20,44,45]. Together the mortality is greater than 60% [44]. Thus, peritoneal sepsis is seldom the sole cause of death but compounds coincidental cardiovascular, respiratory or renal pathology [45,46]. About 20% of patients with colonic cancer will present as an emergency. 16% will present with obstruction but steps should be taken to avoid operating on a pseudo-obstruction. Obstruction is the most likely outcome for cicatrizing tumours which involve the narrower parts of the colon (58% - sigmoid colon and 38% - splenic flexure) [47]. Left-sided lesions precipitate obstructive symptoms at an earlier stage because the content of the left colon is more solid than the right side. However, obstruction of the colon by carcinoma implies a more advanced tumour and poor prognostic variable. In a series of 156 patients with obstruction, hospital mortality was twice that of the non-obstructed group and ability to perform a potentially curative resection was only 58%. The overall 5-year survival rate was only 18% compared with 40% in the uncomplicated cancer resection group [47]. Bleeding and perforation are less common. Colonic perforation is the most lethal complication of colon carcinoma and may occur at the site of the tumour or proximal to an obstructing lesion. It is the perforated tumour that is associated with the higher morbidity and mortality, with a significantly reduced cancer survival [48]. In a series, the operative mortality rate associated with perforated carcinoma was 30%, and the crude 5-year survival rate was only 7% [49]. Fortunately, when perforation occurs it is often in the caecum as a result of distal obstruction in the face of a competent ileocaecal valve (i.e. closed-loop obstruction) [50]. On-table colonic lavage (through a catheter in the caecum, and the effluent drained into a bag from the distal

end of the colon) is most appropriate for obstructing rectal lesions amenable to primary resection, where reservation of colon above a low anastomosis is desirable [51]. If there is significant contamination at the time of surgery, then prolonging antibiotic therapy for the 3-5 days (i.e. therapeutic dose) is appropriate [38,52]. The mortality from emergency/urgent surgery is obviously much higher (>50%) than elective surgery (<5%) due to inadequate preoperative optimization, patient-related factors (comorbidity), faecal peritonitis and the advanced nature of the disease itself. An elderly patient over the age of 80 years with malignant large bowel obstruction has a 1 in 3 chance of in-hospital mortality [20]. Similarly, the in-hospital mortality in the presence of an anastomotic leak is much higher than when there has been no leak [53]. However, with an experienced surgical and anaesthetic staff (surgeon-related factor) the overall mortality should be 20% or less for emergency surgery and <5% for elective surgery for colorectal cancer [13].

### Principles of Resection

It is important to note that local recurrence in colorectal cancer following surgical resection arises for one of the following reasons: 1) inadequate locoregional control, 2) primary tumour disruption in some way at time of the original operation, 3) viable exfoliated cells implanted into the wound/tumour bed/port site/anastomosis [48].

### Positioning

In elective colorectal cancer resection, simultaneous access to the abdomen and perineum is achieved with the patient in the modified lithotomy (Trendelenburg) position of Lloyd-Davies (i.e. a steep head-down tilt, legs abducted, flexed to 30° at the hips and 45° at the knees, with a sandbag placed under the buttocks and urethral catheterisation) [7,35,54,55]. This would also allow the distal bowel to be washed out prior to anastomosis and, a stapling device can be inserted through the anus. Laparoscopic colorectal resection requires a modified Lloyd-Davies position, with shoulder restraints owing to the steep Trendelenburg and lateral tilt required for left-sided and rectal resections but care should be exercised against brachial plexus injury especially in the morbidly obese [56].

### Objectives of Colon Cancer Surgery

Lymphovascular clearance, (the radical excision of a colonic tumour along with the appropriate vascular pedicle and accompanying lymphatic drainage) is the most appropriate oncological procedure in obtaining loco-regional control [20,25,35,54]. Occasionally, a very limited resection may be appropriate in an unfit patient or one with widespread disease. Classical resection removes the lymphatic drainage that lies along the named arterial blood supply, thereby rendering the associated colon ischaemic. Thus right hemicolectomy removes the ileocolic and right colic arteries at their origins from the superior mesenteric artery, transverse colectomy removes the middle colic artery and left hemicolectomy removes the left colic artery. Transverse colectomy has fallen out of favour owing to a perception that anastomotic leakage is unacceptably high. The distinction between left hemicolectomy and sigmoid colectomy is irrelevant, if the principle of radical excision of the vascular pedicle is accepted [35]. Thus the type of operation lies between right hemicolectomy and left hemicolectomy, with the extent of bowel resection dependent on site of tumour. In the standard right hemicolectomy the marginal

artery or the right branch of the middle colic artery will need division to complete vascular isolation. For tumours of the descending colon and sigmoid colon, a formal left hemicolectomy involves division of the inferior mesenteric artery at its origin from the aorta [35,54].

## Controversies in Colon Cancer Surgery

### Splenic flexure carcinoma

There are two options with splenic flexure carcinoma. One is to regard the tumour as left-sided, and to carry out a left hemicolectomy, dividing the inferior mesenteric artery at its origin and dividing the left branch of the middle colic artery. The other approach is to carry out an extended right hemicolectomy, dividing the middle colic artery and the ascending branch of the left colic artery. Left hemicolectomy will necessitate anastomosis between right colon and rectum, which may be difficult to achieve without tension in some patients [35,54]. Furthermore, the blood supply of the colon is inconstant. In 6% of cases there is no left colic artery and the blood supply of the splenic flexure is from the middle colic artery. In 22% of cases the middle colic artery is absent and the blood supply of the splenic flexure comes from both the left and right colic arteries [8]. For lymphovascular clearance, it would seem sensible to ligate the right colic, middle colic and left colic arteries, making extended right hemicolectomy necessary. For these reasons extended right hemicolectomy, with an anastomosis between sigmoid colon and mobile well-vascularized ileum is preferred [35]. However, the ideal operation will be dictated by individual anatomy, the most important criteria being lack of tension and good blood supply as evidenced by brisk bleeding and good colour at bowel ends [54]. The controversy is highlighted by the Large Bowel Cancer Project [23] which found a high local recurrence rate and poor survival for patients with splenic flexure carcinoma, regardless of stage and presentation, which may reflect surgical inadequacy of primary treatment.

### Locally advanced (T4) tumours

It may still be possible to achieve a curative resection if the surgeon is prepared to resect adjacent involved organs such as ureter, duodenum, stomach, spleen, small bowel, bladder and uterus (Dukes' stage D- added to Dukes' staging later on) with 16.4% five-year survival [57]. In addition, a few surgeons carry out routine oophorectomy as about 5% of women will have macroscopic ovarian metastases and a further 2% will have microscopic disease [20,35,54]. In a patient with a truly inoperable tumour of the colon an ileocolonic bypass may be appropriate for lesions of the right side, whereas for tumours of the distal colon a defunctioning colostomy may be preferable. With multiple colonic tumours, a subtotal or total colectomy should be considered [20,35,54,57].

## Objectives of Rectal Cancer Surgery

a) Firstly, the absence of dissemination poses various questions: Is preoperative radiotherapy indicated for the locally extensive tumour? With the undisturbed pelvis (well oxygenated tissues with increased tumour radiosensitivity, and less small bowel in the radiation field limiting gastrointestinal toxicity), a short course preoperative radiotherapy of 5 x 5 Gy fractions over 1 week followed immediately with surgery reduced local recurrence in resectable (freely mobile) tumour compared to surgery alone [58,59]. An alternative approach in improving local control is a long course

preoperative radiation over 5 weeks with a lower dose per fraction (25 x 2 Gy) used in locally advanced (fixed or tethered) tumour. In these circumstances where radiotherapy is used as a treatment, it is important to leave a sufficient interval that will maximize any tumour shrinkage. Surgery is delayed for 2-3 months when tumour shrinkage is beginning to be balanced by continuing tumour growth of resistant cells [59,60]. Allowing tumour shrinkage and thus permitting tumour excision may, however, have no effect on the way the original stage of the tumour predicted the possibility of occult hepatic metastases, and therefore incurability [48]. Recent randomized trials have shown that concurrent chemotherapy given with radiotherapy (CRT) is more effective than radiotherapy alone when used preoperatively in resectable disease [60-63]. Nonetheless, postoperative strategies allow a targeted approach in patients with high-risk pathological features, albeit with poorer compliance, increased toxicity and a need for higher doses [48].

b) Is the tumour at a level sufficiently proximal to the anorectal junction to be able to be removed by a sphincter-conserving operation? An abdomino-perineal excision of the rectal tumour with a permanent end colostomy may otherwise be necessary. However, in specialist centres, the distal margin is now largely irrelevant for most rectal cancers, as the amount of bowel removed is determined more by the policy of performing total mesorectal excision than it is by considering the distal clearance margin [48]. This is manifested in the successful ultralow intersphincteric resections of rectal cancer [64,65]. However, neoadjuvant chemoradiotherapy is required to reduce locoregional recurrence to an acceptable level [66].

c) Does an apparent locally non-extensive tumour permit a local rather than a major form of removal? Early rectal tumour comprise only about 5%, and a carcinoma confined to the rectal wall has a less than 10% chance of coexisting lymph node metastases [67]. Endoanal ultrasound permits local evaluation of depth and may help predict cases suited for local excision. A small (<3cm in d) low rectal cancer, which on biopsy was well differentiated, would be a potential candidate for local excision, whether by transanal endoscopic microsurgery (TEM) [68] or by a conventional transanal (Parks) approach [69]. The decision to adopt a local approach including local radiotherapy will be influenced by knowledge of the likely cost-benefit of the alternative [70]. For example, the local excision of a tumour confined to the rectal wall has a 15% chance of leaving involved lymph nodes behind but with an approximately 16% mortality for radical surgery in those aged over 80 [48,63].

d) Secondly, an objective of rectal cancer surgery is to prevent local recurrence from tumour disruption. Cutting into the primary tumour while mobilizing it will run a very high risk of spilling viable cells. This would be prevented by (1) resecting en-bloc with the primary tumour an adherent loop of intestine or adjacent organs involved by tumour [26]; (2) avoiding the fragmentation of the mesorectal envelope. Total mesorectal excision using sharp or diathermy dissection will avoid disruption and prevent local recurrence of rectal cancer [24,71] Identifying the presacral nerves (sympathetic) at the sacral promontory at the start of the posterior dissection and the nervi erigentes (parasympathetic S 2,3,4) from the lateral pelvic wall will preserve ejaculation and erectile function respectively [72,73]; (3) avoiding the exploration of the anterior plane in a man with an anterior encroaching tumour. This situation



should no longer arise if a standard preoperative work-up for all cases of rectal cancer includes the rectal cancer protocol MRI [13,22,48]. Denonvillier's fascia is of variable thickness but is often a tough fibrous membrane that provides a firm barrier to the early stages of cancerous spread. It would be oncologically safe to give a long course of chemoradiotherapy and then return 3 months later when tumour shrinkage may allow an uninvolved plane to be found [48,66]. If the patient is young and fit enough to be considered for pelvic exenteration, it should be preceded by chemoradiotherapy and performed by a joint colorectal surgical and urological surgical team. In women, as the vagina acts as a barrier to involvement of the bladder an en-bloc hysterectomy when the uterus/back of the vagina is involved is effective oncological clearance [20,48].

e) Thirdly, the quality of life issues are important in rectal cancer surgery. These include preservation of continence, preservation of reasonable bowel frequency and avoidance as far as possible, of permanent sexual and urinary disturbance. In practice, one is usually guided to the quality of a good anus by a history of flatus incontinence and an absence of episodes of faecal incontinence in the past. It is also important to note that the tumour itself may have contributed to a sense of urgency and thereby lead to unreasonable pessimism as to the true state of the anus [48]. A patient with an undoubtedly poor-quality anus will not benefit from an ultra-low anastomosis and would be very much better off with a colostomy. When the tumour itself is reasonably high in the rectum, then a low Hartmann operation will avoid the complications of a perineal wound, but with a lower tumour an abdominoperineal excision would seem safest [48,74].

## Choice of Operation

The first major surgical innovation based on the pathological appreciation of lymph node spread and aiming at the concept of radical surgery inspired by Halstead was the introduction by Miles of the abdominoperineal excision of the rectum [75]. However, his anatomico-pathologic distribution of regional lymphadenopathy was not in line with the modern view in that involvement distal to the level of the tumour was regarded by Miles as being an important route of spread. Despite a high mortality, approaching 50%, as surgical management improved the operation ultimately became established owing to its oncological merit. In the second decade of the 20<sup>th</sup> century anterior as opposed to the posterior (Kraske) approach to the rectum gained popularity when Dukes found that the extent of infiltration of rectal carcinoma distal to the lower border of the tumour was found to be limited [15].

### Anterior resection or sphincter preserving procedure

With improvement of anastomotic technique including the advent of the endoanal circular stapling device [76], and greater understanding of the pathologic spread of the tumour which is more proximal than distal, anterior resection has become increasingly applied to cancer of the middle rectum and in the lower rectum [77]. It is very uncommon for rectal cancer to spread more than 1.5cm below the distal palpable margin of the tumour except when the tumour is poorly differentiated [15,77]. Thus a 5cm margin is considered for a poorly differentiated tumour, whereas a 2cm margin should suffice otherwise [48]. There is evidence that a distal margin of clearance of 1cm or less is associated with a greater incidence of local recurrence than if the patient had a total rectal excision [63,78,79].

Standard anterior resection does not remove the entire mesorectum but complete mesorectal excision should optimize the capability of anterior resection to achieve local tumour clearance. Given the potential of TME to minimize local recurrence, tumour of the middle or lower third of the rectum should be treated by a total rectal excision. This will require a coloanal anastomosis for restoration of intestinal continuity. Clearly sphincter function must be adequate for a restorative procedure and the addition of a colonic pouch in this reconstruction will optimize function [80]. It has been argued that being able to apply a right-angled clamp below the lower margin of the tumour that is not poorly differentiated in the lower third of the rectum, is clearance enough [48,77] provided that adequate lateral (mesorectal) clearance has been achieved and the margin itself is uninvolved [63,80]. There is a tendency for the inexperienced surgeon to 'cone' in on the distance clearance margin, thereby leaving some of the mesorectum behind on the pelvic walls and increasing the chance of local recurrence [23,24,48,63].

### Abdominoperineal (A-P) excision

The reasons for abdomino-perineal excision include (1) cancers involving the sphincter or so near to it that even an ultralow anterior intersphincteric dissection or attempts to preserve the sphincters are unjustified; (2) the functional result of restorative surgery is likely to be so poor that a colostomy would be an advantage; (3) the potential complications of attempts to restore intestinal continuity are not worth risking, particularly in the frail and elderly [48]. There is a higher positive circumferential resection margin (CRM) rate after A-P resection for technical and oncological reasons. A-P excision gives worse results than it should because of 'coning' of the specimen at the levels of the levators [48]. Thus, the oncological importance of excising widely at the level of the pelvic floor (extralevator excision) and a TME in the abdominal phase. The prone position in performing the perineal part of the operation is thus increasingly favoured as it facilitates the wide pelvic floor excision with improved circumferential resection margins [81]. Intra-operative perforation of the surgical specimen is common (8-26%) [82,83] with a 30% local recurrence rate being greatest for tumours lying between 0 and 5 cm from the anal verge [84]. Information on the site or cause of perforation is sparse and conflicting with individual authors variously emphasizing the perineal phase of the operation, the anterior dissection or nodal spread in advanced tumours. Low tumours appear to be more advanced (T4), have higher recurrence rates and suffer more perforations [85]. The risk of local recurrence can be reduced by improving the pre-operative MR imaging to define lines of excision and perineal technique of anorectal excision alongside TME. Applying preoperative radiotherapy may reduce local recurrence but for the high rates of perineal wound infection and breakdown [62,63,86].

## Controversies in Rectal Cancer Surgery

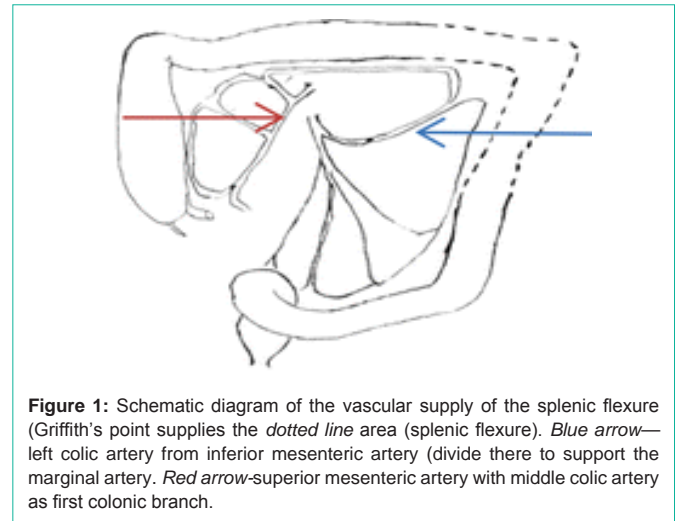
### How radical does the pelvic clearance need to be in a standard case of rectal cancer?

**Total mesorectal excision (TME):** Total mesorectal excision should be performed when operating on a case of low or mid-rectal cancer, but there is lack of clear evidence when dealing with upper rectal cancer. Tumour deposits can be found as much as 3cm [87] or 4cm [23] below the distal margin of the tumour. It would seem

reasonable in oncological terms to perform a mesorectal clearance 5cm below the tumour, which in an upper rectal cancer would not always involve total mesorectal excision. Nevertheless, an extensive distal clearance of mesentery of at least 5cm would make their anastomosis at the junction of the mid and lower thirds of the rectum. Despite the good results of TME [5,23,88], function in the absence of a small colonic pouch or a short rectal remnant is inferior, and complications (anastomotic leak, sexual and urinary disturbance) are relatively high, making a temporary stoma advisable in all cases [13,20,74]. The Dutch total mesorectal excision radiotherapy trial showed routinely applied preoperative radiotherapy is an advantage when employing total mesorectal excision with 15% higher recurrence rate at 5 years in the surgery alone group [89]. However, some faecal incontinence was seen in 62% receiving radiotherapy compared with 39% without [90]. Short course high-dose preoperative radiotherapy also rendered late adverse effects including anal and urinary dysfunction and cardiovascular morbidity at long-term follow-up [91]. This may preclude its additive use with TME for early rectal cancer as being an over-treatment with risks of late radiation damage without benefit unless, a more efficient local mode and dose of application of radiotherapy (brachytherapy) with less adverse effects is utilized.

**Extended pelvic lymphadenectomy:** Lymph nodes are involved in cases of rectal cancer along the internal iliac vessels. These involved lymph nodes lie outside the boundaries of a conventional TME and should be responsible for local recurrence [48,92,93]. However, a Swedish study found that only 2 of 33 pelvic recurrences after TME surgery might be attributed to lateral pelvic side wall lymph node involvement [94]. In Japan, where pelvic lymphadenectomy is practiced, analysis of lateral spread has shown that spread to the lateral pelvic wall lymph nodes is related to the depth of invasion and the level of the tumour from the anal verge [95]. In addition, in advanced low tumours as many as 20-30% of patients may have lateral nodes involved [96]. However, extended pelvic lymphadenectomy is unlikely to become popular in the West, largely because of poor functional result (all patients had sexual and urinary disturbance), lengthy operation times. Excessive blood loss and the perceived success of TME [92].

**High vs low vascular ligation:** The inferior mesenteric artery can be divided either flush on the aorta (high ligation) or at the level of the sacral promontory, in effect preserving the left colic artery (low ligation) [48]. Although about 20% of cases with apical lymph node involvement will be cured there is no benefit to high ligation in terms of cancer survival [97,98]. A possible explanation is that cases with extensive lymph node involvement in one plane will also have extensive pelvic wall lymph node requiring treatment [48]. When performing anastomosis to the anus the descending colon should be used in preference to the sigmoid colon. Not only does the sigmoid colon generate fairly high pressures, which could lead to relatively poor function, but more importantly the marginal artery is absent in the sigmoid colon, which is prone to ischaemia if used for anastomosis. However, the descending colon will not reach the anus unless the splenic flexure is mobilized in all cases, and there is a flush tie of the inferior mesenteric artery on the aorta. This is because the left colic artery is too short and will not permit the descending colon to reach the anus if a low ligation that preserves the left colic artery is performed. Hence a low anastomosis will always need a high



**Figure 1:** Schematic diagram of the vascular supply of the splenic flexure (Griffith's point supplies the dotted line area (splenic flexure). Blue arrow—left colic artery from inferior mesenteric artery (divide there to support the marginal artery). Red arrow—superior mesenteric artery with middle colic artery as first colonic branch.

ligation, but for technical rather than oncological reasons [48,97]. A high anastomosis can be achieved quite easily with either a high or low ligation. The marginal artery blood supply in the region of the splenic flexure (Griffith's point) [99] is precarious and it is important to preserve the terminal two branches of the left colic artery to act as support for the thin marginal artery when mobilizing the blood supply at the splenic flexure (Figure 1) [48]. Further length can also be gained by division of the inferior mesenteric vein (IMV) at the inferior border of the pancreas which would bring down the splenic flexure for a low anastomosis [54].

### Hand-suturing or stapled anastomosis

The interrupted serosubmucosal technique initially described by Matheson et al [100] is recommended for its adaptability to any anastomosis involving the colon and it is also associated with best results in the literature with leak rates of 0.5 - 3% in sizeable series [101,102]. For colorectal and ileorectal anastomoses, the posterior row of sutures is inserted first, the knots being tied on the luminal side after the proximal bowel has been 'parachuted' down the sutures to the upper rectum. After right hemicolectomy the most widely employed stapled anastomosis is the 'functional end-to-end'. Here, the ends of the colon and ileum are stapled closed at the time of the specimen excision, and two small enterotomies are made to permit insertion of the limbs of a linear cutting stapler. The anastomosis is then performed by firing the stapler, taking care not to include mesentery, and after checking the staple line for bleeding the remaining defect is closed with linear stapler [35]. After left hemicolectomy, or anterior resection of rectal cancer, a true end-to-end anastomosis can be performed using a circular anastomosing stapler introduced per anum [35,48,54]. Several studies advocate intraoperative air testing as a means of identifying the lack of integrity of a colorectal anastomosis [103,104]. There seems to be no consistent difference in colonic anastomotic dehiscence between the two approaches although there was evidence in one trial that tumour recurrence was less in the stapled group presumably because of less tumour disruption [105]. A combination of anatomical inaccessibility, less than optimal blood supply, tightly closed anal sphincters below an ultralow anastomosis and an infected pelvic haematoma are likely to be contributory to anastomotic leakage. Thus, there is the potential role of a transanal drainage tube in the reduction of the endoluminal pressure as well

as faecal diversion resulting in a protective effect on anastomotic healing. The current vogue of placing a transanal drainage tube in patients with colorectal anastomoses is safe, simple and claims to reduce the rate and severity of anastomotic leakage [106]. However, there has only been one prospective randomized controlled study that demonstrated this benefit [107]. Nonetheless, surgeons should expect to achieve an overall leak rate below 4% for colonic resection [13,22].

### Laparoscopic TME, Transanal (Ta TME) or Robotic transanal TME?

The safety of laparoscopic TME has been established in several randomized studies [108-111] but a transanal (Ta) TME has the potential to define the radial and distal margins more clearly. Due to utilization of carbon dioxide (CO<sub>2</sub>) for insufflation there are advantages in terms of vision and dissection. Ta TME is ideal in patients in whom a laparoscopic pelvic dissection is difficult (male, obese, preoperative radiotherapy, tumour located in the lower third of the rectum), carrying a risk of inadequate oncological clearance [112]. Thus it might be a promising alternative to laparoscopic TME. With Ta TME, assessing precisely the distal margin of the tumour from the beginning of the procedure has the potential to (1) improve resection quality, and therefore clinical outcome; and (2) decrease the incidence of abdominoperineal resection (APR), thereby improving sphincter preservation rates [113]. In addition, difficulties in pelvic exposure and limitations of instrumentation can affect not only dissection but also the preservation of autonomic pelvic nerves and the achievement of a restorative procedure [114]. TaTME would facilitate the dissection of the Denonvilliers fascia minimizing injury to the prostate, seminal vesicles or vagina. This is especially true with anterior tumours as they have a high risk of positive CRM [48,115]. Starting with dissection from the perineum, a transanal purse-string suture below the tumour ensures an adequate oncological distal margin will be achieved [116] and, avoids distal cross stapling in a narrow pelvis which increases the potential for anastomotic leak [117]. It also allows for exteriorization of the specimen transanally although transanal extraction of the surgical specimen en bloc may not always be possible, particularly in patients with a narrow, deep pelvis, bulky mesentery, and constraints by other pelvic viscera, such as prostatic hypertrophy [118]. Transanal extraction avoids large abdominal extraction incisions and a wound protector minimizes the risk of tumour spillage. Following the developments of naturally orifice transluminal endoscopic surgery (NOTES) transanal endoscopic microsurgery (TEMS), and transanal minimally invasive surgery (TAMIS), TaTME has been reported as feasible and safe in several large studies [119-126]. Although the experience with TaTME is still limited the preliminary data on complications and short-term and oncological safety are good [123-125], but also emphasize the importance of careful patient selection. There is an increased risk of urethral injury from TaTME early in the learning curve especially at the level of the post-prostatic urethra in the setting of anterior tumours and prior pelvic irradiation [112] which rarely occurs for standard TME. CO<sub>2</sub> insufflation might also show areolar planes beyond the scope of dissection thus leading the surgeon off plane to the pre-sacral space with a risk of inadvertent injury to both pelvic side wall autonomic nerves and the sacral venous plexus posteriorly, resulting in haemorrhage [113]. There is a need for large scale trials focusing on long-term outcomes and oncological safety before widespread

adoption of TaTME can be recommended [127]. Whilst some groups have successfully employed the robotic approach to reduce these risks [128,129], there remains a paucity of data regarding their superiority regarding the oncological outcomes thus far. Although the number of patients remains limited, the safety seems to be similar as standard TaTME. Real advantages are still hypothetical but robotic technology might help to overcome the steep learning curve, which seems to be associated with TaTME. New single-site surgery platforms are awaited. They may facilitate docking and transanal access [130].

### Emergency Surgery

In order that compromise in surgical technique does not contribute to the poor prognosis after emergency resection of colorectal cancers, surgery should be performed with the same surgical and oncological principles as for elective colorectal cancer surgery [47,54].

### Management of obstruction

The short term aim of surgery for colonic obstruction is relief of the obstruction with survival of the patient. However, the opportunity of long-term care should not be overlooked. Primary resection of the cancer is indicated where possible and local resections and other non-curative procedures may be employed if there is non-remediable metastatic spread, or the patient's life placed at risk by a resectional procedure. Once mechanical obstruction is diagnosed and the patient resuscitated, laparotomy should proceed with experienced surgical and anaesthetic staff preferably during the day [49,50]. The first task at laparotomy is usually to decompress the gaseous distention of the large bowel, and this can be achieved by inserting a 19-gauge (white) needle attached to suction into the lumen through a convenient taenia. If a larger tube is required to evacuate large amounts of liquid faeces, this should be inserted into the caecum via an enterotomy in the terminal ileum [47-50,54]. When the bowel can be safely handled, and the obstruction is due to a right-sided lesion, a standard right hemicolectomy is usually easy and safe. If the cancer is on the left side, several options are available [49,50,54]. Traditionally, obstructing left-sided cancers were treated by a three-stage approach, starting with a defunctioning loop colostomy, followed by resection and anastomosis, and then by closure of the defunctioning stoma. This gradually gave way to a two-stage procedure, with primary resection of the tumour in the form of a Hartmann operation, where the proximal colon is brought out as an end colostomy and the distal segment either closed off or brought out as a mucous fistula [131]. Recently, there has been a move towards one-stage procedures, facilitated by improvement in perioperative care which anticipate and treat cardiovascular instability and hypoxia promptly, promoting anastomotic healing in the critical first 48hrs after surgery [38,45,54]. The choice lies between a subtotal colectomy with ileo-colic or ileorectal anastomosis and a left hemicolectomy [132] after on-table colonic irrigation with more acceptable postoperative bowel function [49-52,54]. For tumours in the region of the splenic flexure, the former approach is sensible, especially if doubt about the viability of the caecum. Increasingly, expanding metal stents are being used in obstructing left-sided colonic tumours to allow decompression followed by bowel preparation and elective resection of tumour [133].

### Management of perforation

In the patient who is found to have a perforated caecum as a result



of an obstructing distal cancer, an extended right hemicolectomy or subtotal colectomy is the treatment of choice. Whether or not an anastomosis is fashioned will depend on the degree of peritoneal contamination. For the cancer which has perforated primarily, it is important to resect the lesion itself to eliminate not only the malignancy but also the source of sepsis. This can be technically demanding, and for left-sided lesions will almost always necessitate a Hartmann procedure [47,49,54]. A covering defunctioning stoma may be required if a primary anastomosis is performed. A loop ileostomy is favoured to a loop transverse colostomy in defunctioning a distal colonic anastomosis especially because following its closure the blood supply to the distal colon is not compromised, whereas the marginal artery is potentially at risk when the latter is closed or resected at the time of closure [54].

## Conclusions

The outcome of surgical management of colorectal cancer is biologically predetermined by the presence or absence of occult metastases. Locoregional control with surgical oncological principles and radiotherapy will optimize adjuvant systemic chemotherapy and improve the chance of cure. In rectal cancer surgery quality of life issues including preservation of continence, preservation of reasonable bowel frequency and avoidance as far as possible, of permanent sexual and urinary disturbance are important.

## Acknowledgement

I acknowledge Prof Robin Phillips whose gift of his textbook 'Colorectal Surgery-a companion to surgical specialist practice' during my post graduate term at St Mark's Hospital, London in 2009 rendered the impetus to write this review.

## References

- World Health Organization Agency for Research on cancer. GIOBOCAN 2012: Estimated cancer incidence, mortality and prevalence worldwide in 2012.
- Behbehani A, Sakwa M, Ehrlichman R, et al. Colorectal carcinoma in patients under age 40. *Ann Surg* 1985; 202: 610-614.
- Rim SH, Seef L, Ahmed F, et al. Colorectal cancer incidence in the United States, 1999-2004: an updated analysis of data from the National Programme of Cancer Registries and the Surveillance, Epidemiology, and End Results Program. *Cancer*. 2009; 115: 1967-1976.
- Cancer Research UK Statistics on Colorectal Cancer.
- UKCCCR. Handbook for the clinicopathological assessment and staging of colorectal cancer. UKCCCR, 1989.
- Bass BL, Enker WE, Lightdale CJ. Advances in colorectal carcinoma surgery. New York: World Medical Press. 1993; 37.
- Loffeld RJLF, Flens M, Fransen G, den Boer FC, Bochove VA. The localization of cancer in the sigmoid, rectum or rectosigmoid junction using endoscopy or radiology- What is the most accurate method? *J GastrointestOncol*. 2014; 5: 469- 473.
- Williams PL, Warwick R. Gray's anatomy. Edinburgh; Churchill Livingstone. 1980; 1356.
- Glimelius B. Neo-adjuvant radiotherapy in rectal cancer. *World J Gastroenterol*. 2013; 19: 8489-8501.
- Ngan SY, Burmeister B, Fisher RJ, et al. Randomized trial of short course radiotherapy versus long- course chemoradiation comparing rates of local recurrence in patients with T3 rectal cancer. Trans -Tasman Radiation Oncology Group trial 0.1.04. *J ClinOncol*. 2012; 30: 3827-3833.
- Atkin WS, Saunders BP. Surveillance guidelines after removal of colorectal adenomatous polyps. *Gut*. 2002; 51: 6-9.
- Association of Coloproctology of Great Britain and Ireland. Guidelines for the management of colorectal cancer, 3<sup>rd</sup> edn. Association of Coloproctology of Great Britain and Ireland. 2007.
- Anderson N, Cook HB, Coates R. Colonoscopically detected colorectal cancer missed on barium enema. *Gastro intest Radiol*. 1991; 16: 123-127.
- Dukes CE. The classification of cancer of the rectum. *J Pathol Bacteriol*. 1932; 35: 323-332.
- Wood DA, Robbins GF, Zippin C, et al. Staging cancer of the colon and cancer of rectum. *Cancer*. 1979; 43: 961-968.
- Jass JR, Love SB, Northover JMA. A new prognostic classification of rectal cancer. *Lancet*. 1987; 1: 1303-1306.
- Williams NS, Dudley P, Quirke P, et al. Preoperative staging of rectal neoplasm and its impact on clinical management. *Br J Surg*. 1985; 72: 868-874.
- Huddy SP, Husband EM, Cook MG, et al. Lymph node metastases in early rectal cancer. *Br J Surg*. 1993; 80: 1457-1458.
- Fielding LP, Phillips RKS, Fry JS, et al. Prediction of outcome after curative surgery for large bowel cancer. *Lancet*. 1986; 328: 904-907.
- Phillips RKS, Hittinger R, Blesovsky L, et al. Large bowel cancer: surgical pathology and its relationship to survival. *Br J Surg*. 71: 604-610.
- Scottish Intercollegiate Guidelines Network. Guidelines for the management of colorectal cancer SIGN. 2003.
- Aldridge MC, Phillips RKS, Hittinger R, et al. Influence on tumour site on presentation, management and subsequent outcome in large bowel cancer. *Br J Surg*. 1986; 73: 663-670.
- Heald RJ, Husband EM, Ryall D. The mesorectum in rectal cancer surgery: the clue to recurrence? *B J Surg*. 1982; 69: 613-616.
- Quirke P, Dixon MF. The prediction of local recurrence in rectal adenocarcinoma by histopathological examination. *Int J Colorectal Dis*. 1988; 3: 127-131.
- Phillips RKS, Hittinger R, Blesovsky L, et al. Local recurrence after 'curative' surgery for large bowel cancer. *Lancet*. 1986; ii: 904-906.
- Finlay JG, Meek DR, Gray HW, et al. The incidence and detection of occult hepatic metastases in colorectal carcinoma. *Br Med J*. 1982; 284: 803-805.
- Garden OJ, Rees M, Poston GJ, et al. Guidelines for resection of colorectal liver metastases. *Gut*. 2006; 55: 1-8.
- Brown G, Richards CJ, Newcombe RG, et al. Rectal carcinoma: thin-section MR imaging for staging in 28 patients. *Radiology*. 1999; 211: 215-222.
- Beets-Tan RG, Beets GL, Vliegen RF, et al. Accuracy of magnetic resonance imaging in prediction of tumour-free resection margin in rectal cancer surgery. *Lancet*. 2001; 357: 497-504.
- Diagnostic accuracy of preoperative magnetic resonance imaging in predicting curative resection of rectal cancer: prospective observational study. *BMJ*. 2006; 333: 779.
- Extramural depth of tumour invasion at thin-section MR in patients with rectal cancer; results of the MERCURY study. *Radiology*. 2007; 243: 132-139.
- Frykholm GJ, Pahlman L, Glimelius B. Combined chemo- and radiotherapy vs radiotherapy alone in the treatment of primary, non-adenocarcinoma of the rectum. *Int J Radiat Oncol Biol Phys*. 2001; 50: 427-434.
- Shirouzu K, Isomoto H, Kakegawa T. Total pelvic exenteration for locally advanced colorectal carcinoma. *Br J Surg*. 1996; 83: 32-35.
- Steele R. Colonic cancer. In: *Colorectal surgery: A companion to specialist surgical practice*. Robin K. S. Phillips Editor; Saunders Elsevier 4<sup>th</sup> Edn, London 2009.
- Guanega K, Attallah AN, Castro AA, et al. Mechanical bowel preparation for elective colorectal surgery. 2011.



36. The Cochrane Database of Systematic reviews 2006; issue 2. John Wiley and Sons Ltd.
37. Holubar SD, Hadrick T, Gupta R, Kellum P, Hamilton M, Gan TJ, et al. Perioperative Quality initiative (POQI)1 Workgroup. American society for enhanced recovery (ASER) and Perioperative quality initiative (POQI) joint consensus statement on prevention of postoperative infection within an enhanced recovery pathway for elective colorectal surgery. *Perioper Med (Lond)*. 2017; 6: 4.
38. Keighley MRB, Williams NS. Perioperative care. In: Keighley MRB, Williams NS (eds) *Surgery of the anus, rectum and colon*, 3<sup>rd</sup> edn. Elsevier Saunders 2008.
39. Rowe-Jones DC, Peel ALG, Kingston RD et al. Single dose cefotaxime plus metronidazole versus three dose cefotaxime plus metronidazole as prophylaxis against wound infection in colorectal; multicentric prospective randomized study. *Br Med J*. 1990; 300: 18-22.
40. Collins R, Scrimgeour A, Yusuf S, et al. Reduction in fatal pulmonary embolism and venous thrombosis by perioperative administration of subcutaneous heparin. *N Engl J Med*. 1988; 318: 1162-1173.
41. Kakkar VV, Cohen AT, Edmonson RA, et al. Low molecular weight versus standard heparin for prevention of venous thromboembolism after major abdominal surgery. *Lancet*. 1993; 341:259-265.
42. Burrows L, Tatter P. Effects of blood transfusions on colonic malignancy recurrence rate. *Lancet*. 1982; 2: 662.
43. Busch ORC, Hop WCJ, Hoynck van Papendrecht MAW, et al. Blood transfusions and prognosis in colorectal cancer. *N Eng J Med*. 1993; 328: 1372-1376.
44. Krukowski ZH, Matheson NA. Emergency surgery for diverticular disease complicated by generalized and faecal peritonitis: a review. *Br J Surg* 1984; 71: 921-927.
45. Weledji EP, Ngowe MN. The challenge of intra-abdomina sepsis. *Int J Surgery(Lond)*. 2013;11:290-295.
46. Mclauchan GJ, Anderson ID, Grant IS, Fearon KCH. Outcome of patients with abdominal sepsis treated in an intensive care unit. *Br J Surg*. 1995; 82: 624-629.
47. Phillips RKS, Hittinger R, Fry JS, Fielding LP. Malignant large bowel obstruction. *Br J Surg*. 1984; 72: 296-302.
48. Phillips RKS. In: *Colorectal surgery: A companion to specialist surgical practice*. Robin K. S. Philips Editor; Saunders Elsevier 4th Edition, London 2009.
49. Kelley WE Jr, Brown PW, Lawrence W Jr, Terz JJ. Penetrating, obstructing, and perforating carcinomas of the colon and rectum. *Arch Surg*. 1981; 116: 381-384.
50. Weledji EP. Perspectives on large bowel obstruction. *IJS Short report*. 2017; 2: 1-4.
51. Dudley HAF, Radcliffe AG, McGeehan D. Intraoperative irrigation of the colon to permit primary anastomosis. *Br J Surg*. 1980; 67: 80-81.
52. Weledji EP, Ngowe MN. Surgical measures to reduce infection in open colorectal surgery. *East Central African J Surg* 2013; 18: 1.
53. Fielding LP, Stewart-Brown S, Blesovsky L, et al. Anastomotic integrity after operations for large bowel cancer. A multicenter study. *Br Med J*. 1980; 281: 411-414.
54. Windsor A, Phillips R, Harly P. Colon. In: *General Surgical operations*. Ed RM Kirk 4<sup>th</sup> edn 2000. Churchill Livingstone. 7: 549-573.
55. Lloyd-Da vies OV. Lithoomy-Trendelenburg position for resection of rectum and lower pelvic colon. *Lancet*. 1939; 2: 74-76.
56. Jenkins I, Kennedy R. laparoscopic surgery and enhanced recovery programmes in colorectal disease. In: *A companion to specialist surgical practice: Colorectal Surgery*. Robin KS Phillips Editor, Saunders Elsevier London 4<sup>th</sup> edn 2009.
57. Turnbull RB, Jr, Kyle K, Watson FR, Spratt J. Cancer of the colon: the influence of the 'no touch' isolation technique on survival rates. *Ann Surg*. 1967; 166: 420-427.
58. Swedish Rectal Cancer Trial. Improved survival with preoperative radiotherapy in resectable rectal cancer. *N Engl J Med*. 1997; 136: 980-987.
59. Marsh PJ, James RD, Scholfield PF. Adjuvant preoperative radiotherapy for locally advanced rectal carcinoma. Results of a prospective, randomized trial. *Dis Colon Rectum*. 1994; 37: 1205-1214.
60. Hansen MH, Kjaeve J, Revhaug A, Eriksen MT, Wibe A, Vonen B. Impact of radiotherapy on local recurrence of rectal cancer in Norway. *Br J Surg*. 2007; 94: 113-118.
61. Bosset JF, Collette L, Calais G, et al. Chemotherapy with preoperative radiotherapy in rectal cancer. *N Engl J Med*. 2006; 355: 1114-1123.
62. Gerard JP, Conroy T, Bonnetain F, et al. Preoperative radiotherapy with or without concurrent fluorouracil and leucovorin in T3-4 rectal cancers: results of FFCD 9203. *J Clin Oncol*. 2006; 24: 4620-4625.
63. Phillips RKS, Hittinger R, Blesovsky L, et al. Local recurrence after 'curative' surgery for large bowel cancer. 2. The rectum and rectosigmoid. *Br J Surg*. 1984; 71:17-20.
64. Hohenberger W, Merkel S, Matzel K, Bittorf B, Papadopoulos T, Gohl J. The influence of abdomino-peranal (intersphincteric) resection of lower third rectal carcinoma on the rates of sphincter preservation and locoregional recurrence. *Colorectal Disease*. 2006; 8: 23-33.
65. Tiret E, pourpadin B, McNamara D, et al. Ultralow anterior resection with intersphincteric dissection: what is the limit of safe sphincter preservation? *Colorectal Dis*. 2003; 5: 454-457.
66. Radcliffe A, Rofo C, Evans M, et al. Preoperative chemoradiation for locally advanced rectal cancer: RO resections are the crucial surrogate endpoint. *Colorectal Dis*. 2003; 5: 14.
67. Huddy SP, Husband EM, Cook MG, et al. Lymph node metastases in early rectal cancer. *Br J Surg*. 1993; 80: 1457-1458.
68. Suppiah A, Masleker S, Alabi J, Hartley E, Monson JRT. Transanalendoscopic microsurgery in early rectal cancer: time for a trial? *Colorectal Disease*. 2007; 10: 314-329.
69. Parks AG. Transanal technique in low rectal anastomoses. *Proc R Soc Med*. 1972; 65: 975-976.
70. Hershman MJ, Sun Myint A, Makin CA. Multimodality approach in curative local treatment of early rectal carcinomas. *Colorectal Dis*. 2003; 5: 445-450.
71. McFarlane JK, Ryall RD, Heald RJ. Mesorectal excision for rectal cancer. *Lancet*. 1993; 341: 457-460.
72. Heald RJ, Moran BJ, Brown G, et al. Optimal total mesorectal excision for rectal cancer is by dissection in front of Denonvillier's fascia. *Br J Surg*. 2004; 91: 121-123.
73. Weledji EP, Eyongetah D. The anatomical basis for autonomic dysfunction in surgical coloproctology. *Int J Surgical Research*. 2014; 3: 7-14.
74. Camilleri-Brennan J, Steele RJ. Quality of life after treatment of rectal cancer. *Br J Surg*. 1998; 85: 1036-1043.
75. Miles WE. A method of performing abdomino-perineal excision for carcinoma of the rectum and of the terminal portion of the pelvic colon. *Lancet*. 1908; 2: 1812-1813.
76. Knight CD, Griffen FD. An improved technique for low sphincter resection of the rectum using the EEA stapler. *Surgery*. 1980; 88: 710.
77. Heald RJ, Leicester RJ. The low stapled anastomosis. *Br J Surg*. 1981; 68: 333-337.
78. Williams NS, Dixon M, Johnston D. Reappraisal of the 5cm rule of distal excision for carcinoma of the rectum: a study of distal intramural spread and of patient's survival. *Br J Surg*. 1983; 70: 150-154.
79. Karanjia ND, Schache DJ, North WRS, et al. 'Close shave' in anterior resection. *Br J Surg*. 1990; 77: 510-512.

80. Phillips RKS. Adequate distal margin of resection of adenocarcinoma of the rectum. *World J Surg.* 1992; 16: 463-466.
81. Hallbook O, Paholman L, Krog M, et al. Randomized comparison of straight and colonic J pouch anastomosis after low rectal excision. *Ann Surg.* 1996; 224: 58-65.
82. Holm T, Ljung A, Haggmark T, et al. Extended abdominoperineal resection with gluteus maximus flap reconstruction of the pelvic floor for rectal cancer. *Br J Surg.* 2007; 94: 232-238.
83. Porter GA, O'Keefe GE, Yakimets WW. Inadvertent perforation of the rectum during abdominoperineal resection. *Am J Surg.* 1996; 172: 324-327.
84. Slanetz CA. The effect of inadvertent intraoperative perforation on survival and recurrence in colorectal cancer. *Dis Colon Rectum.* 1984; 27: 791-797.
85. Eriksen MT, Wibe A, Syse et al. Inadvertent perforation during rectal cancer resection in Norway. *Br J Surg.* 2004; 91: 210-216.
86. Radcliffe A. Can the results of anorectal (abdominoperineal) resection be improved: are circumferential resection margins too often positive? *Colorectal Dis.* 2005; 8: 160-167.
87. Scott N, Jackson P, Al-Jaberi T, et al. Total mesorectal excision and local recurrence: a study of distal spread in the mesorectum distal to rectal cancer. *Br J Surg.* 1995; 82: 1031-1033.
88. Wibe A, Syse A, Anderson E, et al. Oncological outcomes after total mesorectalexion for cure for the lower rectum: anterior vs. abdominoperineal resection. *Dis Colon Rectum.* 2004; 47: 48-58.
89. Kapiteijn E, Marijnen CAM, Nagtegaal ID, et al. Preoperative radiotherapy combined with total mesorectal excision for resectable rectal cancer. *N Eng J Med.* 2001; 345: 638-646.
90. Lange MM, Der Dulk M, Bossema ER, et al. Risk factors for faecal incontinence after rectal cancer treatment. *Br J Surg.* 2007; 94: 1278-1284.
91. Pollack J, Holm T, Cedermark B, Altman D, Holmstrom B, Glimelius B, et al. Late adverse effects of short-course preoperative radiotherapy in rectal cancer. *Br J Surg.* 2006; 93: 1519-1525.
92. Enker WE, Philipshen SJ, Heilwell ML et al. En bloc pelvic lymphadenectomy and sphincter preservation in the surgical management of rectal cancer. *Ann Surg.* 1986; 293: 426-433.
93. Moriya Y, Hojo K, Sawada T, et al. Significance of lateral node dissection for advanced rectal carcinoma at or below the peritoneal reflection. *Dis Colon Rectum.* 1989; 32: 307-315.
94. Syke E, Torkzad MR, Blomqvist L, et al. Radiological findings do not support lateral residual tumour as a major cause of local recurrence of rectal cancer. *Br J Surg.* 2006; 93:113-119.
95. Fujita S, Yamamoto S, Akasu M, et al. Lateral pelvic lymph node dissection for advanced lower rectal cancer. *Br J Surg.* 2003; 90: 1580-1585.
96. Harnsberger JR, Vernava VM III, Longo WE. Radical abdominopelvic lymphadenectomy: historic perspective and current role in the surgical management of rectal cancer. *Dis Colon Rectum.* 1994; 37: 73-87.
97. Surtees P, Ritchie J, Philips RKS. High versus low ligation of the inferior mesenteric artery in rectal cancer. *Br J Surg.* 1992; 79: 618-621.
98. Corder AP, Karanjia ND, Williams JD, et al. Flush aortic tie versus selective preservation of the ascending left colic artery in low anterior resection for rectal carcinoma. *Br J Surg.* 1992; 79: 680-682.
99. Griffith's D. Surgical anatomy of the blood supply of the distal colon. *Ann R Coll Surg Engl.* 1956; 19: 241-256.
100. Matheson NA, McIntosh CA, Krukowski ZH. Continuing experience with single layer appositional anastomosis in the large bowel. *Br J Surg.* 1985; 72: 104-106.
101. Leslie A, Steele RJC. The interrupted serosubmucosal anastomosis-still the gold standard. *Colorectal Dis* 2003; 5: 362-366.
102. Carty NJ, Keating J, Campbell J, et al. Prospective audit of extramucosal technique for intestinal anastomosis. *Br J Surgery.* 1991; 78: 1439-1441.
103. Davies AH, Bartolo DC, Richards AE, et al. Intraoperative air testing: an audit on rectal anastomosis. *Ann R Coll Surg Engl.* 1988; 70: 345-347.
104. Beard JD, Nicholson MC, Sayers RD, Lloyd D, Everson NW. Intraoperative air testing of colorectal anastomoses: a prospective randomized trial. *Br J Surg.* 1990; 77: 1095-1097.
105. Docherty JG, McGregor JR, Akyol AM, et al. Comparison of manually constructed and stapled anastomoses in colorectal surgery. *Ann Surg.* 1995; 221: 176-184.
106. Brandl A, Szipin S, Mittermain R, Weiss S, Pratschke J, Kafka-Ritsch R. Transanal drainage tube reduces rate and severity of anastomotic leakage in patients with colorectal anastomosis: A case-controlled study. *Annals Med and Surg.* 2016; 6: 12-16.
107. Xiao L, Zhang WB, Jiang PC, Bu XF, Yan Q, Li H, et al. Can transanal tube placement after anterior resection for rectal carcinoma reduce anastomotic leakage rate? A single-institution prospective randomized study. *World J Surg.* 2011; 35: 1367-1377.
108. van der Pas MH, Haglind E, Cuesta MA, Fürst A, Lacy AM, Hop WC, et al. Colorectal cancer Laparoscopic or Open Resection II (COLOR II) Study Group. Laparoscopic versus open surgery for rectal cancer (COLOR II): short-term outcomes of a randomised, phase 3 trial. *Lancet Oncol.* 2013; 14: 210-218.
109. Ng SS, Lee JF, Yiu RY, Li JC, Hon SS, Mak TW, et al. Long-term oncologic outcomes of laparoscopic versus open surgery for rectal cancer: a pooled analysis of 3 randomized controlled trials. *Ann Surg.* 2014; 259: 139-147.
110. Kang SB, Park JW, Jeong SY, Nam BH, Choi HS, Kim DW, et al. Open versus laparoscopic surgery for mid or low rectal cancer after neoadjuvantchemoradiotherapy (COREAN trial): short-term outcomes of an open-label randomised controlled trial. *Lancet Oncol.* 2010; 11: 637-645.
111. Bonjer HJ, Deijen CL, Abis GA, Cuesta MA, van der Pas MH, de Lange-de Klerk ES, et al. COLOR II Study Group. A randomized trial of laparoscopic versus open surgery for rectal cancer. *N Engl J Med.* 2015; 372: 1324-1332.
112. Fernández-Hevia M, Delgado S, Castells A, Tasende M, Momblan D, Díaz del Gobbo G, et al. Transanal total mesorectal excision in rectal cancer: short-term outcomes in comparison with laparoscopic surgery. *Ann Surg.* 2015; 261: 221-227.
113. Atallah S. Transanal total mesorectal excision: full steam ahead. *Tech Coloproctol.* 2015; 19: 57-61.
114. Hompes R, Arnold S, Warusavitarne J. Towards the safe introduction of transanal total mesorectal excision: the role of a clinical registry. *Colorectal Dis.* 2014; 16: 498-501.
115. de Lacy AM, Rattner DW, Adelsdorfer C, Tasende MM, Fernández M, Delgado S, et al. Transanal natural orifice transluminal endoscopic surgery (NOTES) rectal resection: "down-to-up" total mesorectal excision (TME)--short-term outcomes in the first 20 cases. *Surg Endosc.* 2013; 27: 3165-3172.
116. Hompes R, Guy R, Jones O, Lindsey I, Mortensen N, Cunningham C. Transanal total mesorectal excision with a side-to-end stapled anastomosis - a video vignette. *Colorectal Dis.* 2014; 16: 567.
117. Ito M, Sugito M, Kobayashi A, Nishizawa Y, Tsunoda Y, Saito N. Relationship between multiple numbers of stapler firings during rectal division and anastomotic leakage after laparoscopic rectal resection. *Int J Colorectal Dis.* 2008; 23: 703-707.
118. Atallah S, Albert M, DeBeche-Adams T, Nassif G, Polavarapu H, Larach S. Transanal minimally invasive surgery for total mesorectal excision (TAMIS-TME): a stepwise description of the surgical technique with video demonstration. *Tech Coloproctol.* 2013; 17: 321-325.
119. Araujo SE, Crawshaw B, Mendes CR, Delaney CP. Transanal total mesorectal excision: a systematic review of the experimental and clinical evidence. *Tech Coloproctol.* 2015; 19: 69-82.
120. Atallah S, Martin-Perez B, Albert M, deBeche-Adams T, Nassif G, Hunter L, et al. Transanal minimally invasive surgery for total mesorectal excision (TAMIS-TME): results and experience with the first 20 patients undergoing

- curative-intent rectal cancer surgery at a single institution. *Tech Coloproctol*. 2014; 18: 473–480.
121. de Lacy AM, Rattner DW, Adelsdorfer C, Tasende MM, Fernández M, Delgado S, et al. Transanal natural orifice transluminal endoscopic surgery (NOTES) rectal resection: “down-to-up” total mesorectal excision (TME)--short-term outcomes in the first 20 cases. *Surg Endosc*. 2013; 27: 3165–3172.
122. Fernández-Hevia M, Delgado S, Castells A, Tasende M, Momblan D, Díaz del Gobbo G, et al. Transanal total mesorectal excision in rectal cancer: short-term outcomes in comparison with laparoscopic surgery. *Ann Surg*. 2015; 261: 221–227.
123. Muratore A, Mellano A, Marsanic P, De Simone M. Transanal total mesorectal excision (taTME) for cancer located in the lower rectum: short- and mid-term results. *Eur J Surg Oncol*. 2015; 41: 478–483.
124. Rouanet P, Mourregot A, Azar CC, Carrere S, Gutowski M, Quenet F, et al. Transanal endoscopic proctectomy: an innovative procedure for difficult resection of rectal tumors in men with narrow pelvis. *Dis Colon Rectum*. 2013; 56: 408–415.
125. Tuech JJ, Karoui M, Lelong B, De Chaisemartin C, Bridoux V, Manceau G, et al. A step toward NOTES total mesorectal excision for rectal cancer: endoscopic transanal proctectomy. *Ann Surg*. 2015; 261: 228–233.
126. Velthuis S, Nieuwenhuis DH, Ruijter TE, Cuesta MA, Bonjer HJ, Sietses C. Transanal versus traditional laparoscopic total mesorectal excision for rectal carcinoma. *Surg Endosc*. 2014; 28: 3494–3499.
127. Buchs NS, Nicholson GA, Ris F, Mortensen NJ, Hompes R. Transanal total mesorectal excision: A valid option for rectal cancer? *World J Gastroenterol*. 2015; 21: 11700–11708.
128. Baik SH, Ko YT, Kang CM, Lee WJ, Kim NK, Sohn SK, et al. Robotic tumor-specific mesorectal excision of rectal cancer: short-term outcome of a pilot randomized trial. *Surg Endosc*. 2008; 22: 1601–1608.
129. Halabi WJ, Kang CY, Jafari MD, Nguyen VQ, Carmichael JC, Mills S, et al. Robotic-assisted colorectal surgery in the United States: a nationwide analysis of trends and outcomes. *World J Surg*. 2013; 37: 2782–2790.
130. Atallah S, Martin-Perez B, Parra-Davila E, deBeche-Adams T, Nassif G, Albert M, et al. Robotic transanal surgery for local excision of rectal neoplasia, transanal total mesorectal excision, and repair of complex fistulae: clinical experience with the first 18 cases at a single institution. *Tech Coloproctol*. 2015; 19: 401–410.
131. Rothenberger DA, Mayoral J, Deen K. Obstruction and perforation. In: Williams NS (ed) *Colorectal cancer* Edinburgh: Churchill Livingstone. 1996; 123-133.
132. SCOTIA Study group. Single – state treatment for malignant left-sided colonic obstruction: a prospective randomized trial comparing subtotal colectomy with segmental resection following intraoperative irrigation. *Br J Surg*. 1996; 82: 1622-1627.
133. Watson AJ, Shanmugan V, MacKay I, et al. Outcomes after placements of colorectal stents. *Colorectal Dis*. 2005; 7: 70-73.