

Clinical Image

Symmetric Ulcerative Tumefactions on Buttocks

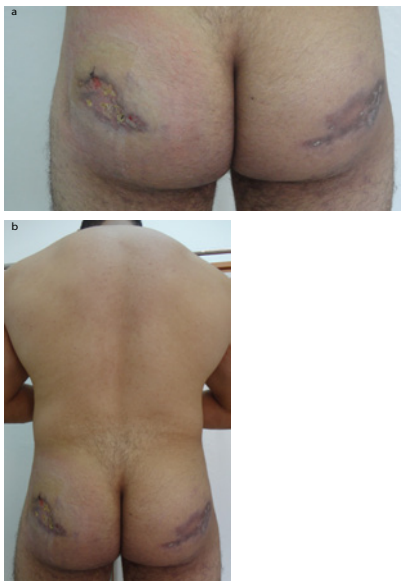
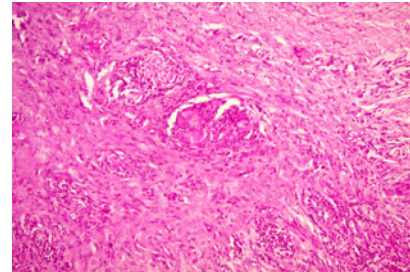
Hjira N* and Boui M

Department of Dermatology, University Mohammed V, Morocco

***Corresponding author:** Hjira N, Department of Dermatology, University Mohammed V, Morocco**Received:** March 26, 2017; **Accepted:** April 07, 2017;**Published:** April 14, 2017

Clinical image

A 24-year-old bodybuilder man presented with a two months history of a progressively enlarging painful lesion on the buttocks. On physical examination, the patient had 7 to 12 cm red-brownish infiltrated tumefactions, with ulcerations on surface symmetrically on outer face of buttocks without fistula (Figures 1a & 1b). There was no regional lymphadenopathy and no other abnormalities were found. The patient was revealed that he had intramuscular injections of anabolic androgenic steroids for 6 months (methandienone and nandrolone decanoate). Skin biopsy showed foreign body granulomatous reaction with multi-nucleated cell (Figure 2).

**Figure 1:****Figure 2:**

Anabolic-Androgenic Steroids (AAS) abuse by the athletes has dramatically increased during the recent decades. They are used to improve athletic performance and male physical attractiveness [1].

Cutaneous manifestations develop early in the use of anabolic-androgenic steroids, allowing making an early diagnosis of AAS abuse in patients [2].

References

1. van Amsterdam J, Opperhuizen A, Hartgens F. Adverse health effects of anabolic-androgenic steroids. *Regul Toxicol Pharmacol.* 2010; 57: 117-123.
2. Walker J, Adams B. Cutaneous manifestations of anabolic-androgenic steroid use in athletes. *Int J Dermatol.* 2009; 48: 1044-8.