

Case Report

The Anatomy Specimen Collection of Albert Gellért: A Unique Paraffin Wax Method of Body Preservation

Mihály A*, Weiczner R, Süle Z and Czigner A
 Department of Anatomy, University of Szeged, Hungary

*Corresponding author: Mihály A, Department of Anatomy, University of Szeged, H-6724 Szeged, Kossuth L. sgt. 40, Hungary

Received: June 03, 2014; **Accepted:** August 08, 2014;

Published: August 12, 2014

Human gross anatomy is based on cadaver dissection. Cadavers must be conserved before dissection [1]. Embalming methods are numerous and used in anatomy teaching and research [2,3]. However, most of the fluid embalmed specimens require special storage conditions, therefore long-term storage of these specimens is relatively expensive. We have several methods for long-term preservation which include fluid embalming [3] and the embedding of the tissue into solidifying-polymerizing media [4]. These embedding methods result in compact and durable specimens which can be arranged in collections and contribute to medical databases. One of these popular preservation methods is plastination [4].

Another method of manufacturing durable anatomical specimens was the waxwork modeling: cadaver preparations were used for moulding their structures and the moulds were filled with wax. The wax models were stained and polished [5]. The beautiful and demonstrative specimens were made by skilled anatomists and artists and the specimens were arranged in anatomical museums [5]. Most outstanding collections were made in Italy [5] and Austria [6].

Here we describe a more than 70 years old method, invented by professor Albert Gellért [7]. Gellért used paraffin wax but not for moulding, rather for infiltration and conservation of the body. This method was applied to dissected preparations of whole bodies, limbs, visceral organs and brain [7-9]. The cadavers were carefully prepared and then embedded into paraffin, similarly to tissue blocks in routine histology. The specimens were systematically arranged into a collection, which is now known as the, "Albert Gellért Anatomical Collection" in the Department of Anatomy, University of Szeged, Hungary [10]. The original method was based on the following steps:

1. Cadavers and organs were fixed in 4% aqueous formalin by means of intravascular perfusion and immersion. The intravascular perfusion was performed through the common carotid- and/or femoral arteries, similarly to other embalming procedures. The time of the immersion fixation depended on the size and weight of the cadaver, or body part; varied from 5 days to 5 weeks. In case of blood vessel preparation, the vessels were filled with celluloid dissolved in acetone before the fixation.

2. The cadaver was cut into pieces according to the dissection aim, and dissected *lege artis*. The dissections aimed to demonstrate the anatomy and topography of muscles, nerves and blood vessels of

the body part or organ. Following dissection, a further immersion fixation step followed in freshly prepared 4% aqueous formalin, for 1-2 weeks.

3. The dissected piece was dehydrated in ascending ethanol series (50% I-70%-96%). The 96% ethanol contained 5% phenol. The time of the dehydration depended on the size of the organ (varied from 3 days to 3 weeks), and the ethanol concentration was controlled several times; if it was necessary, the solution was changed. In case of large specimens (e.g. lower limb) the infiltration was facilitated through injecting the chemical into the deep tissues (e.g. muscles).

4. Infiltration with mixture of 96% ethanol, phenol and benzine (mixture of alkanes: pentane, hexane, heptane; cleaning benzine).

5. Infiltration with pure benzine, twice changed.

6. Infiltration with low melting point paraffin (at 36-48°C).

7. Infiltration with high melting point paraffin (at 56°C).

8. Dropping off the surplus paraffin at 56°C.

9. Hardening of the preparations at room temperature.

10. Organs with smooth surface (e.g. stomach, kidney, liver) are finished after hardening. Muscle surfaces were smoothed with a hot iron.

11. Painting the muscles, nerves, blood vessels and covering the specimen with varnish.

12. Many specimens were mounted on wooden and metal supports, for easy handling and display on museum racks.

The fixation and infiltration procedures were done on room temperature [7,8,9]. Instead of benzine, benzene (benzol) was tried, too [8]. In the case of the brain, turpentine was also used in some specimens instead of benzine [9]. Paraffin infiltration of large specimens required a special vacuum thermostat [8]. The thermostat controlled the temperature, the vacuum inside, and reduced the time of the paraffin infiltration [8]. The thermostat was built by local craftsman. Due to the prolonged dehydration the volume of the bodies decreased [8]. The benzine-paraffin infiltration caused further shrinkage [8]. The shrinkage during the entire procedure is larger than that occurring during plastination (Table 1 & 2). This difference

Table 1: Shrinkage of the tissues during the Gellért-paraffin embedding [8,9].

Treatment	Shrinkage of the brain (volume after fixation is 100%) [8,9]	Shrinkage of peripheral tissues (skeletal muscle). Volume after fixation is 100% [8]
Dehydration in ethanol	16.9 %	16 %
Dehydration in acetone	27.2 %	9 %
Benzine-paraffin infiltration	28 %	31 %
Benzol-paraffin infiltration	40.3 %	36 %

Table 2: Shrinkage of tissues during plastination [11,13,14].

Treatment	Shrinkage of the brain [11,13]	Shrinkage of peripheral tissues (kidney). Area measurements of kidney slices; fixed tissue area is 100% [14].
After dehydration in acetone	not measured	10.21 %
After impregnation with silicon polymer	6.96 % [11] 10 % [13]	19.72 %

was probably due to the fact, that infiltrations during plastination happen at low temperatures [4], whilst infiltrations during paraffin embedding were done on room- and higher temperatures [8,9]. This temperature dependence of the shrinkage was clearly demonstrated in brain plastination by Sora et al. [11], in case of heart, kidney, liver and testis plastination by Brown et al. [12].

The volume shrinkage of the tissues due to dehydration was 10-40% during the Gellért-method (Table 1 & 2). The shrinkage was smaller when acetone was used instead of ethanol for dehydration [9]. The shrinkage is larger in the brain, than in peripheral tissues (e.g. skeletal muscle; Table 1). The explanation of the large-scale brain shrinkage is probably the large lipid content which was dissolved during the dehydration and benzine-paraffin infiltration [9]. In general, the range of the volume changes are larger than those obtained during plastination (Tables 1 & 2). The shrinkage of the brain at the end of paraffin embedding was approx. 40% [8,9]. Compared to this, the volume loss of the brain after plastination is only 8-10% [11,13]. The difference was probably due to the low temperatures used during the plastination; at low temperature (-20°C;-25°C) the acetone or ethanol treatment extracted mostly the water, and did not dissolve the lipids from the tissue [11].

The specimens were prepared and kept differently, according mostly to the aims of anatomy teaching. In the "Albert Gellért Anatomical Collection" we have syndesmology specimens: the bones, the ligaments, the articular capsule and related structures are shown (Figure 1). We have a large number of myology specimens, where muscles and muscle groups (with skeletal elements) are visible

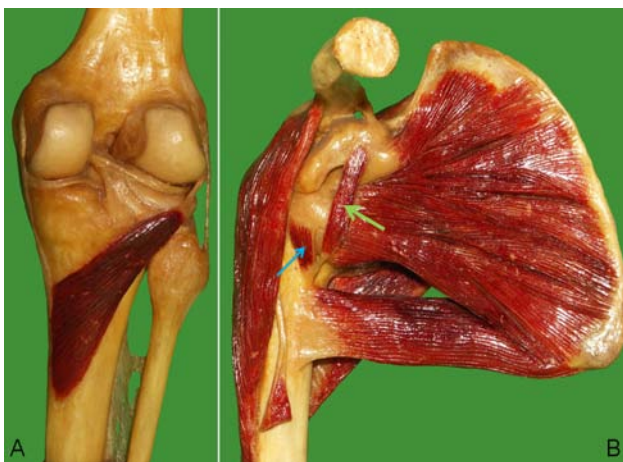

Figure 1A: The knee joint: posterior view with the popliteus muscle. Ligaments and menisci are visible.

Figure1B: Deltoid, teres major and subscapularis muscles. The tendon of the long head of the biceps and a coracobrachialis superior muscle [16] (green arrow) are visible. A small articular muscle of the shoulder joint is visible, too (blue arrow).

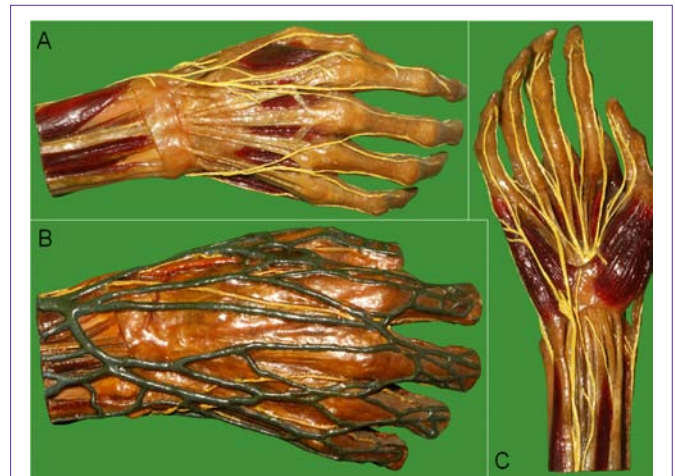

Figure2A: Dorsal branch of the ulnar nerve and the superficial branch of the radial nerve with dorsal digital branches are yellow. The dorsal carpal tendons, the dorsal interossei (brown colour) and the extensor retinaculum are visible, too.

Figure 2B: The dorsal venous network of the hand (blue) together with the skin nerves.

Figure 2C: The palmar muscles (brown), the flexor retinaculum, the ulnar nerve and branches of the median nerve (yellow) are visible. The palmar digital nerves innervating the finger-edges are clearly seen.

(Figure 1). Some anatomical variations can be studied, too (Figure 1). We have paraffin-embedded organs: hearts, kidneys, genital organs, alimentary organs, respiratory organs and brains. We have topographical anatomy specimens in which nerves, blood vessels, ganglia are shown together with muscles and organs (Figures 2 & 3). We have embryology preparations: placentas embedded in paraffine (Figure 4). The collection also includes the adult male-, female- and infant torsos (head and upper trunk), in order to display the characteristic body shape and proportions. We have one pathology preparation: an infant with hydrocephalus (Figure 4).

There are ethical debates in connection of plastinated bodies: the origin of the bodies and the artistic display have been debated several times [15]. We do not discuss these issues. We have document archives which prove that Gellért made precise lists (from 1922 until 1947) about the dead which entered the Anatomy Department: these dead bodies were from hospitals of Szeged and from towns around, the Szeged prison and the Forensic Pathology Department of the University. The name, date of birth, diagnosis, place and cause of the death were registered, too. During these times (1922-1947), no written consent was needed for the anatomical dissection. The hand-written register of the dissected bodies is kept in the archives of the Anatomy Department. The paraffinized specimens are numbered, and registered in hand-written documents, too. In these, the name of the dead, the date of preparation and the name of the preparator are recorded; and the register is kept in the archives of the department. With help of these documents the history of each specimen (made between 1928 and 1947) can be traced back. The paraffin embedding method did not result in artistic forms and appearances. The preparators did not colour the skin (Figure 4), and did not attempt to mimic any lively conditions, postures; therefore, no ethical issues can be raised against them.

Teaching and research in gross anatomy requires cadaver

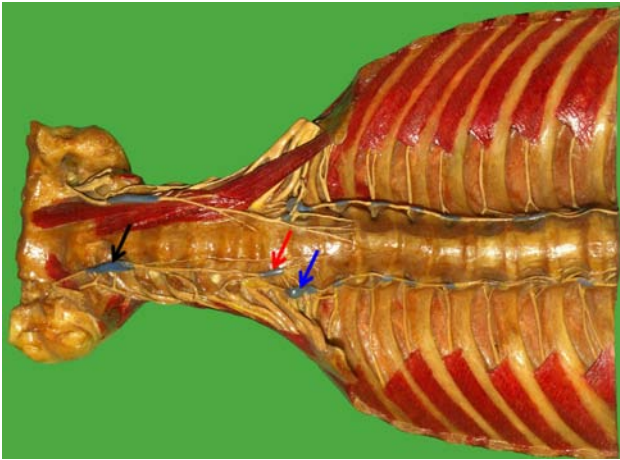


Figure 3: The torso of the skull, vertebral column and rib cage with some muscles and the sympathetic trunk. The ganglia are bluish-grey, nerves are yellow, muscles are brown. The superior cervical ganglion (black arrow), middle cervical ganglion (red arrow) and stellate ganglion (blue arrow) are visible. The cervical- and brachial plexuses and intercostal nerves are visible, too. The left anterior scalenus muscle, the longus capitis and longus colli muscles were prepared.

preparations and their demonstrative documentation. Preservation of the dissected specimen is important, too. The Gellért-method of paraffin embedding of the human bodies resulted in a regimen of spectacular anatomy preparations. The present number of preparations stored in the museum of the Department is almost 500. The fine anatomical details are visible on these preparations. The preparations are especially suitable for the study of muscles: the attachments, the layers and the fasciculation of the muscles are clearly visible (Figures 1-3). The method gives a real image of the nerves, ganglia and nerve plexuses, too (Figures 2-3). The method is also suitable for the preservation of pathological samples (Figure 4). At present, efforts are directed towards the laser scanning of the specimens. We aim to create a digital/virtual anatomy museum for students, research and postgraduate studies.

Acknowledgement

The photographic artwork was performed by Mr. Z. Imre and Mr. M. Dezső. The publication was supported by the „Albert Gellért’s Memory Non-Profit Foundation” (Szeged, Hungary).

References

1. Thiel W. The preservation of the whole corpse with natural color. *Ann Anat.* 1992; 174: 185-195.
2. Coleman R, Kogan I. An improved low-formaldehyde embalming fluid to preserve cadavers for anatomy teaching. *J Anat.* 1998; 192: 443-446.
3. Eisma R, Lamb C, Soames RW. From formalin to Thiel embalming: What changes? One anatomy department’s experiences. *Clin Anat.* 2013; 26: 564-571.
4. Riederer BM. Plastination and its importance in teaching anatomy. Critical points for long-term preservation of human tissue. *J Anat.* 2014; 224: 309-315.

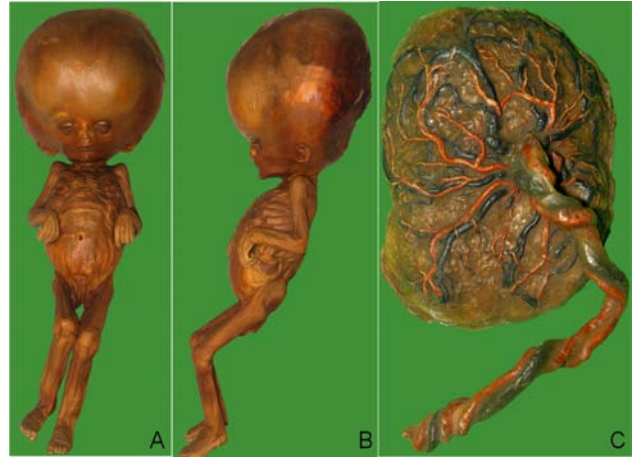

Figure 4A,B: This is a hydrocephalus in a 1 year old female infant, the body was embedded in paraffin. Preparation was made in 1948.

Figure 4C: Normal placenta embedded into paraffin. The umbilical cord and the ramifications of the umbilical vessels are clear on the fetal surface (umbilical vein: blue; umbilical arteries: red).

5. Maraldi NM, Mazzotti G, Cocco L, Manzoli FA. Anatomical waxwork modeling: the history of the Bologna anatomy museum. *Anat Rec.* 2000; 261: 5-10.
6. Sedivy R. Pathoanatomical museum of Vienna. *Virchows Arch.* 2011; 458: 357-358.
7. Gellért A, Bacsich P. Museum specimens prepared by paraffin impregnation. *J. Anat. (Anatomical Society of Great Britain and Ireland Proceedings).* 1936; 71: 139-140.
8. Gellért A. Anwendung der Paraffintechnik bei der Herstellung anatomischer Präparate. *Studia Medica Szegedinensia.* 1971; 8: 7-21.
9. Gellért A. Versuche zur Paraffin-Imprägnation von Gehirn Präparaten. *Acta Morph. Acad. Sci. Hung.* 1959; 8: 381-389.
10. Csillik B, Martin AW. The Szeged Anatomical Collection. A private publication of Martin AW. New Malden, Surrey. 1991. ISBN 0 951691201.
11. Sora M-C, Brugger P, Traxler H. P40 plastination of human brain slices: comparison between different immersion and impregnation conditions. *J. Int. Soc. Plastination.* 1999; 14: 22-24.
12. Brown MA, Reed RB, Henry RW. Effects of dehydration mediums and temperature on total dehydration time and tissue shrinkage. *J. Int. Soc. Plastination.* 2002; 17: 28-33.
13. Suriyapradilok L, Withyachumnarnkul B. Plastination of stained section of the human brain: comparison between different staining methods. *J. Int. Soc. Plastination.* 1997; 12: 27-32.
14. Pereira-Sampaio MA, Marques-Sampaio BP, Sampaio FJ, Henry RW. Shrinkage of renal tissue after impregnation via the cold Biodur plastination technique. *Anat Rec (Hoboken).* 2011; 294: 1418-1422.
15. Jones DG. Using and respecting the dead human body: An anatomist’s perspective. *Clin Anat.* 2014.
16. Bergman RA, Thompson SA, Afifi AK. *Catalog of Human Variation.* Baltimore, Munich: Urban & Schwarzenberg. 1984.