

## Research Article

# Can An Embolectomy Catheter Become a One Stop Solution for Lung Isolation in One Lung Ventilation?

Jain A\*

Department of Anesthesiology, Gandhi Medical College, Bhopal, Madhya Pradesh, India

**\*Corresponding author:** Anuj Jain, Department of Anesthesiology, Gandhi Medical College, Bhopal, Madhya Pradesh, India**Received:** July 03, 2020; **Accepted:** August 13, 2020;**Published:** August 20, 2020**Abstract**

One Lung Ventilation (OLV) is often required for surgeries in the thorax; patients may belong to any age group. If the patients are adult, the options for lung isolation are many, but handicap arises when one is dealing with paediatric patients. While dealing with pediatric patients, Embolectomy Catheters (EC) may be quite useful as they are available in a wide range of sizes, making them appropriate for lung isolation even in neonates. Besides, ECs can be improvised to achieve selective lobar separation in patients who have borderline lung function and are at risk for intraoperative hypoxemia. Though EC is a versatile device, it is underutilized; only a few low-quality pieces of evidence are available. Among the people who have used ECs for lung isolation, the technique of insertion had been variable. This article is an attempt to review the methods of lung isolation and explore the possibility of EC becoming a universal device for lung isolation.

**Background**

One Lung Ventilation (OLV) is usually indicated in thoracic, oesophageal, vascular and non-thoracic surgical settings in peri-operative period. A variety of surgeries require OLV; an indication can be to improve the exposure of intrathoracic structures or to prevent soiling of the healthy lung with contaminant from the affected lung.

Now a days, Embolectomy Catheters (ECs) are becoming more popular for One Lung Ventilation (OLV) because of their easy availability even in resource limited health care facilities. The purpose of this review is to provide an update on emerging evidence and defining the role of ECs in OLV, both in paediatric and adult patients.

**Challenges of OLV in paediatric patients and available lung isolation techniques**

OLV in paediatric patients is a challenge to all anaesthesiologists; smaller the airway, greater is the challenge. Antero-Posterior (AP) diameter of a neonatal trachea, in both males and females is just 4.3mm; at 15 years, the size increases to 14mm in both sexes, thereafter the trachea in female stops growing, while in males it grows to a size of 16-18mm at 19years (Table 1).

In adults, the Lung Isolation Techniques (LITs) most commonly used are Double Lumen Tubes (DLTs); less common options include, Bronchial Blockers (BB), Univent Tubes (UT), and Embolectomy Catheters (EC).

**Double lumen tube:** DLT is most popular, but it is not available below 26 Fr [1]. A generic interpretation of a 26Fr DLT is two 4mm ETTs joined together, implying thereby that in order to accommodate even the smallest DLT the tracheal diameter has to be more than 8mm and the bronchial diameter has to be more than 4mm. So, a DLT is fit for paediatric patients of age more than 8 years, weighing more than 30kg or height more than 130 centimeters; recommended size varies with age and human race too [2]. According to Brodsky, appropriate size of DLT may be determined either by direct

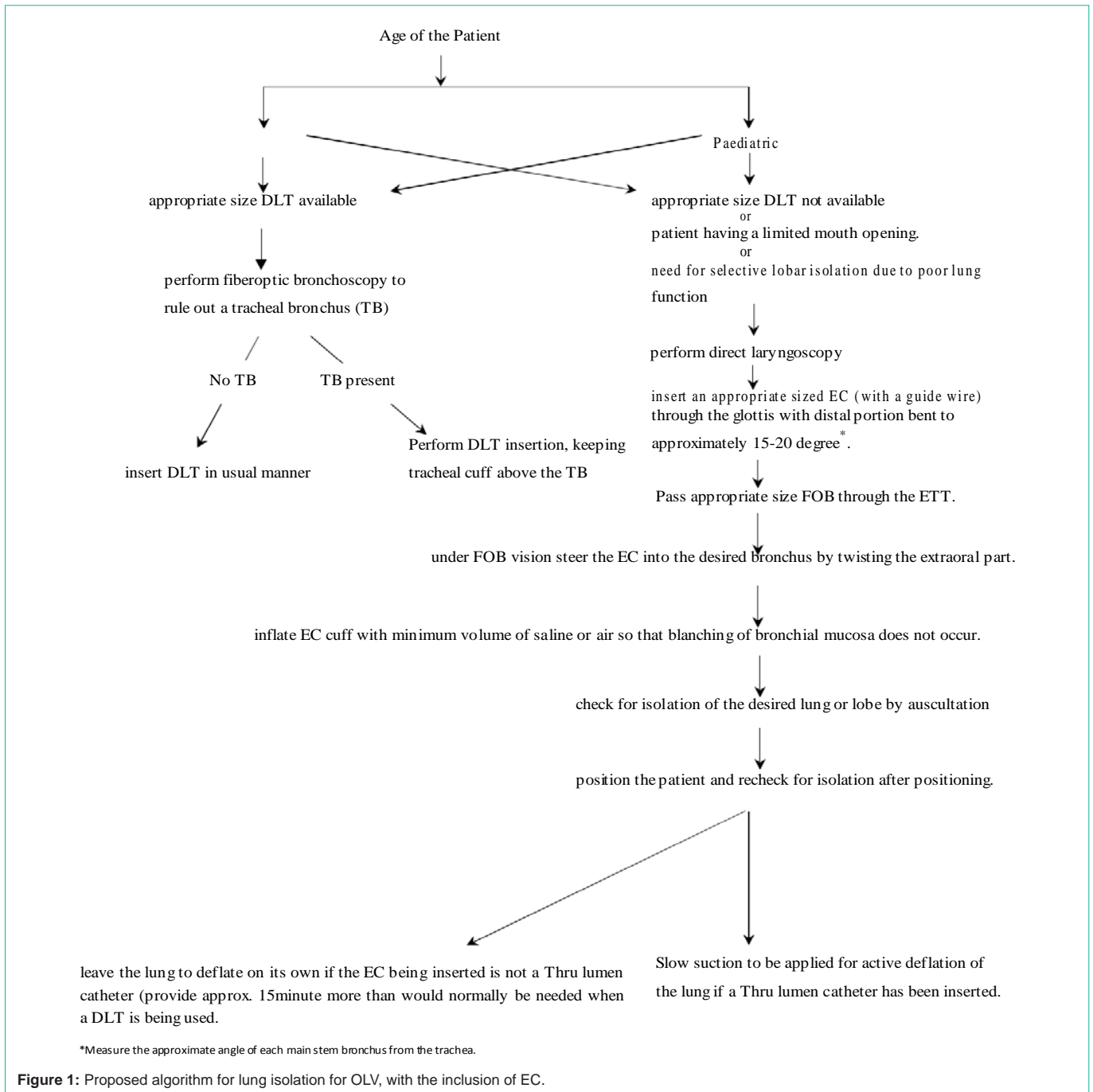
measurement of bronchial diameter in a chest radiograph or by predicting left Bronchus Diameter (BD) based on Tracheal Diameter (TD) according to the formula,  $LBD=(0.4 \times TD)+3.3$  [3].

**Marraro-bilumen tube:** These bilumen tubes can be used in smaller paediatric patients; smallest tube is made of two 2.0 mm tubes molded together. The sizes may go up to two 3-3.5mm tubes molded together, making it appropriate for 2-3 years age group. Although Marraro tubes may be used in neonates, it is usually unavailable and most anaesthesiologists are unaware that such tubes even exist.

**Univent Tube (UT):** A UT with an Internal Diameter (ID) of 3.5mm has an External Diameter (ED) of 7.5-8.0mm, while the one with 4.5mm ID have an ED of 8.5-9.0mm. The large ED limits its use in Asian paediatric population smaller than 4-6years of age [4].

**Bronchial blockers:** Arndt's BB are available in 5,7 and 9Fr and are appropriate for 6month to 6 years, 6 years to 14 years and 14-18 years age groups respectively [5]. BBs have a low pressure cuff and a coaxial channel for suctioning, which allows active deflation of lung. Apart from its high cost and less availability, the major disadvantage of BBs is that the loop guide wire (which is essential for placement) once removed cannot be reinserted, rendering it useless if need for repositioning arises. In a RCT by Narayanaswamy, the misplacement rate of Arndt's blocker (the most popular among the 3 BBs) was higher compared to other two BBs [6].

**Endobronchial Single Lumen Tube (SLT):** SLTs can be used for lung isolation in emergency situations like contralateral pneumothorax [7]. Some anaesthesiologists also insert two SLTs, one in trachea and other in the bronchus. Endobronchial SLT has a tendency to progress to the right side due to the more inline orientation of the right bronchus. It can be of concern, if surgery needs to be performed in the right hemithorax. In order to overcome this problem, Chengod et al., [8]. Suggested left endobronchial intubation using a SLT that was curved towards the left side (with a stylet). However, this approach may not be appropriate up to 2 years of age as the diameter of the left



main bronchus is small to accommodate an appropriate for age SLT (Table 1).

**Embolectomy catheters:** ECs although invented for a different purpose, is a versatile equipment, which can be improvised to effect OLV. EC was invented by Thomas Fogarty in 1963; patent for it was acquired in 1969. EC was first used by Charles Dotter in 1965 for first balloon angioplasty. There are few evidences in scientific literature to suggest the use of ECs for OLV but the technique of EC insertion varies in most of the cases with no consensus regarding the method of insertion (Table 2). ECs come in a variety of sizes; 2 and 3Fr ECs,

do not have a guidewire in them (hence, lack the required stiffness), making it difficult to steer them for endobronchial placement. ECs of higher sizes have a guidewire and may be used for lung isolation. For OLV, EC is usually used in conjunction with ETT, but may be used along-with DLTs also.

**Technical review of the ECs as LITs: LITs have used in various ways, but the quality of evidence regarding its use still remains poor**

**Co-axial vs Parallel techniques:** ECs may be passed coaxially in the ETT or may be passed externally, parallel to the ETT; choice

**Table 1:** Age wise dimensions of the airways as by Szelloe et al [17], in comparison with calculated size of ETT.

Age(yr)	Smallest Mean AP TD (mm)	Mean Right BD (mm)	Mean Left BD (mm)	Predicted size of cuffed endotracheal tube=[3.5+age(yr)/4]mm
0-1	6.0 (2.9-7.7)	3.9 (2.4-6.0)	3.4 (2.1-5.7)	3.5
1-2	7.0 (4.3-9.2)	4.9 (3.8-7.5)	4.2 (2.7-6.6)	4
2-4	7.9 (4.1-10.3)	6.1 (3.0-7.9)	5.5 (2.7-8.5)	4-4.5
4-6	7.5 (5.1-10.9)	6.1 (4.4-7.8)	5.3 (4.1-6.6)	4.5-5.0
6-8	8.8 (5.7-11.0)	6.8 (4.3-9.0)	6.0 (4.5-10.1)	5.0-5.5
8-10	9.5 (7.4-12)	7.0 (5.5-9.4)	6.6 (4.9-9.1)	5.5-6.0
10-12	10.8 (10.2-15.8)	8.2 (6.6-10.0)	7.5 (5.6-11.1)	6.0-6.5
12-14	11.7 (10.3-15.8)	8.5 (7.3-10.5)	8.1 (6.5-10.0)	6.5-7
14-16	13.0 (8.9-16.8)	9.8 (6.5-12.7)	9.2 (6.2-11.5)	

**Table 2:** Literature review with regards to use of Embolectomy catheters in lung isolation.

S.no	Author	TOP	YOP	Region	E or I	ToS	Age	Size of EC (in F)	FOB used	Lung isolated
1	Amar et al [18]	CR	2001	USA	E, I	Esophageal surgery	A	8	Y	R
2	Asai et al [19]	CR	2000	Japan	I	Lung Surgery	P	3	Y	L
3	Kamra et al [20]	CS (N=27)	2017	India	E	Lung surgery	P	Variable	Y	
4	Bakshi et al [21]	CR	2013	India	E	Lung surgery	P	3	Y	R
5	Shimamoto et al [22]	CR	2004	Japan	I	Lung surgery	P	4 (Through lumen)	Y	L
5	Ho et al [23]	CS N=10	2008	China	E, I	Lung surgery, Mediastinal surgery, Thoracic Spine surgery, Oesophageal surgery.	P	5-Mar	Y	R(4) L(6)
6	Mohan v et al [24]	CR	2002	India	I	Lung	P	5	Y	L
7	Baidya et al [25]	CS (N=4)	2015	India	E	Lung	P			R(2) L(2)
8	Vretzakis et al [26]	CS (N=61)	2005	Greece	I	Lung	A	4,5	Y	R(selective right upper lobe)
9	Umoroglu et al [27]	CR	2017	Turkey		Lung lavage	P		Y	L
10	Peeters et al [28]	CR	2015	Belgium	I	Lung surgery	P	3	Y	L
11	Sharma et al [29]	CR	2014	India	I	Lung surgery	A	4	Y	R (middle lobe)
12	Cho et al [30]	CR	2010	Korea	E	Lung surgery	P	3	Y	R
13	Sutton et al [31]	CS (N=11)	2012	USA	E	Ling surgery	P	5	Y	R(3) L(8)
14	Chaitanya et al [32]	CR	2016	India	E	Lung surgery	P	4	Y	L
15	Mathews and Sanders [33]	CR	2001	UK	I	Lung surgery	A	5	y	R
16	Morikawa et al [34]	CS (N=3)	2002	Japan	I	Lung surgery	A	5	Y	R and L

**Abbreviations:** CR: Case Report; CS: Case Series; N: Number of Patients; YOP: Year of Publication; E: Extraluminal; I: Intraluminal; TOS: Type of Surgery; A: Adults; P: Paediatric; Y: Yes; N: No; R: Right; L: Left.

depends on relative size of ETT and EC. Ho et al., passed EC both extra and intraluminal to the ETT; in wider ETT (ID, more than 4.5mm) the stem of EC was passed intraluminal and the distal end was made extraluminal through the murphy eye [9]. In thinner ETT, the stem of the EC was extraluminal and distal end became intraluminal through the murphy eye. When the distal end was made intraluminal, the bevel of the ETT was trimmed obliquely to decrease the resistance to gas flow; this practice needs to be questioned, due to the safety concerns that may arise. Asai et al., made a hole in the ETT near the connector end and passed a 3F EC through it [19]. This practice, seems good in the absence of proprietary three way airway connector, may become problematic if the EC size needs to be changed and more so it can used only with wider diameter ETTs. Sutton et al [30]. Successfully used EC extraluminally in 9 patients, of age less than 6months. Mohan et al. [23], tried using a 5F EC

extraluminally and had to abandon the procedure as they could not negotiate the EC “smoothly”. They succeeded when they tried putting the EC intra-luminally. Park et al., inserted EC for lung isolation in adult patients with subglottic stenosis; they passed the EC within the tube [10].

Important consideration while deciding whether to put EC, intra or extraluminally is the size of EC relative to the size of ETT; care should be taken not to occlude more than 50% of the cross sectional area (i.e. 70% of the diameter) of the ETT. However, occlusion of even 50% CSA may compromise ventilation and oxygenation in relatively sick patients. As seen in Table 2, the balloon diameter of a EC (Fogarty Catheter - Edwards Life sciences, Irvine, CA, USA) can vary anywhere from 1.4 mm to 14 mm, thereby making it appropriate for even the smallest of the airways. Since the diameter of EC is also small compared to the ETT, it is less likely to cause any obstruction/

**Table 3:** Dimension of Fogarty EC along with the dimension of its balloon in deflated and inflated state.

Catheter size (Fr)	Diameter of catheter body(mm) Size in Fr/3=size in mm	Inflated balloon diameter (mm)	Deflated balloon diameter(mm)
3	1	5	1.4
4	1.33	9	1.67
5	1.66	11	2
6	2	13	2.3
7	2.33	14	2.66

alteration to airflow. According to our experience, passing the EC extraluminally although not as smooth as passing it intra-luminal, does give two important advantages. Firstly, unlike the intraluminal approach, this approach need not be changed according to size of the ETT. Secondly, ETT cuff when inflated anchors the EC in position, preventing misplacement of EC; besides, no specialized three-way airway adapter is required.

Kamra et al., [11] successfully used a rigid bronchoscope to guide EC placement for OLV. Rigid bronchoscopy would require a deep plane of anesthesia which may not be appropriate when anticipating a difficult airway situation. More so, rigid bronchoscope is unavailable in the airway armamentarium of anesthesiologist. Mathews et al., achieved OLV by inserting EC in a tracheotomised patient, through the tracheostomy tube [32].

**Utility of ECs in unconventional situation:** EC may provide added advantage in conditions where the lung functions are compromised. Morikawa et al. [33], inserted two 8F ECs, in order to obtain selective lobar collapse in 3 patients, who had a poor lung function. Vretzakis et al., evaluated oxygenation in patient undergoing right lung surgery with DLT in situ and found that 13.7 percent patients had oxygenation problem during OLV [25]. Out of these, oxygenation issues could be resolved with conventional techniques only in 50 percent patients; other half of the patients were managed with selective lobar ventilation preserving strategy. In order to achieve this, they passed EC through the tracheal lumen of DLT and selectively blocked bronchial opening (upper lobe ventilation was preserved by them, in all the cases).

**Bent vs straight ECs:** Ramakrishna et al., bent the tip of EC to make it steerable into one of the bronchus [31]. In our practice, we have also found the techniques of bending the distal part of EC useful, in cases requiring selective lobar isolation. We have proposed in detail, the techniques of OLV using a EC in Figure 1. The other authors did not describe whether they bent the EC or not.

**EC insertion, whether FOB guidance is necessary:** As per available literature, all the users (Table 3), placed EC under FOB guidance, except Munir et al., [12] who considered FOB guided placement optional. In our view, performing bronchoscopy is mandatory in all the cases of lung isolation, firstly, to rule out a tracheal bronchus [13] and secondly, inserting an EC blindly with a stylet predisposes the airway to injury [14,15].

**Disadvantages of ECs:** ECs although versatile, also have certain important disadvantages. Since ECs, have low volume and high-pressure cuffs they are likely to cause mucosal ischemia if inflated at high pressure for prolonged duration.

**EC with a hollow core:** Commonly available ECs, do not have

a hollow core and cannot be used for active deflation of the lung. ECs having a hollow core are available, they are called as Fogarty Thru-Lumen embolectomy catheter (Edwards Life Sciences, Irvine, CA, USA). Shimamoto et al., [16] used a thru lumen EC and used it successfully to aspirate blood and sputum from the blocked lung. Based on the available literature,

ECs with or without a thru lumen seems to be the most versatile among all the LITs, especially in paediatric patients.

## Conclusion

The omnipresence of ECs in health care facilities and, a wide range of available sizes make ECs suitable to be used for OLV in pediatric patients. When inserted parallel to the ETT (extraluminally) and guided by flexible fiberscope, they can be used without any specialized adapters. Specialized adapters shall be required if the EC is inserted intraluminally. Chances of misplacement of an EC inserted parallel to the ETT are comparatively lower, as the cuff of the ETT tends to keep the catheter body pressed against the tracheal wall, thereby reducing telescoping and misplacements. The problem of delayed lung deflation can be resolved by using the thru lumen ECs or by allowing extra time for lung deflation to occur by resorption. Though, there is no high-grade scientific evidence of EC's clinical use in OLV, but, author's experience of using ECs in OLV has been excellent, and there is low-grade scientific evidence also to suggest their use in OLV especially in the setting of where situations necessitating selective lobe isolation, to improve oxygenation. Therefore, we can conclude that because of their omnipresence in health care facilities, cheapness, and versatility in terms of different sizes, the ECs have excellent potential to become one stop solution for OLV. However, the authors also suggest that there should be a high powered Randomized control trial study (feasibility of such a study is trying) to generate high-grade scientific evidence.

## References

1. M Letal, M Theam. Paediatric lung isolation. BJA Education. 2017; 17: 57-62.
2. Chow MY, Liam BL, Lew TW, Chelliah RY, Ong BC. Predicting the size of a double-lumen endobronchial tube based on tracheal diameter. Anesth Analg. 1998; 87: 158-60.
3. Brodsky JB, Lemmens HJ. Left double-lumen tubes: Clinical experience with 1,170 patients. J Cardiothorac Vasc Anesth. 2003; 17: 289-98.
4. Hammer GB, Brodsky Jb, Redepath JH, Cannon WB. The Univent tube for single-lung ventilation in paediatric patients. Paediatr Anaesth. 1998; 8: 55-7.
5. One lung ventilation & bronchial blocker guideline. 2019.
6. Narayanaswamy M, McRae K, Slinger P, Dugas G, Kanellakos GW, Roscoe A, et al. Choosing a lung isolation device for thoracic surgery: A randomized trial of three bronchial blockers versus double-lumen tubes. Anesth Analg. 2009; 108: 1097-101.
7. Baraka A, Dajani A, Maktabi M. Selective contralateral bronchial intubation

- in children with pneumothorax or bronchopleural fistula. *Br J Anaesth.* 1983; 55: 901-4.
8. Chengod S, Chandrasekharan AP, Manoj P. Selective left bronchial intubation and left-lung isolation in infants and toddlers: analysis of a new technique. *J Cardiothorac Vasc Anesth.* 2005; 19: 636-41.
  9. Ho AM-H, Karmakar MK, Critchley L a. H, Ng SK, Wat C-Y. Placing the tip of the endotracheal tube at the carina and passing the endobronchial blocker through the Murphy eye may reduce the risk of blocker retrograde dislodgement during one-lung anaesthesia in small children†. *British Journal of Anaesthesia.* 2008; 101: 690-3.
  10. Park HP, Bahk JH, Park JH, Oh YS. Use of a Fogarty catheter as a bronchial blocker through a single-lumen endotracheal tube in patients with subglottic stenosis. *Anaesth Intensive Care.* 2003; 31: 214-6.
  11. Kamra SK, Jaiswal AA, Garg AK, Mohanty MK. Rigid Bronchoscopic Placement of Fogarty Catheter as a Bronchial Blocker for One Lung Isolation and Ventilation in Infants and Children Undergoing Thoracic Surgery: A Single Institution Experience of 27 Cases. *Indian J Otolaryngol Head Neck Surg.* 2017; 69: 159-71.
  12. Muhammad A. Munir, Jehad I. Albataineh, Muhammad Jaffar. An Alternative Way to Use Fogarty Balloon Catheter for Perioperative Lung Isolation. *Anesthesiology.* 2003; 99: 240.
  13. Lee DK, Kim YM, Kim HZ, Lim SH. Right upper lobe tracheal bronchus: anesthetic challenge in one-lung ventilated patients -A report of three cases-. *Korean J Anesthesiol.* 2013; 64: 448-50.
  14. Schwartz DE, Yost CS, Larson MD. Pneumothorax complicating the use of a Univent® endotracheal tube. *Anesth Analg.* 1993; 76: 443-5.
  15. Campos JH. An Alternative Way to Use Fogarty Balloon Catheter for Perioperative Lung Isolation. *Anesthes.* 2003; 99: 241-241.
  16. Use T, Shimamoto H, Fukano T, Sumikawa K. Single lung ventilation in a pediatric patient using a Fogarty catheter with a hollow center. *Masui.* 2004; 53: 69-71.
  17. Szelloe P, Weiss M, Schraner T, Dave MH. Lower airway dimensions in pediatric patients-Acomputed tomography study. *Pediatr Anesth.* 2017; 00: 1-7.
  18. Amar D, Desiderio DP, Bains MS, Wilson RS. A Novel Method of One-lung Isolation Using a Double Endobronchial Blocker Technique. *Anesthes.* 2001; 95: 1528-30.
  19. Asai T, Ikeda S, Shingu K. Insertion of a Fogarty Catheter through an Endotracheal Tube for One-lung Ventilation: A New Method. *Anesthes.* 2000; 93: 909-909.
  20. Kamra SK, Jaiswal AA, Garg AK, Mohanty MK. Rigid Bronchoscopic Placement of Fogarty Catheter as a Bronchial Blocker for One Lung Isolation and Ventilation in Infants and Children Undergoing Thoracic Surgery: A Single Institution Experience of 27 Cases. *Indian J Otolaryngol Head Neck Surg.* 2017; 69: 159-71.
  21. Bakhshi RG. One Lung Ventilation Using Fogarty's Catheter in a Case of Bronchial Tear. *Bombay Hospital Journal.* 2009; 51: 547-548.
  22. Use T, Shimamoto H, Fukano T, Sumikawa K. [Single lung ventilation in a pediatric patient using a Fogarty catheter with a hollow center. *Masui.* 2004; 53: 69-71.
  23. Ho AM-H, Karmakar MK, Critchley L a. H, Ng SK, Wat C-Y. Placing the tip of the endotracheal tube at the carina and passing the endobronchial blocker through the Murphy eye may reduce the risk of blocker retrograde dislodgement during one-lung anaesthesia in small children†. *British Journal of Anaesthesia.* 2008; 101: 690-3.
  24. MohanVirender K, Darlong, Vanlal M, KashyapLokesh, MishraSailesh K, Gupta Kalpana. Fiberoptic-Guided Fogarty Catheter Placement Using the Same Diaphragm of an Adapter with in the Single-Lumen Tube in Children. *Anesthesia & Analgesia.* 2002; 95: 1241-1242.
  25. Baidya DK, Pawar DK, Maitra S, Bajpai M, Panda SS. Novel Maneuver for Endobronchial Fogarty Embolectomy Catheter Placement for Lung Isolation in Infants: An Experience of Four Cases. *Eur J Pediatr Surg.* 2015; 25: 541-3.
  26. Vretzakis G, Dragoumanis C, Papaziogas B, Mikroulis D. Improved oxygenation during one-lung ventilation achieved with an embolectomy catheter acting as a selective lobar endobronchial blocker. *Journal of Cardiothoracic and Vascular Anesthesia.* 2005; 19: 270-2.
  27. Umuroglu T, Altintas M, Abdullayev T, Kiyan G, Ayanoglu HO. An Alternative Lung Isolation Technique in Paediatric Pulmonary Alveolar Proteinosis. *Turkish Journal of Anesthesia and Reanimation.* 2017; 45: 310-2.
  28. Peeters Y, de Velde MV, Neyrinck AP, Vermeulen K. Approach to one lung ventilation during the surgical resection of an intrathoracic ganglioneuroblastoma in a three-year-old child: A case report and review of the literature. 2014; 5.
  29. Sharma A, Sinha S, Mehta Y, Khanna S, Khandelwal S, Khan A. A novel technique to prevent endobronchial spillage during video assisted thoracoscopic lobectomy. *Annals of Cardiac Anaesthesia.* 2014; 17: 164.
  30. Ah Reum Cho, Kyung Hoon Kim, Sang Wook Shin, Jung Min Hong, and Hee Young Kim. Anesthetic management of a neonate with giant bronchopulmonary sequestration. *Anesth Pain Med.* 2010; 5: 351-354.
  31. Christopher J. Sutton, Ayman Naguib, Suvikram Puri, Collin J. Sprenker, Enrico M. Camporesi. One-lung ventilation in infants and small children: blood gas values. *J Anesth.* 2012; 26: 670-4.
  32. K Ramakrishna Chaitanya, P Ravikanth, Suhasini Gazula, Nagarjuna Thakur. Pediatric single lung ventilation for lobectomy: Anesthetic challenge. *CHRISMED Journal of Health and Research.* 2016; 3: 131-133.
  33. Matthews AJ, Sanders DJ. Single-lung ventilation via a tracheostomy using a fiberoptically-directed 'steerable' endobronchial blocker. *Anaesthesia.* 2001; 56: 492-3.
  34. Morikawa T, Sugiura H, Kaji M, Sasamura Y, Okushiba S, Kondo S, et al. Availability of lobe-selective bronchial blockade for video-assisted thoracic surgery. *Surg Endosc.* 2002; 16: 327-30.