

## Clinical Image

# Extranodal NK/T Cell Lymphoma, Nasal Type

David Navarro-Gonzalez MD<sup>1\*</sup> and Arnáez-Solis R<sup>2</sup>

<sup>1</sup>Prehospital Emergency Unit, Navarra Health Service - Osasunbidea, Spain

<sup>2</sup>Department of Internal Medicine, Navarra Health Service - Osasunbidea, Spain

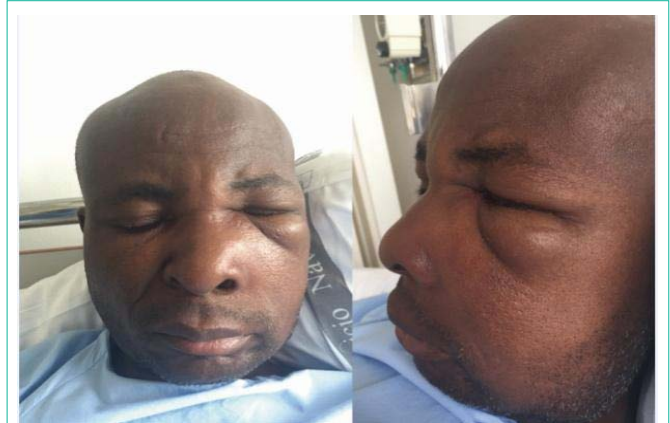\*Corresponding author: David Navarro-González, 18 Teodoro Ochoa de Alda, Pamplona, Navarra, Spain

Received: February 14, 2018; Accepted: March 12, 2018; Published: April 03, 2018

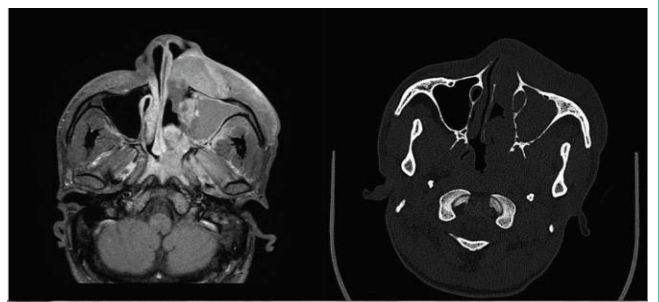
## Clinical Image

Natural killer/T cell Lymphoma, Nasal type (NKTLN), is an extranodal lymphoma, with a poor prognosis due to the late diagnosis and its aggressive behavior. The initial nasal symptoms of NKTLN are unspecific, contributing to the delay of a diagnosis. Rapidly progressive, NKTLN cause destruction of adjacent structures. Multiple biopsies are usually required to establish the diagnosis due to necrosis. The number of new cases has been increasing as a result of a better knowledge of this disease.

A 53 years-old Nigerian man was admitted with 2 months rhinorrhea, nasal obstruction, hemifacial edema and deformity of the nasal pyramid (Figure 1). Computed tomography of the facial bones was performed, completed by magnetic resonance imaging, revealing ethmoid, sphenoid, maxillary and frontal sinuses involvement (Figure 2). The biopsy and immunohistochemical study allowed the diagnosis of NKTLN, related to an Epstein-Barr infection. Combined radiotherapy and chemotherapy type SMILE was administered, with completed radiological eradication.



**Figure 1:** A 53 years-old Nigerian man with nasal obstruction, hemifacial edema and deformity of the nasal pyramid.



**Figure 2:** Paranasal sinuses MRI (right) and Facial bones CT scan (left): Solid mass with infiltrating growth pattern and important local destruction.