

Case Report

Accessory Iris Membrane or Iris Duplication: A Case Report

El Hachimi R*, El Hadiri R, Benchekroun S, El Arari N, Boutimzine N and Cherkaoui LO

Department of Ophthalmology, Speciality Hospital of Rabat, Mohamed V University of Rabat, Morocco

*Corresponding authors: Rim El Hachimi, Department of Ophthalmology, Speciality Hospital of Rabat, Mohamed V University of Rabat, Morocco

Received: November 16, 2021; Accepted: December 08, 2021; Published: December 15, 2021

Abstract

We report a case of 8 years old boy complaining of bilateral reduced visual acuity since birth. Biomicroscopic examination have found a dense accessory iris membrane obstructing pupil. The patient underwent surgical excision (Membranectomy). Our report describes accessory iris membrane and difference between AIM and differences between this congenital iris abnormalities and persistent pupil membrane.

Keywords: Congenital; Accessory membrane; Membranectomy

Case Presentation

We report a case of 8 years old boy complaining of bilateral reduced visual acuity since birth. The patient was otherwise healthy. He had no family history of any ocular pathology and his parents were not consanguineous.

Examination showed: BCVA OD = 0.2, BCVA OS = 0.2 and IOP OU = 14 mmHg. Slit lamp examination revealed OU clear cornea, normally reacting pupillary margin and iris. There were dense strands of tissue attached to the iris collarette along the pupil. In the center of this tissue was a 1 mm diameter pseudopupil incompletely opened (Figure 1). Gonioscopy showed normal structures. Fundus biomicroscopy was impossible to do due to the dens AIM. Ocular echography was normal. We proceed to bilateral surgical membranectomy. Post-operative visual acuity was 0.6 OU. Treatment of amblyopia and optical correction was immediately undertaken.

Discussion and Conclusion

Accessory Iris Membrane (AIM) or iris duplication and Persistent Pupil Membrane (PPM) are congenital iris abnormalities that compromise vision by obscuring the pupil. These two conditions have a quite different clinical appearance [1]. Very few cases of AIM have been reported in literature [2]. AIM closely resembles normal iris tissue in terms of color and thickness and has a second virtual pseudopupil which distinguishes it from PPM which does not have a central pseudo pupil. AIM is confused with extreme tick PPM [3]. PPM can be unilateral or bilateral but AIM seems to appear always bilateral [1].

In cases of accessory iris membrane, the tissue shows an abnormal extensive hyperplasia on histopathological examination, even compared to the pupillary membrane in fetal life [4]. Treatment options of this kind of membranes include mydriatics, Nd:YAG laser therapy and surgical excision (Membranectomy).

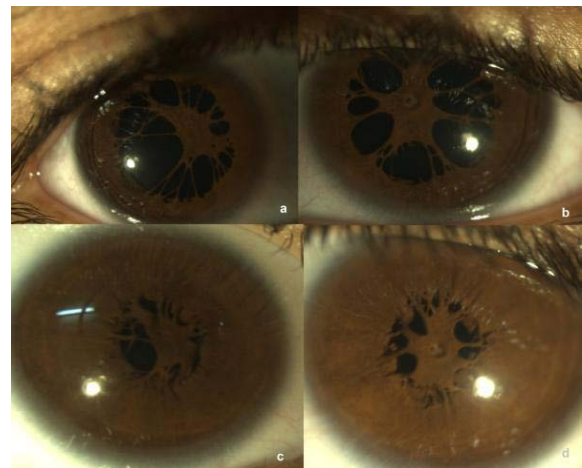


Figure 1: Accessory iris membrane: thick tissue similar to the structure of the iris with dilation (a and b). The pseudopupil is clearly visible in OS (b). Without dilation, the membrane protrudes into the anterior chamber respectively OR (c) and OS (d).

References

1. Monica Gavriş, Ioan Horge, Elena Avram, Roxana Belicioiu, Ioana Alexandra Olteanu and Hanga Kedves. Persistent pupillary membrane or accessory iris membrane? Rom J Ophthalmol. 2015; 59: 184-187.
2. Tasman W, Jaeger E. Duane's ophthalmology. 2007 Ed. Philadelphia: Lippincott Williams & Wilkins. 2007: 24-258.
3. Levy WJ. Congenital iris lesion. British Journal of Ophthalmology. 1957; 41: 120-123.
4. Duke-Elder S. System of Ophthalmology. 1st Ed. London: Henry Kimpton. 1964; 3: 587-775.