

Case Series

Risk Factor of Cataract Formation after Penetrating Keratoplasty

Mrad Khalil*; Serghini Louay; Abdallah El Hassan; Berraho Amina

Department of Ophthalmology B, Ibn Sina Hospital, University Mohamed V, Rabat, Morocco

*Corresponding author: Mrad Khalil

Department of Ophthalmology B, Ibn Sina Hospital, University Mohamed V, Rabat, Morocco.

Email: mradkhalil962@gmail.com.

Received: March 20, 2023

Accepted: May 01, 2023

Published: May 08, 2023

Abstract

Introduction: Post-corneal graft cataract is a not negligible complication. Its occurrence rate varies from 0.4% (2) to 32% (3) according to series, it can present itself in the form of nuclear, cortical and posterior capsular opacities. Its treatment corresponds to a usual cataract surgery by phacoemulsification with implantation in the capsular bag. Our work aims to identify and analyze the risk factors for the development of cataract after keratoplasty.

Materials and Methods: This is an analytical study conducted within the Ophthalmology Service B at the Rabat Specialty Hospital on 58 patients who underwent penetrating keratoplasty. The main criteria studied were: age; sex; indication for surgery and average dose of corticosteroids. Statistical calculations were made using the SPSS 10.0 software for Windows. A p value <0.05 was considered significant. The average follow-up was 24 months.

Results: Cataract after corneal transplantation was observed in 10 cases (17.2%). The mean age at the time of cataract diagnosis was 55 years, with extremes ranging from 40 to 70 years? It developed in 7 of the 33 female cases (21%), and in 3 of the 25 male cases (12%). The onset delay ranged between 16 and 24 months, with a mean delay of 18 months after the penetrating keratoplasty. The most frequent type was nuclear cataract (8 of 10 eyes, 80%), posterior subcapsular cataract developed in one eye (10%) and cortical-nuclear cataract in one eye (10%). It developed in 4 of the 9 cases operated for corneal dystrophies (44.4%), in 3 of the 11 cases operated for sequelae of infectious keratitis (27.2%), in 2 of the 13 cases operated for posttraumatic opacity (15%) and in 1 of the 20 cases operated for keratoconus (5%). In our study, only age and operative indication of the graft were considered as risk factors for the development of cataract after corneal transplantation (p<0.05). The preoperative visual acuity, the patient's sex.

Discussion: Our study provides data on the risk factors of post-corneal graft cataract development in patients of different ages and diagnoses to help surgeons determine an appropriate procedure whether it be penetrating keratoplasty alone or combined with cataract extraction in their patients.

Conclusion: The frequency of post-corneal graft cataract has decreased since the advent of lamellar grafts and the improvement of surgical technique.

Introduction

After Penetrating Keratoplasty (PKP), lens opacification is a major factor contributing to a decrease in postoperative visual acuity, even when the graft remains clear. Cataract formation or progression has been linked to surgical trauma, normal lens physiology, prolonged intraocular inflammation and prolonged use of topical corticosteroids [1]. Studies have been conducted to determine the incidence and risk factors of developing cataracts after PKP. The aim of this study is to elucidate the risk factors for the development of cataract after a transfixing keratoplasty in order to ensure better patient management namely the performance of combined surgery or subsequent management of the cataract.

Materials and Methods

This is a retrospective analytical study which included 58 patients who had undergone keratoplasty with a follow-up of 24 months. The inclusion criteria were any patient who underwent keratoplasty with a clear lens before the intervention. Only the first transplant was included to obtain independent data. We have collected data related to the patient, namely age, gender and medical history. Then, all patients have received a preoperative examination including preoperative visual acuity and a complete ophthalmological examination.

For the surgical technique, the donor's cornea was trepanned with the Hanna trepan via the endothelial route, oversized by 0.25mm compared to that of the recipient also trepanned by the Hanna trepan via the epithelial route completed with the Catzin scissors. Then there was the placement of a graft and the realization of 4 cardinal points with the 10.0 monofilament, completed by 12 separate points. Precautions were taken during surgery to avoid any trauma to the crystalline lens, in particular preoperative pupil constriction with topical pilocarpine, controlled trepanation and protection of the anterior capsule with viscoelastic substance, no surgery was done on the iris. As for the postoperative data, all our patients benefited postoperatively from a treatment based on antibioticocorticoids at a rate of one drop 4 times a day with progressive decrease and a healing ointment based on vitamin A applied 3 times a day. Postoperative examination was carried out with a daily rhythm in the immediate postoperative period, that is, the first week and then 15 days after the intervention, monthly for six months, then every two months the first year, then the rhythm adjusted according to the evolution, it assessed postoperative visual acuity, the appearance of the graft, transparency of the crystalline lens (type and density of the cataract), measurement of ocular tonus, measurement of corneal thickness by ultrasonic pachymetry, measurement of endothelial cell density by specular microscope, and finally, examination of the fundus when possible.

The main criteria studied were age, gender, etiology, and average dose of corticosteroid.

Results

The study group comprised 58 eyes in 33 female and 25 male patients. The mean age at the time of the keratoplasty was 44, 5 years (from 15 to 70 years). The mean follow-up time from penetrating keratoplasty to last examination was 24 months. The most frequent diagnosis was keratoconus (20 eyes; 34,4%), followed by post traumatic scars (13 eyes; 22,4%), Infectious keratitis scar (11 eyes; 19%), and corneal dystrophy (9 eyes; 15,5%), finally bullous keratopathy (5 eyes; 8,6%). Most of the patients had a collapsed visual acuity prior to the intervention, it was

limited to 'counting fingers at one meter' in 28 patients (48%), 'moving fingers' in 20 patients (34.5%), 9 patients had a visual acuity of 1/10 (15.5%) and only one case was 'positive light perception' which was 1.7%. A cataract occurred in 10 patients (17.2%), with an onset time of 18 months (between 16 and 24 months). Regarding the type of cataract, 8 (80%) were nuclear cataracts, one patient (10%) developed a cortico-nuclear cataract, and one (10%) had a posterior subcapsular cataract.

Cataract Development Risk Factors

The average age of development of cataract was 55 years with extremes ranging from 40 to 70 years, the probability of cataract formation increased from 0% in the 15-40 age group to 62.5% in the 60-70 age group (Table 1).

Table 1: distribution of patients according to age.

	Frequency	Percentage
15 years – 30 years	0	0%
30 years – 40 years	0	0%
40 years – 50 years	1	4%
50 years – 60 years	4	44,5%
60 years – 70 years	5	62,5%

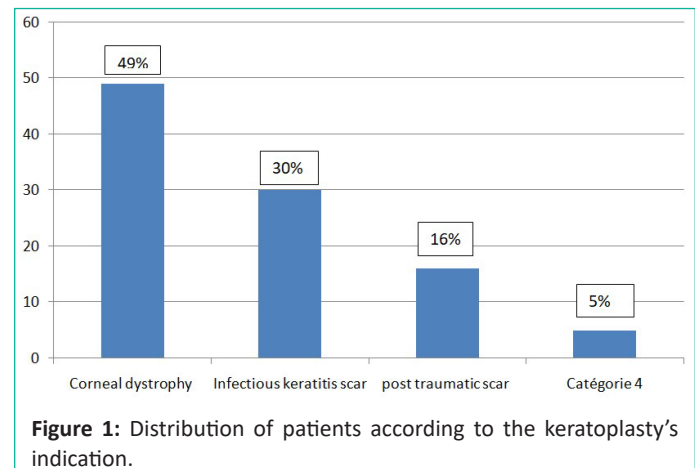


Figure 1: Distribution of patients according to the keratoplasty's indication.

A significant relation between donor age and cataract formation was noted ($p < 0.05$) (Table).

Of the 10 cataracts formed, 7 were women (21% of the 33 women), 3 were men (12% of the 25 men), there was no significant correlation in our study between sex and the development of cataract ($p > 0.05$). The mean dose of corticosteroids in our study was slightly higher in eyes affected by cataract (380+/-25units) compared to those who did not develop it (290+/-16units), however there was no significant correlation between the mean dose of corticosteroids and the formation of cataract ($p > 0.05$). Regarding the operative indication, cataracts developed in 4 of the 9 cases operated for corneal dystrophy (44.4%), in 3 of the 11 cases operated for Infectious keratitis scar (27.2%), in 2 of the 13 cases operated for post-traumatic opacity (15%) and in 1 of the 20 cases operated for keratoconus (5%). The analysis of these data showed that there is a significant relationship between the diagnosis and the formation of cataract in our series ($p < 0.05$).

Discussion

Cataract after penetrating keratoplasty is a rare complication, its incidence of appearance ranges from 0.4% [1] to 32% [2] depending on the series. In our work, cataract was noted in 17.2% of the operated cases, this result remains close to those found in the different studies (Table 3).

Table 2: Risk factor for cataract post penetrating keratoplasty.

Risk factor	Number of eye	Cataract formation (%)	P
Age:			
40 years -50 years	21	4%	P<0,05
40 years -50 years	9	44,5%	
40 years -50 years	8	62,5%	
Gender			
Female	33	21%	P>0,05
Male	25	12%	
The average dose of corticoid			
380+/-25 units	10	100%	P>0,05
290+/-16 units	48	0%	
Indication of keratoplasty			
Keratoconus			P<0,05
Post traumatic scar	20	5%	
Infectious keratitis scar	13	15%	
Corneal dystrophy	11	44,4%	
Bullous keratopathy	9	27,2%	
	5	0%	

The main risk factor for the development of cataract after keratoplasty in patients with clear crystalline lens before intervention is the patient's age. In our patients, the mean age at the time of cataract diagnosis was 55 years with extremes ranging from 40 to 70 years; its incidence of onset is 62.5% in patients over 60 years old. Here our data agrees with those of the literature, in fact in a retrospective study carried out by Martin [3] to identify the risk factors for the development of cataract, the mean age was 56 years, the probability of developing a cataract in the two years following penetrating keratoplasty went from 19% in the group of patients aged 40 to 49 years, to 72% in the group of patients aged 60 to 70 years. In another study by Payant [4], the risk of cataract after keratoplasty increases with age to reach 75% after 60 years. In this study, the development of cataract was not significantly correlated to the gender. These data are in line with the results from the literature [3]. No correlation between the mean dose of corticosteroids and the formation of cataract was found in our study, our results do not correspond to those found in the literature; in a study conducted by Rathi [5], the mean dose was significantly higher in eyes affected by cataracts (563+/-234units) than in those who did not develop cataracts (479+/-127units) (P<0.05). In this study, excessive use of corticosteroids is a major risk factor for the formation of post keratoplasty transfixing cataracts. Donshik et al [2] reported in a study of 86 eyes over 4 years, a rate of 32% cataracts, the development of posterior subcapsular cataracts was significantly associated with the cumulative total dose of steroids and the total time of corticosteroid administration (P<0.05). This discrepancy is explained by the fact that the mean dose of corticosteroids administered to our patients was lower than that administered in these studies. Operative indications (Fuchs' dystrophy, infectious pathologies) are described in literature as risk factors for post-penetrating keratoplasty cataract. In our study, cataract developed in 44.4% of the cases operated for corneal dystrophies and in 27.2% of the cases operated for sequelae of infectious keratitis, in 15% of the cases operated for post-traumatic leucoma and in 5% of the cases operated for keratoconus. These results correspond to those found in the lit-

Table 3: Cataract frequency post penetrating keratoplasty

Series	Cataract Frequency Post Penetrating Kertoplasty
Donshik [2]	32%
Sharif [1]	12%
Martin [3]	18%
Rathi [5]	24%
Rumelt [6]	14%
Our series	17,2%

erature, for example, in Martin's study, cataract developed in 47% of the cases operated for dystrophy, 28% of the cases operated for sequelae of infectious keratitis, and 6% of the cases operated for keratoconus. Post-keratoplasty cataract can present as nuclear, cortical, or posterior capsular opacities. In our study, 80% of the patients developed a nuclear cataract, which is close to the results of the Rumet study [6], where nuclear cataracts were found in 52% of the cases. Its treatment corresponds to a usual cataract surgery using phacoemulsification with implantation in the capsular bag. It is necessary to check the endothelial cell density before scheduling a surgical intervention. The scleral incision is preferred since it affects the endothelium less than a corneal incision, a high viscosity viscoelastic product should be used and ultrasonics should be avoided near the corneal endothelium. In postoperative treatment, preventive rejection treatment should be resumed or even increased.

Conclusion

Post-keratoplasty corneal graft cataract is a major cause of decreased visual acuity post-keratoplasty in the presence of a clear graft, its incidence rate varies from 0.4% [3] to 32% [4] according to series. However, this frequency has decreased since the advent of lamellar grafts and the improvement of the surgical technique. Our study of 58 keratoplasties in patients of different ages and diagnoses allowed us to identify age and indication of the graft as risk factors for the development of post-corneal graft cataract in order to help surgeons determine an appropriate procedure, either penetrating keratoplasty alone or combined with cataract extraction in their patients.

References

- Sagnières H, Doat M, Girard A, Legeais JM, Renarde G, et al. Acuité visuelle un et deux ans après la kératoplastie transfixante pour kératocône. *Journal Français d'ophtalmologie*. 2002; 30: 465-473.
- Donshick PC, Canavaush HD, Dohlman GHI. Posterior subcapsular cataracts induced by topical corticosteroid following keratoplasty for keratoconus. *Ann Ophthalmol*. 1981; 13: 29-32.
- Martin TP, Reed JW, Legault C, Oberfeld SM, Jacoby RG, et al. Cataract formation and cataract extraction after penetrating keratoplasty. *Ophthalmology*. 1994; 101: 113-119.
- Payant JA, Gordon LW, Vander Zwaag R, Wood TO. Cataract formation following corneal transplantation in eyes with Fuchs' endothelial dystrophy. *Cornea*. 1990; 9: 286-289.
- Rathi VM, Krishnamachary M, Gupta S. Formation de cataracte après une kératoplastie pénétrante. *J Cataract Refract Surg*. 1997; 23: 562-564.
- Rumlet S. Development and progression of cataract in patients required repeated corneal transplantation. *Eye*. 2003; 17: 1025-1031.