

Case Report

Choroideremia: A Case Report of Bilateral Chorioretinal Atrophy in a Young Male

Essakali Amine^{1*}, Kanboui Marouane¹, Mahmoudi Marame¹, Lakraa Rania¹, Akkanour Younes², Serghini Louay² and El Hassan Abdallah²

¹Service d'Ophtalmologie B, Hôpital des Spécialités, Université Mohammed V, Rabat, Morocco

²Faculté de Médecine et de Pharmacie de Rabat, Université Mohammed V, Rabat, Morocco

*Corresponding author: Dr. Amine Essakali, Service d'Ophtalmologie B, Hôpital des Spécialités, Université Mohammed V, Rabat, Morocco

Email: dr.amine.skali@gmail.com

Received: October 24, 2025

Accepted: November 11, 2025

Published: November 14, 2025

Abstract

Choroideremia is a rare, X-linked recessive inherited chorioretinal dystrophy characterized by progressive degeneration of the retinal pigment epithelium (RPE), choriocapillaris, and photoreceptors. We report a case of a young male presenting with progressive visual impairment and night blindness since childhood, in whom molecular analysis confirmed the diagnosis. This case highlights the importance of multidisciplinary collaboration between ophthalmologists and geneticists in the diagnosis of inherited retinal diseases.

Introduction

Choroideremia is a rare hereditary ocular disorder with X-linked recessive transmission [1]. It belongs to the spectrum of choroidal dystrophies and is characterized by diffuse and progressive degeneration of the retinal pigment epithelium (RPE) and choriocapillaris, eventually leading to extensive chorioretinal atrophy. Although there is currently no curative treatment, promising gene therapy trials are under active investigation [2].

Case Presentation

We report the case of a 28-year-old male from a rural background, with a family history of low vision, who presented with progressive visual decline and nyctalopia since childhood. His best-corrected visual acuity was limited to counting fingers at near in both eyes. Intraocular pressure was 17 mmHg bilaterally. On inspection, bilateral horizontal nystagmus was noted. Slit-lamp examination of the anterior segment was unremarkable. Fundus examination revealed bilateral, diffuse chorioretinal atrophy consistent with choroideremia (Figures 1A and 1B). Molecular genetic testing through direct sequencing identified a pathogenic variant in the CHM gene located on the X chromosome, thereby confirming the diagnosis of choroideremia. This case underlines the crucial role of molecular testing and the collaboration between ophthalmologists and geneticists in the diagnosis and management of hereditary retinal dystrophies.

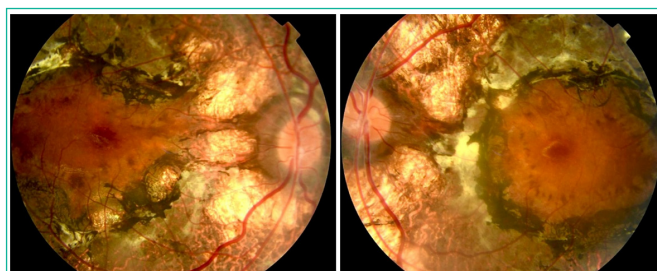


Figure 1A: Color fundus photograph of the right eye showing diffuse chorioretinal atrophy with well-demarcated areas of RPE loss and exposure of underlying choroidal vessels.

Figure 1B: Color fundus photograph of the left eye showing extensive chorioretinal atrophy with a preserved central island corresponding to the foveal region.

Discussion

Choroideremia typically affects males, while female carriers are usually asymptomatic or show mild fundus changes. The disease begins with night blindness and peripheral visual field loss, progressing toward central vision impairment as macular involvement develops. Mutations in the CHM gene, which encodes the Rab escort protein-1 (REP1), result in defective intracellular trafficking and progressive retinal degeneration. Advances in molecular diagnostics have made early and accurate identification of CHM mutations possible, which is

essential for genetic counseling and future therapeutic interventions. Recent clinical trials in gene replacement therapy have demonstrated encouraging results, aiming to restore REP1 function and halt disease progression [2].

Conclusion

This case illustrates the typical clinical and genetic features of choroideremia and emphasizes the value of genetic analysis in confirming the diagnosis. Early recognition and multidisciplinary management remain key in the era of emerging gene therapies.

References

1. MacDonald IM, Mah DY, Ho YK, Lewis RA. Choroideremia: New Findings and Future Prospects in Retinal Gene Therapy. *Prog Retin Eye Res.* 2020; 79: 100862.
2. Dimopoulos IS, et al. Two-Year Results After AAV2-Mediated Gene Therapy for Choroideremia: The Natural History of Treated and Untreated Eyes. *Am J Ophthalmol.* 2018; 193: 130–142.