

## Clinical Image

# Isolated Fracture of the Greater Trochanter in Elderly

Yassine Ben Bouzid\*; Marouane Dinia; Rida-Allah Bassir; Monsef Boufettal; Jalal Mekkaoui; Mohamed Kharmaz; Moulay Omar Lamrani; Mohamed Saleh Ber-rada

Department of Orthopaedic and Trauma Surgery, Ibn Sina University Hospital, Rabat, Morocco

\*Corresponding author: Yassine Ben Bouzid

Department of Orthopaedic and Trauma Surgery, Ibn Sina University Hospital, Rabat, Morocco.  
Email: yassine.benbouzid2@gmail.com

Received: March 21, 2023

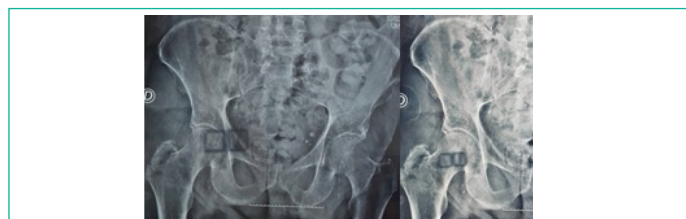
Accepted: April 28, 2023

Published: May 05, 2023

## Clinical Image

Isolated fracture of the greater trochanter are unusual and rare injury. The literature has focused on the extension of these fractures to the trochanteric region and their management [1,2]. MRI is recommended to evaluate the fracture and rule out intertrochanteric extension [3-5]. The management of these fractures remains debated due to lack of long-term reports [3,6]. However, abductor function may be affected, which may justify surgical treatment [7].

We report the case of a 92 years old, hypertensive subject under treatment, who was admitted following a banal fall on the right hip. The patient was previously independent. The physical examination found pain in the left hip, with limited and painful mobility especially during abduction. The rest of the systemic examination was normal. On standard radiography, an isolated fracture of the greater trochanter was noted. The indication for orthopedic treatment was retained with immobilization for 1 month. Non weight-bearing rehabilitation was started in the second week of the injury. Partial weight-bearing was allowed after 4 weeks, followed by full weight-bearing 2 weeks later. Consolidation was achieved after 6 weeks. After 6 months, the patient had regained his autonomy with a preserved mobility of the hip.



## References

1. Schultz E, Miller TT, Boruchov SD, Schmill EB, Toledano B. Incomplete intertrochanteric fractures: Imaging features and clinical management. *Radiology*. 1999; 211: 237-240.
2. Hartford JM, Graw BP, Knowles SB, Frosch DL. Isolated greater trochanter fracture and the direct anterior approach using a fracture table. *J Arthroplasty*. 2018; 33: S253-S258.
3. Park JH, Shon HC, Chang JS, Kim CH, Byun SE, et al. How can MRI change the treatment strategy in apparently isolated greater trochanteric fracture?. *Injury*. 2018; 49: 824-828.
4. LaLonde B, Fenton P, Campbell A, Wilson P, Yen D. Immediate weight-bearing in suspected isolated greater trochanter fractures as delineated on MRI. *Iowa Orthop J*. 2010; 30: 201-204.
5. Suzuki K, Kawachi S, Nanke H. Insufficiency femoral intertrochanteric fractures associated with greater trochanteric avulsion fractures. *Arch Orthop Trauma Surg*. 2011; 131: 1697-1702.
6. Feldman F, Staron RB, Zwass A, Rubin S, Haramati N. MRI: Its role in detecting occult fractures. *Skeletal Radiol*. 1994; 23: 633-636.
7. Ren H, Huang Q, He J, Wang Y, Wu L, et al. Does isolated greater trochanter implication affect hip abducent strength and functions in intertrochanteric fracture?. *BMC Musculoskelet Disord*. 2019; 20: 79.