

Clinical Image

Neurobrucellosis in a Striped Dolphin

Di Guardo G*Faculty of Veterinary Medicine, University of Teramo,
Località Piano d'Accio, 64100 - Teramo, Italy***Corresponding author:** Di Guardo G, Faculty of
Veterinary Medicine, University of Teramo, Italy**Received:** April 04, 2016; **Accepted:** April 20, 2016;**Published:** April 22, 2016

Clinical Image

The image shows a brain tissue section obtained from a striped dolphin (*Stenella coeruleoalba*) (Figure 1), which was found stranded in 2012 along the southern Adriatic Sea coast of Italy. A prominent, subacute-to-chronic, predominantly lympho-histiocytic leptomeningitis is observed, along with a simultaneous, though far less pronounced involvement of the subcortical grey matter by a similar inflammatory infiltrate. The agent responsible for the aforementioned lesions' development is *Brucella ceti*, the most recent "entry" into the *Brucella* genus, a feature which is also shared by *B. pinnipedialis*. Besides infecting a consistent number of aquatic mammal species worldwide, *B. ceti* and *B. pinnipedialis* are zoonotic pathogens, capable of causing neurobrucellosis and osteomyelitis in human patients. Likewise, *B. ceti* is known to display a strong neurotropism in striped dolphins, which frequently develop remarkable brain lesions particularly affecting their meninges (as in the case presented here) and choroid plexuses, with subsequent neurological impairment, disorientation and stranding.

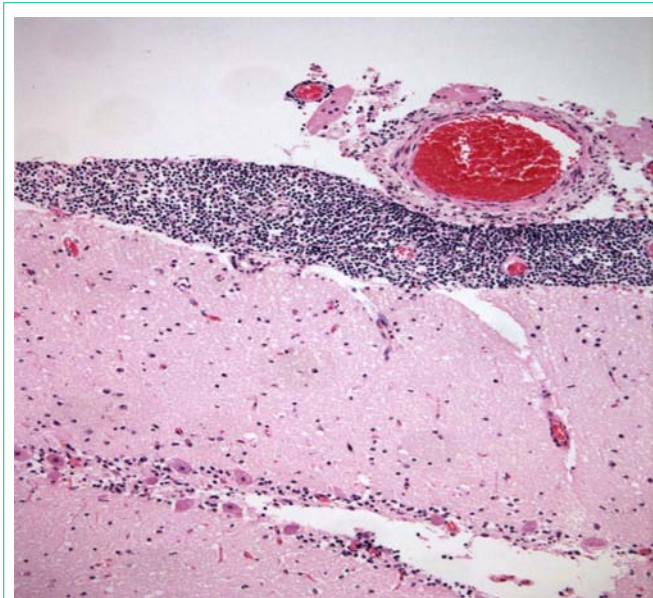


Figure 1: Brain tissue section obtained from a striped dolphin (*Stenella coeruleoalba*).