

Case Report

Acute Abdominal Aortic Dissection during Invasive Coronary Assessment in a Patient with Glucose-6-Phosphate Dehydrogenase Deficiency

Mehrpooya M^{1*}, Ghasemi M¹, Gerayeli B¹, Sherafati A² and Dashti S³

¹Department of Cardiology, Imam Khomeini Hospital Complex, Tehran University of Medical Sciences, Iran

²Department of Cardiovascular Medicine, Mayo Clinic, USA

³Department of Pharmacy, Imam Khomeini Hospital Complex, Tehran University of Medical Sciences, Iran

*Corresponding author: Maryam Mehrpooya, Department of Cardiology, Imam Khomeini Hospital Complex, Tehran University of Medical Sciences, Tohid Square, Tehran, Iran

Received: July 30, 2022; Accepted: August 29, 2022;

Published: September 05, 2022

Abstract

Background: Glucose-6-Phosphate Dehydrogenase (G6PD) is an X-linked recessive disorder. Acute hemolytic anemia can occur in these patients if they are exposed to certain foods or drugs. Iatrogenic Isolated Acute Abdominal Aortic Dissection (IAAAD) is an uncommon complication during diagnostic or interventional coronary procedures. Endovascular intervention for abdominal aortic dissection is mandatory in some patients.

Case Summary: A 58-years-old man with a history of G6PD deficiency underwent primary percutaneous coronary intervention for the right coronary artery. He was discharged with aspirin 80 milligrams daily as well as clopidogrel. The patient stopped taking aspirin immediately after discharge. He was admitted again for an invasive physiologic study of the left anterior descending artery. Due to the risk of stent thrombosis, we reinitiated aspirin. During his scheduled intervention, iatrogenic AAAAD happened. Endovascular intervention was performed, and a self-expandable stent was implanted successfully at the site of dissection. Regarding some laboratory evidence of hemolysis with aspirin, the drug was discontinued on the tenth day after the procedure, and he was discharged in good general condition.

Discussion: Hemolytic anemia can occur with a low dose of aspirin in patients with G6PD deficiency. Endovascular intervention is a practical therapeutic approach to iatrogenic IAAAD.

Keywords: Abdominal aortic dissection; G6PD deficiency; IAAAD; Endovascular intervention

History of Presentation

A 58-years-old man was admitted due to acute inferior ST-Segment Elevation Myocardial Infarction (STEMI). He underwent primary Percutaneous Coronary Intervention (PCI) for the Right Coronary Artery (RCA) He had a history of Glucose-6-Phosphate Dehydrogenase (G6PD) deficiency. He was discharged on the fourth day after the index event with aspirin 80 mg daily as well as clopidogrel 75 mg daily. Regarding multiple moderate coronary lesions in the Left Anterior Descending artery (LAD), he was scheduled for an invasive physiologic study of LAD. He presented for his scheduled procedure after a month. He stated that he had stopped taking aspirin after his discharge from the hospital due to fear of G6PD crisis but had continued clopidogrel.

Past Medical History

His past medical history was significant for G6PD deficiency, type 2 diabetes mellitus and hypertension.

Differential Diagnosis

Due to the discontinuation of aspirin, there was a concern about sub acute stent thrombosis.

Investigations

He was hospitalized and after consultation with clinical

pharmacologists and an extensive literature review, aspirin appeared to be safe in low doses. Therefore, aspirin was reinitiated for him with a dose of 80 mg daily. Coronary angiogram showed a patent stent in the RCA. For the physiologic study of LAD, an instantaneous wave-free ratio (iFR) wire was passed through the LAD. However, as soon as the wire crossed the LAD, the patient complained of severe back pain. He had a stable heart rhythm and hemodynamics. There was no sign of dissection or occlusion in the LAD, so the iFR wire was removed. We performed an aortic injection immediately. There was no sign of dissection in aortic root, but a 10-mm dissection was evident in the abdominal aorta before the aortic bifurcation (Figure 1, Video 1, Video 2). Due to the stable hemodynamics, we terminated the procedure. Aortic dissection was confirmed by CT angiography with a calculated size of 10 mm (Figure 2).

Despite the ascertained data from imaging, we were still unsure if the aortic dissection was iatrogenic. However, given the course of the events, the iatrogenic injury appeared to be more likely.

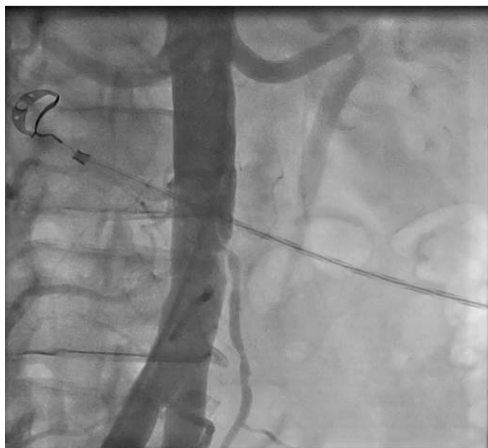
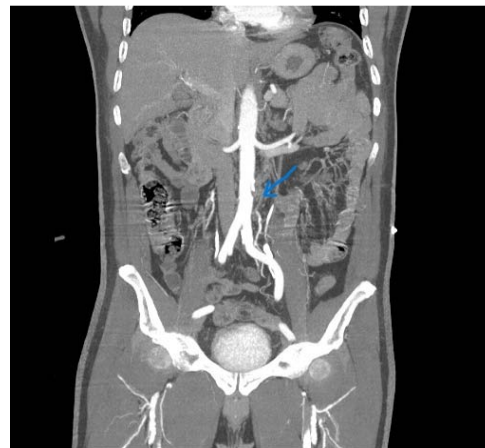
Management

One day after the angiogram (second day of admission), the laboratory findings were as follows: hemoglobin was 11.4 g/dL, serum urea was 46 mg/dL, and serum creatinine was 1.8 mg/dL.

On the seventh day after the angiogram (index event), he looked

Table 1: Serial laboratory data of patient.

Serial laboratory data of patient						
Days	Day 1	Day 2	Day 7	Day 10	Day 11	Day 14
Laboratory data						(After discharge)
Haemoglobin (g/dL)	11.4	11.4	10.7	10	10	10.8
Haematocrit (%)						
Blood urea nitrogen (mg/dL)	33	46		54	45	
Serum creatinine (mg/dL)	1.4	1.8	3.3	1.8	1.5	1.3
Platelet count (N × 10 ³ /mL)	231		249	332	277	
Corrected reticulocyte count (%)				2.9		
Total Bilirubin (mg/dL)		1.4		1.9		
Indirect Bilirubin (mg/dL)		1.1		1.5		
Haptoglobin (mg/dL)				Less than 40 mg/dL		
LDH (U/L)				476		

**Figure 1:** Dissection of abdominal aorta (angiographic view).**Figure 2:** Dissection of abdominal aorta (CT angiography).

ill and pale. (Table 1) shows the lab results on this day. Reported G6PD activity was about between 10-60 % (class III deficiency). Hydration and other approaches were made for probable contrast-induced nephropathy. The patient's creatinine level continued to low about 2 mg/dL. Regarding his continuous back pain, an endovascular procedure was performed on the ninth day the angiogram. After aortography and precise location determination, a self-expandable nitinol aortic Stent (Optimed) 22*40 was implanted in abdominal aorta and successfully covered the place of dissection with an adequate landing zone. Total amount of used agent was about 50 cc. Last injection showed successful final result (Video 3, Video 4, and Video 5).

The day after the procedure, a hematology consultation was requested. His hemoglobin was 10g/dL, and his corrected reticulocyte count was 2.9%. It seemed that despite the previous literature review result, aspirin was the cause of hemolytic anemia in this patient.

We discontinued aspirin due to the high probability of aspirin-induced hemolysis. His hospital course was uneventful, and he was discharged with scheduled follow-up hematology and cardiology visits.

Discussion

We report a case of G6PD deficiency with aspirin-induced hemolysis with a low dose and aortic dissection during the coronary physiologic study, which seems most probably iatrogenic. Our patient had a history of primary PCI, necessitating the use of dual antiplatelet therapy [1,2]. A recent review concluded that large, randomized clinical trials are mandatory to determine whether aspirin with low doses can cause a hemolysis crisis in G6PD deficient patients [3]. Despite the authoritative scientific investigations that considered high doses of aspirin as a possible cause of hemolysis (not predictable hemolysis), there was aspirin-induced hemolysis in low doses in our patient [4].

IAAAD is a rare clinical entity. Iatrogenic type could be complication of a cardiac catheterization or interventional procedures. In the IRAD registry, iatrogenic IAAAD was about 11.1 % in those with a history of ischemic heart disease, one of whom died in the hospital. They suggested that in patients with atherosclerosis, iatrogenic aortic dissection is more common due to the intimal calcification of the aortic wall [5].

The impaired endothelial function has been shown in G6PD

deficiency [6,7]. Our patient had ischemic heart disease, and probably, the superimposed endothelial dysfunction due to G6PD deficiency predisposed him to vascular injury and iatrogenic aortic dissection.

A spontaneous isolated infrarenal abdominal aortic dissection was reported. The patient underwent conservative management due to stable hemodynamics, the lesion's relatively chronic nature, and the stable size of the aorta [8]. Our patient underwent endovascular treatment because it was more likely to be iatrogenic. In addition, we were worried about the progression of the dissection regarding the history of hypertension, ischemic heart disease, and most importantly, underlying G6PD deficiency.

Angiographic contrast agent had been suggested as a possible cause of hemolysis as a hypothesis [9], but our patient had no evidence of hemolysis following the first angiogram performed for primary PCI.

A recent systematic review, adopted endovascular intervention for certain patients as an early treatment strategy [10]. We preferred endovascular intervention for our patient because of persistent back pain and the risk of progression of dissection, especially in the setting of G6PD deficiency.

The main purpose of this report is of precautionary use of aspirin in G6PD deficiency, also, we suggest endovascular intervention for abdominal aortic dissection, especially iatrogenic type, and particularly when there is an underlying disease.

Follow up

Four days after the discharge, he was revisited at the outpatient clinic, and his general condition was very good.

Conclusion

This case report emphasizes on precautionary use of aspirin even with a low dose in patients with G6PD deficiency. In addition, aspirin-induced hemolysis should always be considered in these patients. Acute iatrogenic aortic dissection can occur in the context of cardiovascular catheterization or any interventional procedure,

and probably, underlying diseases, including G6PD deficiency, have been implicated in aortic injury. Finally, it should be emphasized that endovascular treatment of abdominal aortic dissection is an effective and safe treatment in these patients to prevent the progression of the lesion and subsequent catastrophic events.

References

1. Feghaly J, Hout ARA, Balbi MM. Aspirin safety in glucose-6-phosphate dehydrogenase deficiency patients with acute coronary syndrome undergoing percutaneous coronary intervention. *BMJ Case Reports*. 2017; 2017: bcr-2017-220483.
2. Valgimigli M. *The ESC DAPT Guidelines 2017*. Oxford University Press; 2018.
3. Li J, Chen Y, Ou Z, Ouyang F, Liang J, Jiang Z, et al. Aspirin Therapy in Cardiovascular Disease with Glucose-6-Phosphate Dehydrogenase Deficiency, Safe or Not?. *American Journal of Cardiovascular Drugs*. 2020: 1-6.
4. Roper D, Layton M, Rees D, Lambert C, Vulliamy T, Salle BDL, et al. Laboratory diagnosis of G6PD deficiency. A British Society for Haematology Guideline. *British Journal of Haematology*. 2020; 189: 24-38.
5. Trimarchi S, Tsai T, Eagle KA, Isselbacher EM, Froehlich J, Cooper JV, et al. Acute abdominal aortic dissection: insight from the International Registry of Acute Aortic Dissection (IRAD). *Journal of vascular surgery*. 2007; 46: 913-919.e1.
6. Parsanathan R, Jain SK. Glucose-6-phosphate dehydrogenase (G6PD) deficiency is linked with cardiovascular disease. *Hypertension Research*. 2020; 43: 582-584.
7. Parsanathan R, Jain SK. Glucose-6-Phosphate Dehydrogenase Deficiency Activates Endothelial Cell and Leukocyte Adhesion Mediated via the TGFβ/NADPH Oxidases/ROS Signaling Pathway. *International Journal of Molecular Sciences*. 2020; 21: 7474.
8. Tang ELS, Chong CS, Narayanan S. Isolated abdominal aortic dissection. *BMJ Case Reports*. 2014; 2014: bcr2013203097-bcr2013203097.
9. Küçükseymen S, Çağirci G, Köklü E, Yüksel I, Bayar N, Esin M, et al. Acute hemolysis in glucose-6-phosphate dehydrogenase deficiency after coronary angiography. *GAZZ MED ITAL*. 2015; 174: 427-30.
10. Liu Y, Han M, Zhao J, Kang L, Ma Y, Huang B, et al. Systematic Review and Meta-analysis of Current Literature on Isolated Abdominal Aortic Dissection. *European journal of vascular and endovascular surgery: the official journal of the European Society for Vascular Surgery*. 2019; 59: 545-556.