

## Case Report

# Thromboelastometry-Guided Therapy of Fulminant Coagulopathy during C-Section and Amniotic Fluid Embolism

Weiss R<sup>1\*</sup>, Von Groote TC<sup>1</sup>, Schäfer SD<sup>2</sup> and Keller M<sup>1</sup>

<sup>1</sup>Department of Anesthesiology, Intensive Care and Pain Medicine, University Hospital Münster, Germany

<sup>2</sup>Department of Gynecology and Obstetrics, University Hospital Münster, Germany

\*Corresponding author: Weiss R, Department for Anesthesiology, Intensive Care and Pain Medicine, University Hospital Münster, Albert-Schweitzer-Campus 1, Complex A1, 48149 Münster–Germany

Received: June 24, 2022; Accepted: July 26, 2022;

Published: August 02, 2022

## Abstract

This article describes the emergency case of a mid-thirty-year-old pregnant woman who suffered the rare obstetric complication of an amniotic fluid embolism, resulting in fulminant Disseminated Intravascular Coagulopathy (DIC) and shock. DIC was diagnosed with Thromboelastometry (TEM) and therapy was consequently guided by TEM. Thromboelastometry is a viscoelastic hemostatic assay that enables assessment of different aspects of whole blood clot formation under shear stress. This technique is increasingly used in anesthesia and critical care to guide hemostatic therapy. This report underlines the importance of TEM-monitoring of hemostatic complications such as DIC.

**Keywords:** Guided therapy; Shock; ROTEM; Disseminated intravascular coagulopathy; Caesarean section

## Case Presentation

### Introduction

In 2000, the United Nations defined the Millennium Development Goals to improve global living conditions. Goal five aims for an improvement in maternal health care with a 75% reduction in the maternal mortality rate within two decades. Since then, rates of maternal survival have improved significantly (50% reduction in maternal mortality since 1990), with the majority being achieved after 2000. Nevertheless, around 300,000 mothers worldwide continue to die each year as a result of childbirth. This is around 820 dead mothers per day [1]. To improve this situation, interdisciplinary cooperation between, anesthesiological and gynaecological teams is essential. Especially in complex and challenging emergency cases, implementation of innovative technologies yields major opportunities to enable more directed therapies (precision medicine).

In 2014, the World Health Organization (WHO) published a comprehensive global analysis of the leading causes of maternal death (Table 1) [2]. Regardless of region, hemorrhage was the leading cause of death, followed by embolism.

Firstly described in 1926 by J.R. Meyer at the University of Sao Paulo [3], an Amniotic Fluid Embolism (AFE) represents a combination of both mechanisms. AFE is a result of translocation of amniotic fluid into the maternal bloodstream, resulting in an obstruction of the maternal pulmonary vessels by the fluid's corpuscular components. Consecutive vasoconstriction, right ventricular overload, and an acute drop of the left ventricular filling pressure provokes cardiogenic shock. It is assumed that the amount of embolized corpuscular components correlates with the severity of this process. In up to 80% of patients, Disseminated Intravascular Coagulation (DIC) with reactive hyperfibrinolysis and consumption coagulopathy develops due to the combination of the amniotic fluid's high amount of thromboplastin and existing maternal cardiogenic

shock. Coma and convulsions are the consequences of hypoxia and cardiopulmonary collapse. Subsequently, liver and renal failure may develop.

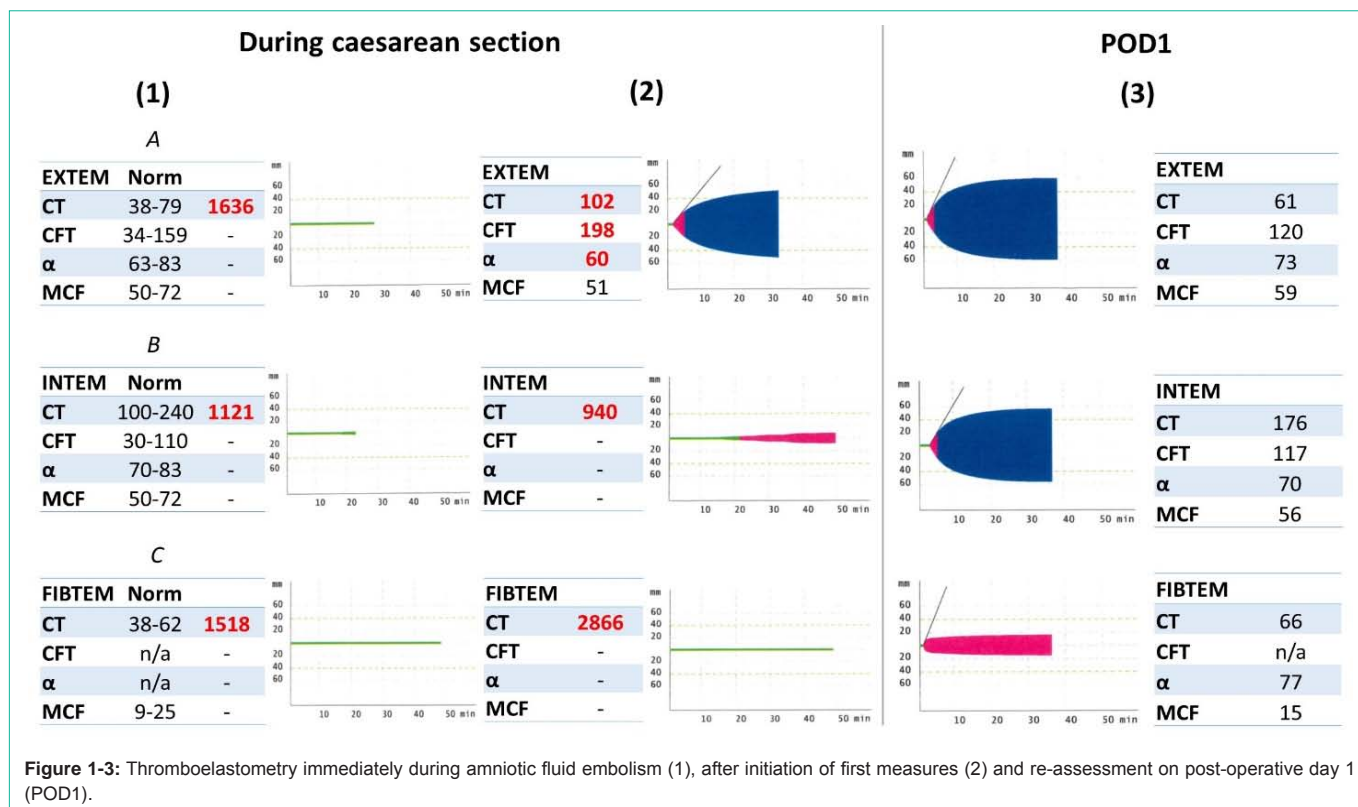
According to the literature, incidence varies between 1.9:100,000 to 6.1:100,000 [4]. Although a rare obstetric emergency, an AFE is associated with a high maternal mortality rate (20-60%) and compromises approximately 10% of all maternal deaths during caesarean section [4-6]. About 25% of affected patients die within the first hour [7].

In this case report we refer to a young, previously healthy woman, who developed an AFE under emergency cesarean section, whose hemorrhage was successfully treated with the help of Thromboelastometry (TEM). TEM is an innovative point-of-care method for hemostatic assessment in whole blood, which helps to discriminate coagulopathies rapidly and guides the immediate therapy of hemostatic products.

### Main Text

A mid-thirty-year-old pregnant woman (24+5 weeks of gestation) was admitted to the hospital with new onset of mirror syndrome associated with parvovirus B19 infection. The clinical examination presented a significant fetal hydropic decompensation, which – together with an acute clinical deterioration of the mother – made an emergency caesarean section necessary. Subsequently, the patient was urgently intubated while simultaneously being prepared for surgery. During caesarean section, sudden major bleeding of the mother occurred with progressively worsening coagulopathy. Blood levels of hemoglobin dropped acutely to 5.4 g/dL. The most likely cause of this immediate incident was the rare complication of amniotic fluid entering the maternal vessels as coagulopathy markedly occurred and progressively deteriorated after surgical opening of uterine vessels.

Thromboelastometry (TEM) was performed to assess for potential disseminated intravascular coagulopathy, which was consequently



diagnosed (Figure 1). Both EXTEM and INTEM assays of TEM (Figure 1A and 1B) revealed significantly impaired coagulation and clot formation. FIBTEM analysis further emphasized this diagnosis (Figure 1C).

Resuscitation was immediately initiated by the transfusion of blood products, repletion of coagulation factors and crystalloid infusions. Overall the patient was resuscitated with six red blood cell concentrates, four units of fresh-frozen plasma, one thrombocyte concentrate, 6000 IU of prothrombin complex concentrate, 8g of fibrinogen, 3x1g calcium gluconate, 100mL sodium bicarbonate (8.4%), as well as 1g of tranexamic acid and 2.5 litres of crystalloids. Additionally, norepinephrine was continually infused as a vasopressor. Evolving hyperkalemia was corrected by simultaneous application of glucose 20% and insulin. Meanwhile, intensive efforts were made to keep the patient warm and to surgically stop the bleeding.

Following caesarean section and this resuscitation with differentiated mass transfusion, TEM was performed again (Figure 2) and demonstrated a significant improvement of coagulatory function in EXTEM analysis. Major bleeding was terminated surgically and visually decreased in the operative field. Uterine preservation could be achieved. After surgery, the patient was successfully extubated in the operating theatre and transferred to the intensive care unit in a hemodynamically stable condition. Coagulation was reassessed as compensated by TEM on the following day (Figure 3).

The patient was discharged in physical well-being on postoperative day 7. Psychosocial care was initiated in context of the child's death due to severe hydropic decompensation associated with previous parvovirus B19 infection.

**Table 1:** Leading causes of death regarding maternal mortality in industrial countries [2].

Cause of death	Portion
Bleeding	16,3 %
Embolism	13,8 %
Hypertension	12,9 %
Abortion	7,5 %
Sepsis	4,7 %
Other	20,0 %

### Discussion

As demonstrated in this case report, swift and correct diagnosis of AFE is a key factor for the patient's survival. Intensive cooperation between gynaecological surgeons and anesthesiologists is of utmost importance. Joint efforts to stabilize the patient have to be taken surgically and medically. This enables immediate resuscitation and stabilization of the cardiovascular system and termination of DIC. To handle such a situation, not only a quick, but targeted and definitive therapeutic approach is essential.

Here, the use of viscoelastic tests can provide useful advantages to guide and individualize treatment approaches. This allows for distinctive approaches with specific hemostatic agents, leading to normalisation of the coagulatory system - especially in the critically dysbalanced situation of DIC. TEM provides global information about kinetics and the structure of the clot, besides evaluating the fibrinolytic system. Like in this case, TEM quickly reveals DIC and provides differential diagnostic information to support goal-directed

management, according to individual needs directly at the bedside. This is not only an improvement in time, but in quality of care.

Critically ill patients often require several blood transfusions. However, massive hemorrhage and blood transfusions themselves are associated with further risks and increased patient morbidity, as well as mortality, subsequently also leading to increased costs [8,9]. When used, TEM may lead to an improvement of treatment effects due to more targeted application of therapies, as well as an overall reduction in the amount of blood transfusions required, length of hospital stay and in-hospital mortality [10]. Saved costs for blood- and coagulation products may outweighed the expenses of TEM and underline the cost-effectiveness to justify the investment in this technology.

## Conclusion

This case report presents the successful interdisciplinary management of amniotic fluid embolism with disseminated intravascular coagulopathy during emergency cesarean section. Here, TEM enabled to diagnose quickly, treat precisely and stabilize the patient sustainably. Embedded in interdisciplinary management, TEM forms an important tool to increase success rates in the treatment of emergency patients with critical haemorrhage during caesarean section.

## References

1. United Nations. Millennium Development Goals and Beyond 2015; Goal 5: Improve Maternal Health. 2022.
2. Say L, Chou D, Gemmill A, Tunçalp, Moller A, Daniels J, et al. Global causes of maternal death: a WHO systematic analysis. *The Lancet. Global health.* 2014; 2: e323-e333.
3. Meyer JR. Embolia-pulmonar-amnio-caseosa. *Bras Med.* 1926; 301-303.
4. Clark SL, Hankins GD, Dudley DA, Dildy GA, Porter TF. Amniotic fluid embolism: analysis of the national registry. *American journal of obstetrics and gynecology.* 1995; 172: 1158-1169.
5. Stein PD. *Pulmonary embolism.* 3rd ed. NJ: John Wiley & Sons Inc. 2016.
6. Knight M, Berg C, Brocklehurst P, Kramer M, Lewis G, Oats J, et al. Amniotic fluid embolism incidence, risk factors and outcomes: a review and recommendations. *BMC Pregnancy and Childbirth.* 2012; 12: 7-7.
7. Conde-Agudelo A, Romero R. Amniotic fluid embolism: an evidence-based review. *Am J Obstet Gynecol.* 2009; 201: 445. e1-13.
8. Murphy GJ, Reeves BC, Rogers CA, Rizvi SI, Culliford L, Angelini GD. Increased mortality, postoperative morbidity, and cost after red blood cell transfusion in patients having cardiac surgery. *Circulation.* 2007; 116: 2544-52.
9. Christensen MC, Krapf S, Kempel A, Heymann CV. Costs of excessive postoperative hemorrhage in cardiac surgery. *The Journal of thoracic and cardiovascular surgery.* 2009; 138: 687-693.
10. Spalding GJ, Hartrumpf M, Sierig T, Oesberg N, Kirschke CG, Albes JM. Cost reduction of perioperative coagulation management in cardiac surgery: value of "bedside" thrombelastography (ROTEM). *European journal of cardio-thoracic surgery : official journal of the European Association for Cardio-thoracic Surgery.* 2007; 31: 1052-1057.