

Case Report

Mechanical Aspiration of a Heavy Thrombus in the Left Anterior Descending Artery using Penumbra Aspiration Catheter

Ubaid Khan¹; Adnan Raufi²; Diao Hakim^{3*}¹School of Medicine, King Edward University, Lahore, Pakistan²Department of Cardiology, Westchester Medical Center, Valhalla, New York, USA³Department of Cardiology, Brigham and Women's Hospital, Harvard Medical School, Boston, USA***Corresponding author: Diao Hakim, MD, PhD, FESC**

Brigham and Women's Hospital, 1620 Tremont Street, Boston, MA, 02120, USA.

Tel: (617) 732 4860

Email: dhakim1@bwh.harvard.edu

Received: June 20, 2023**Accepted:** July 24, 2023**Published:** July 31, 2023

Introduction

Left anterior descending artery thrombosis is a medical emergency that requires prompt intervention to achieve the best possible clinical outcomes [1]. Early recanalization of obstructed vessels and thrombectomy with subsequent stenting effectively restore blood flow and improve procedural outcomes [2]. However, Manual Aspiration Thrombectomy (MAT) using a flexible aspiration catheter is also an alternative method that can be used to open blocked vessels [3]. Recent advancements in aspiration catheters have improved their trackability and size, making them comparable in efficacy to SBT [4]. As a result, Stent-Based Thrombectomy (SBT) and mechanical aspiration thrombectomy have become the primary treatment options for endovascular therapy in particular cases of coronary artery disease. The concurrent utilization of SBT and MAT as first-line and fallback interventions has been demonstrated to be effective in restoring vascular recanalization [5].

Besides SBT and MAT, a new aspiration catheter device has emerged. It is a relatively new technique for treating a thrombus in LAD that involves using a specialized catheter to remove the blood clot from the culprit artery [6]. This minimally invasive procedure is faster and more effective than traditional treatments such as thrombolytic therapy or Percutaneous Coronary Intervention (PCI) [7]. Penumbra medical technology company (Penumbra Inc, Alameda, CA, USA) introduced the Aspira-

tion System in 2014 [8]. This system is specifically designed to remove blood clots from veins and arteries in the "peripheral vasculature" as well as for the treatment of "pulmonary embolism" [9]. The CAT family of catheters, developed by Penumbra, is known for its robustness, trackability, and atraumatic design, making it well-suited for peripheral anatomy where a thrombus forms [10]. The system comes equipped with the "Penumbra ENGINE aspiration source," which can administer almost untainted and consistent vacuum to catheters. This proficiency enables the extraction of thrombus in vessels of assorted dimensions.

Recently, a penumbra aspiration catheter was used in a case report to remove thrombosis in acute coronary syndrome. According to the findings presented in this case report, it can be deduced that the Penumbra CAT RX catheter represents a secure and remarkably efficient alternative for eliminating blood clots in urgent scenarios. Notably, this method mitigates the heightened vulnerability to stroke often associated with the conventional approach of manual aspiration thrombectomy [11]. Previously, penumbra reperfusion catheter and MAT have been used as a "first-line therapy," and SBT with a "Solitaire stent" as a rescue therapy since 2012. This approach showed promising results regarding vessel recanalization and clinical outcomes [12].

Case Report

A 45-year-old male with a medical history significant for type 2 diabetes mellitus, hyperlipidemia, hypertension, and chronic heavy cigarette smoking was admitted to the hospital with a complaint of chest pain lasting for one day. Upon admission, an Electrocardiogram (ECG) showed T-wave inversion in leads V1-V3, and hs-Troponin was elevated. An echocardiogram was performed, which revealed significant hypokinesia in the antero-septal walls. The decision was made to undergo cardiac catheterization to investigate the patient's condition further.

Coronary angiography showed a large caliber ectatic Left Anterior Descending (LAD) artery occluded by a thrombus (Figure 1). Despite difficulties wiring the LAD, the involved segment was successfully ballooned escalated, restoring TIMI-3 flow. An ectatic segment that is just distal to the involved segment was also noted, studded with a thrombus, resulting in a very hazy picture. Although attempts were made to aspirate the thrombus using an Export catheter (Medtronic, MN, USA), it was unsuccessful. The decision was then made to medically manage the patient for 24-48 hours before attempting the procedure again.

The patient was started on intravenous Tirofiban and, after approximately 36 hours, was brought back to the Cath lab. An improvement in the haziness of the mid-segment Left Anterior Descending Artery (LAD) picture was noted, with TIMI-3 flow remaining. Intravascular Ultrasound (IVUS) confirmed the presence of an ectatic segment with a large amount of mobile thrombus (Figures 2 & 3).

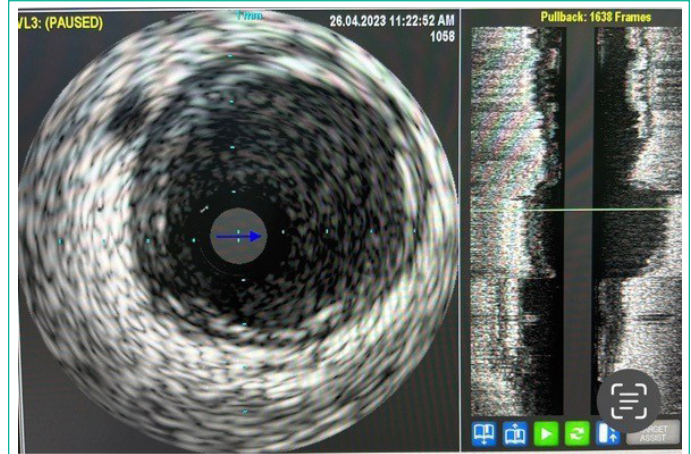


Figure 3: Baseline IVUS image showing ectatic segment (Arrow).

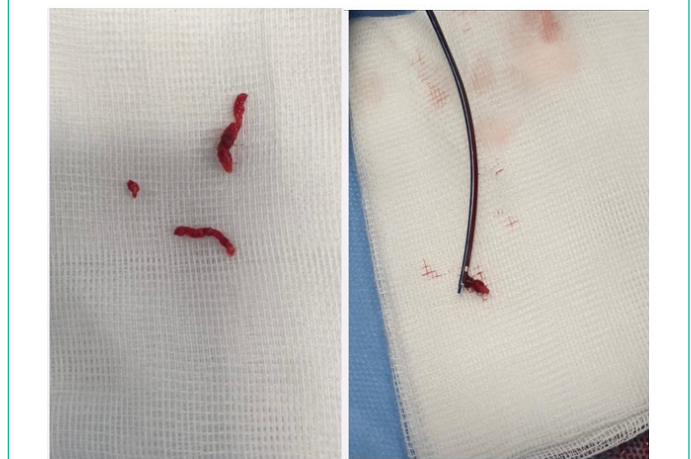

Figure 4: Thrombus aspiration using Pnumbra.

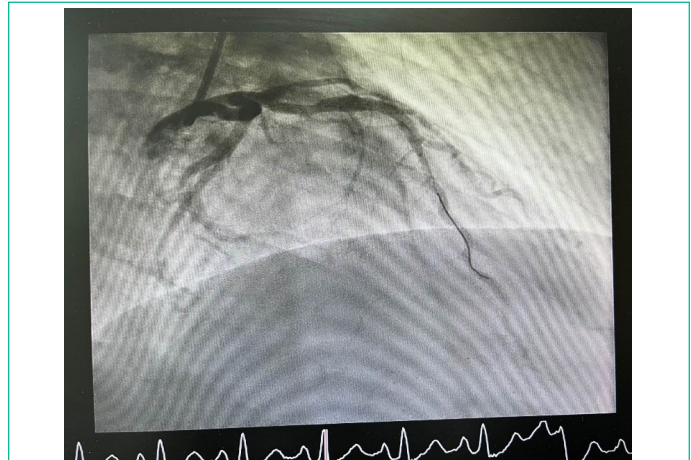


Figure 5: Coronary angiography post stenting.

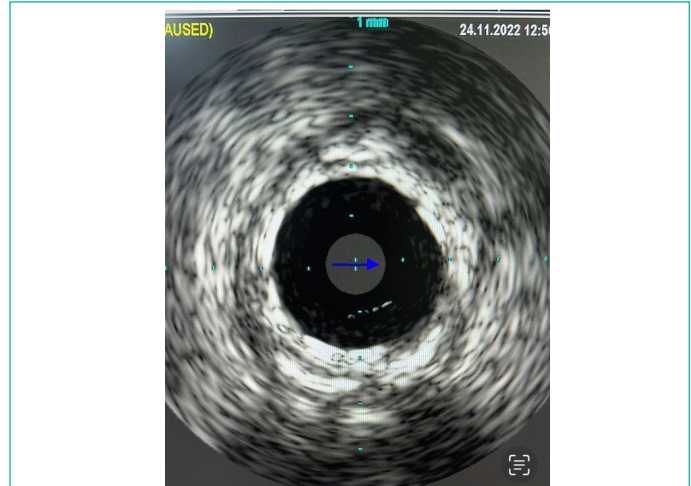


Figure 6: Post stenting IVUS.

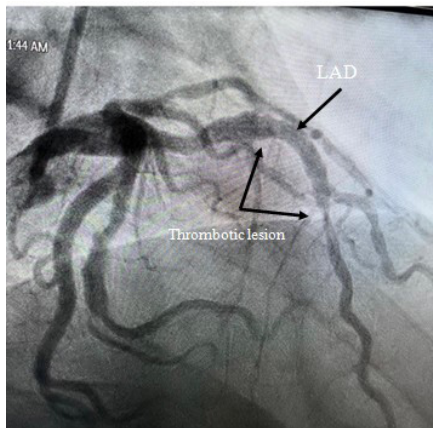


Figure 1: Baseline Coronary Angiography showing the Thrombotic lesion in the LAD.

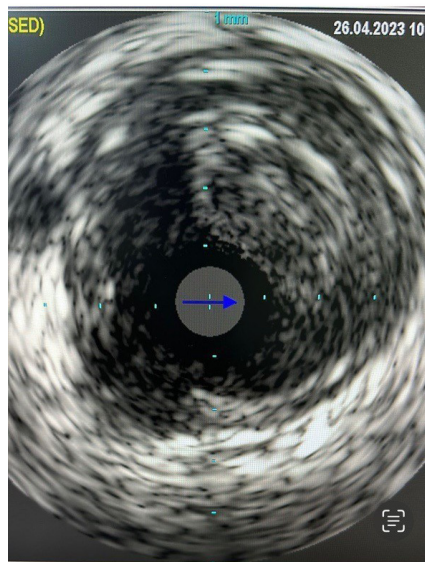


Figure 2: Baseline IVUS image showing a large thrombus (Arrow).

A Penumbra aspiration catheter was used, and after multiple passes, all the thrombus was aspirated.

(Figure 4), the stent was deployed, then repeat coronary angiography and IVUS demonstrated no haziness, and there was no evidence of distal embolization (Figures 5 & 6).

The patient tolerated the procedure well without any complications. Due to the heavy thrombus burden, the decision was made to leave him on a triple regimen consisting of low-dose aspirin, clopidogrel, and a Novel Oral Anticoagulant (NOAC) for one week, followed by the continuation of clopidogrel and NOAC. The patient was advised to refrain from smoking and to make lifestyle modifications, including strict control of his diabetes. The patient was seen in the clinic and reported to be doing well.

Discussion

This case report describes a case of a 45-year-old male patient with a medical history of type 2 diabetes, hyperlipidemia, hypertension, and chronic heavy smoking, who was admitted to the hospital with chest pain. The patient exhibited T-wave inversion in ECG leads V1-V3 and elevated hs-Troponin levels. Further evaluation revealed significant hypokinesia in the anteroseptal walls on the echocardiogram. Cardiac catheterization identified a totally occluded and ectatic left anterior descending artery with thrombus formation. Despite initial challenges in thrombus removal, a subsequent procedure utilizing aspiration catheter techniques successfully resolved the thrombus burden. The patient was prescribed a triple regimen of low-dose aspirin, clopidogrel, and a novel oral anticoagulant, along with lifestyle modifications and strict diabetes control.

This case report presents our experience utilizing “mechanical aspiration thrombectomy” with the Penumbra CAT RX system for the management of thrombus in the Left Anterior Descending artery (LAD). Our case demonstrated significant clinical benefit, as evidenced by a remarkable improvement in the blood flow of LAD. The Penumbra aspiration catheter has also been employed in various reported cases [13]. In a related case series involving ST-Elevation Myocardial Infarction (STEMI) patients, in each patient, a notable quantity of blood clots was observed within their respective affected blood vessels. Interestingly, half of these involved vessels were in the Right Coronary Artery (RCA), which interventional cardiologists speculate may be attributed to the RCA's larger caliber and slower blood flow than the LAD. Moreover, the RCA's fewer side branches maintain proximal patency and limit distal flow runoff, as seen in the LAD.

In this case, the “Penumbra CAT RX system” was highly effective in removing a significant thrombus burden. Of all the cases, only one instance was unsuccessful in achieving “TIMI 2 or 3” flow restoration. The medical team suspected that the thrombus in this specific case was likely embolic in nature, originating from “atrial fibrillation rather than forming within the “native vessel”, which could have contributed to its difficulty in removal. Overall, this collection of cases established that mechanical thrombectomy demonstrates a favorable safety profile, as no instances of cardiovascular mortality or stroke were reported within 30 days [13].

According to the literature, the technique of aspiration thrombectomy, endorsed with a class IIb recommendation, relies on evidence derived from studies involving manual aspiration thrombectomy using syringes of small volume (30 ccs) [14].

However, it is important to acknowledge that manual aspiration techniques are limited. One such limitation is the diminishing efficiency of aspiration as the syringe becomes filled with fluid. This decrease in aspiration effectiveness could impact the overall efficacy of the procedure and elevate the risk of systemic embolization during catheter withdrawal. These factors may help elucidate the slight rise in stroke incidence observed in previous randomized trials, such as TOTAL [15]. Notably, the “constant vacuum” provided by the “Penumbra CAT RX system” appears to mitigate the risk of embolization [16]. No post-procedural strokes were reported in our case report and other initial retrospective reports.

Similarly, in another case report, a patient exhibited a localized blockage in the radial artery at the wrist level, accompanied by a severely atherosclerotic ulnar artery that displayed minimal detectable blood flow [17]. The “ACE Penumbra catheter system (Penumbra)” was utilized to perform “suction embolectomy” on the “distal radial artery”. The successful management of this case highlights the effectiveness of the Penumbra device in such scenarios.

The efficacy of the Penumbra aspiration device in the management of ischemic stroke has already been well established [18,19]. Additionally, multiple case reports have documented the successful application of Penumbra devices in the resolution of basal stent occlusion and cerebral venous thrombosis [20]. The Penumbra device presents itself as a hopeful alternative for patients who are unable to undergo surgical interventions or when thrombolysis is contraindicated or not beneficial.

Conclusion

This case report highlights the successful utilization of the Penumbra CAT RX system for mechanical aspiration thrombectomy in the management of thrombus within the left anterior descending artery. The clinical benefit observed in the dramatic improvement of the LAD supports the efficacy of aspiration thrombectomy as a treatment option. This case report adds to the growing body of evidence supporting the use of Penumbra devices in the management of complex thrombotic cases. Further studies and clinical trials are warranted to validate these findings and expand our understanding of the optimal approach for thrombus removal in coronary artery disease.

References

1. Kuipers RS, Paes AJ, Amoroso G, Riezebos RK. Thrombosis within the left anterior descending coronary artery and left ventricle after high-dose nitrous oxide use. *BMJ Case Rep.* 2022; 15.
2. Seners P, Turc G, Maier B, Mas JL, Oppenheim C, et al. Incidence and predictors of early recanalization after intravenous thrombolysis: a systematic review and meta-analysis. *Stroke.* 2016; 47: 2409-12.
3. Saver JL, Goyal M, Bonafe A, Diener HC, Levy EI, et al. Stent-retriever thrombectomy after intravenous t-PA vs. t-PA alone in stroke. *N Engl J Med.* 2015; 372: 2285-95.
4. Jankowitz B, Grandhi R, Horev A, Aghaebrahim A, Jadhav A, et al. Primary manual aspiration thrombectomy (MAT) for acute ischemic stroke: safety, feasibility and outcomes in 112 consecutive patients. *J NeuroIntervent Surg.* 2015; 7: 27-31.
5. Kim YS, Kwak HS, Chung GH, Hwang SB. Manual aspiration thrombectomy using the Penumbra catheter in patients with acute M1 occlusion: A single-center study. *Interv Neuroradiol.* 2015; 21: 694-9.

6. Deshaies EM. Tri-axial system using the solitaire-FR and Penumbra Aspiration microcatheter for acute mechanical thrombectomy. *J Clin Neurosci*. 2013; 20: 1303-5.
7. Hussain SI, Zaidat OO, Fitzsimmons BF. The Penumbra system for mechanical thrombectomy in endovascular acute ischemic stroke therapy. *Neurology*. 2012; 79: S135-41.
8. Park JS, Kwak HS. Manual aspiration thrombectomy using penumbra catheter in patients with acute M2 occlusion: a single-center analysis. *J Korean Neurosurg Soc*. 2016; 59: 352-6.
9. Fujimoto M, Tateshima S, Ali L, Raychev R, Vinuela F. Direct thrombus aspiration using the Penumbra system for the treatment of pediatric intracranial dissection. *J NeuroIntervent Surg*. 2013; 5: e43.
10. Byon JH, Kwak HS, Chung GH, Jang KY. Acute stroke from tumor embolus in a patient with cardiac sarcoma: aspiration thrombectomy with Penumbra catheter. *Interv Neuroradiol*. 2016; 22: 88-90.
11. Gilchrist IC Jr, Fordham MJ, Pyo R, Reilly JP, Chen O. Mechanical aspiration thrombectomy using the penumbra CAT RX system for patients presenting with acute coronary syndrome. *Cardiovasc Revasc Med*. 2022; 40S: 316-21.
12. Turk AS, Frei D, Fiorella D, Mocco J, Baxter B, et al. ADAPT FAST study: a direct aspiration first pass technique for acute stroke thrombectomy. *J NeuroIntervent Surg*. 2018; 10: i4-7.
13. Gilchrist IC, Fordham MJ, Pyo R, Reilly JP, Chen O. Mechanical aspiration thrombectomy using the penumbra CAT RX system for patients presenting with acute coronary syndrome. *Cardiovasc Revasc Med*. 2022; 40S: 316-21.
14. Turk AS, Siddiqui A, Fifi JT, De Leacy RA, Fiorella DJ, et al. Aspiration thrombectomy versus stent retriever thrombectomy as first-line approach for large vessel occlusion (COMPASS): a multicentre, randomised, open label, blinded outcome, non-inferiority trial. *Lancet*. 2019; 393: 998-1008.
15. Elgendy IY, Huo T, Bhatt DL, Bavry AA. Is aspiration thrombectomy beneficial in patients undergoing primary percutaneous coronary intervention? Meta-analysis of randomized trials. *Circ Cardiovasc Interv*. 2015; 8: e002258.
16. Sagheer S, Prejean S, Litovsky S, Watts T, Von Mering G, et al. Successful mechanical aspiration of embolized vessel fragment during TAVR with penumbra indigo cat Rx catheter. *J Invasive Cardiol*. 2021; 33: E315.
17. Oklu R, Ghasemi-Rad M, Irani Z, Brinegar KN, Toner E, et al. Aspiration thrombectomy using the penumbra catheter. *J Vasc Interv Radiol*. 2015; 26: 454-5.
18. Kim YW, Hwang YH, Kim YS, Kang DH. Frontline contact aspiration thrombectomy using Sofia catheter for acute ischemic stroke: period-to-period comparison with penumbra catheter. *Acta Neurochir*. 2019; 161: 1197-204.
19. Yoo AJ, Frei D, Tateshima S, Turk AS, Hui FK, et al. The penumbra stroke system: a technical review. *J NeuroIntervent Surg*. 2012; 4: 199-205.
20. Sandhaus M, Hiltner E, Shukla A, Sethi A. A novel approach to an acute watchman device related thrombus with penumbra aspiration catheter. *J Am Coll Cardiol*. 2023; 81: 3296.