

Research Article

Antidote Effect of Selenium against Endosulfan Induced Toxicity in Ovarian Cells of Mice

Sinha A¹, Sahay R¹, Kumar R², Ali M², Srivastava SK¹ and Kumar A^{2*}

¹Department of Zoology, Patna University, Patna, Bihar, India

²Mahavir Cancer Institute & Research Centre, Patna, Bihar, India

*Corresponding author: Arun Kumar, Mahavir Cancer Institute & Research Centre, Patna, Bihar-801505, India

Received: September 16, 2016; Accepted: October 17, 2016; Published: October 19, 2016

Abstract

In the recent times, indiscriminate use of pesticides has increased many folds. The farmers for the better yield of crops are utilizing the pesticides. Presently, these pesticides have caused health related problems in the population. It has led to hormonal imbalance in females leading to infertility. The present research work on animal deciphers the antidote effect of selenium in endosulfan induced reproductive toxicity in female mice.

Endosulfan at the dose of 3mg/Kg body weight was administered orally to female mice for respectively 1 week, 2 weeks & 4 weeks. Thereafter, selenium in the form sodium selenite at the dose of 10µg/Kg body weight was administered for 4 weeks to observe the ameliorative effect of it on ovarian cells. The study reveals that after the administration of endosulfan, there was significant damage at the sub cellular level in ovarian cells of mice along with hormonal imbalance. But, after administration of selenium, there was significant reversal at the sub cellular levels. The basic chelation property of selenium eliminates the deleterious toxicity of endosulfan denotes that it not only possesses antioxidant and rejuvenating property but also maintains the cellular integrity of the ovarian cells leading to normal functioning of it. It is one of the best antidote against endosulfan induced cellular toxicity.

Keywords: Endosulfan; Selenium; Hormonal imbalance; Mice; Electron microscopy

Introduction

Indiscriminate use of agrochemicals under conventional agriculture not only causes severe health hazards for human beings but also has numerous other side effects on the environment including destruction of the biodiversity. Endosulfan is an organochlorine insecticide effective against a wide range of pests of cereals, coffee, cotton, fruits, oilseeds, potato, tea and vegetables. Moreover, it is easily absorbed by the stomach, lungs and skin and exposure through any route can be hazardous. Commercially produced endosulfan consists of two isomers α - endosulfan and β - endosulfan. Both these forms have been proved to be genotoxic to human gonads [1,2].

Pesticide safety is classified by the World Health Organisation (WHO) according to the results of LD₅₀ tests, which document the amount of a chemical required to kill 50% of a population of laboratory rats. Under this system, endosulfan is currently classified as Class II – moderately hazardous to human health. However, the United States' Environmental Protection Agency (EPA) rates endosulfan as Category Ib – highly hazardous [3]. LD₅₀ data for endosulfan are in conformity with some published results indicating that the chemical should be in the WHO's Class Ib, according to the organization's own criteria. Evidence of the threats to human health posed by endosulfan are abundant, and the chemical has been banned outright or severely restricted in a number of countries as a result. Independent of LD₅₀ results, these threats warrant the immediate upgrading of endosulfan to WHO Class Ib [4].

Endosulfan has been associated with estrogenic activity both *in*

vivo and *in vitro* [5]. Exposure to this pesticide produces persistent vaginal estrous and anovulation in rats treated neonatally [6,7].

Micronutrients are dietary minerals required by the human body in a very small quantity. They basically interact with xenobiotics at several sites like during absorption and excretion, transport of metals in the body, binding to target proteins, metabolism and sequestration of toxic metals, and oxidative stress [8]. Besides this, they may also serve as required prosthetic groups in active sites or as co-enzymes for indispensable metalloenzymes. Several studies showed that antioxidant nutrients protect cells against deleterious effects of environmental agents [9]. Selenium has received considerable attention as an essential micronutrient for both animal and human beings. Therefore, in the present study Selenium has been used to observe its antidote efficacy against the pesticide endosulfan.

Materials and Methods

Animals

Swiss albino mice were bred at the Mice Room of Prof. A. Nath, Department of Zoology, Patna University, Patna, Bihar, India. The animals had free access to water and feed pellets (mixed formulated feed prepared by the laboratory itself).

The age of mice for the experiments was 12 weeks old. The average body weight of experimental mice was 30 + 2g.

Test chemical

Pesticide endosulfan, manufactured by Excel India Pvt. Ltd., Mumbai with EC 35% was utilized for the experiment.

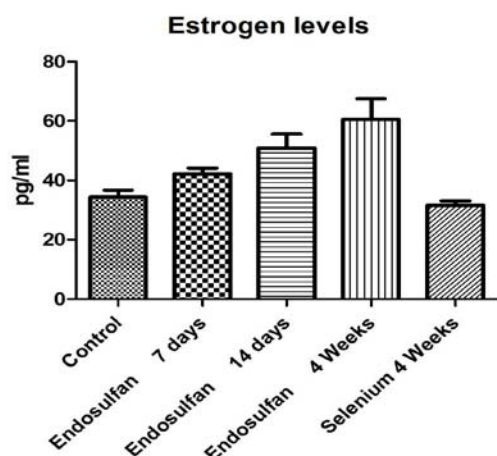


Figure 1: Showing Estrogen hormone levels in different groups in which selenium shows significant amelioration. The data are presented as mean \pm S.D, n = 6, significance at $P < 0.001$.

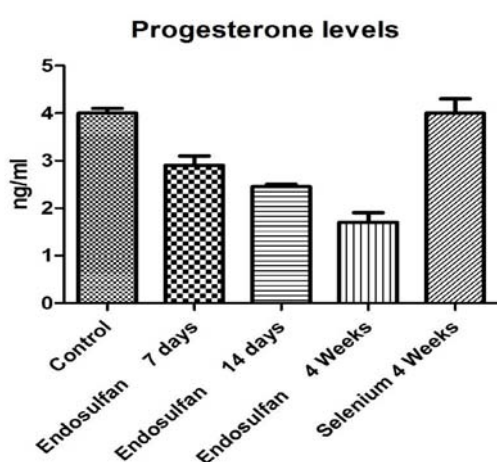


Figure 2: Showing Progesterone hormone levels in different groups in which selenium shows significant amelioration. The data are presented as mean \pm S.D, n = 6, significance at $P < 0.001$.

Preparation of selenium dose

In the present study, Selenium in the form of Sodium Selenite was procured from Himedia and dose of $10\mu\text{g}/\text{Kg}$ body weight was prepared for oral administration after estimation of LD_{50} value.

Study groups & sampling

The control group of mice received distilled water as drinking water. The 'treatment' groups received Endosulfan $3\text{ mg}/\text{kg}$ b.w daily by gavage method for 7 days, 14 days & 4 weeks followed by 4 weeks administration of Sodium selenite ($10\mu\text{g}/\text{Kg}$ body weight/day). Animals were sacrificed after the scheduled treatment. Serum was collected for estrogen & progesterone assay. The ovary from all the animals were removed and washed three times in isotonic saline (0.85 v/w %) and fixed in 2.5% glutaraldehyde for Transmission Electron Microscope (TEM) study.

Hormonal assay

Using the ELISA method Estrogen & Progesterone kit of LILAC Medicare (P) Ltd., Mumbai was utilized for the experiment.

Statistical analysis

Results are presented as mean \pm SD and total variation present in a set of data was analyzed through one way analysis of variance (ANOVA). Difference among mean values has been analyzed by applying Dunnett's test. Calculations were performed with the Graph Pad Prism Program (Graph Pad software, Inc., San Diego, U.S.A.). The criterion for statistical significance was set at $P < 0.05$.

Results

Estrogen level in control group was 37 ± 1.421 pg/ml. Estrogen level were 46 ± 1.103 pg/ml, 51 ± 2.873 pg/ml and 62 ± 4.215 pg/ml in endosulfan 1 week, 2 weeks and 4 weeks administered group respectively. While estrogen level of endosulfan 4 weeks followed by 4 weeks selenium was 34 ± 0.861 pg/ml (Figure 1).

Progesterone level in control group was 4.0 ± 0.352 pg/ml. Progesterone level were 2.9 ± 1.014 pg/ml, 2.5 ± 0.031 pg/ml and 1.8 ± 1.029 pg/ml in endosulfan 1 week, 2 weeks and 4 weeks administered group. While progesterone level of endosulfan 4 weeks followed by 4 weeks selenium was 4.1 ± 0.961 pg/ml (Figure 2).

Transmission Electron Micrographs of control ovary of mice showed double membrane of nucleus with normal chromatin material. Mitochondria as well as the ribosomes were distinct while mitochondrial cristae and lipid droplets were clearly visible with

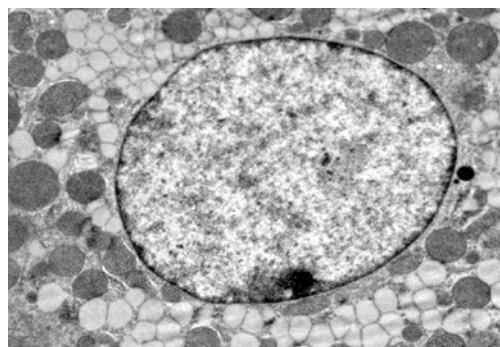


Figure 3: Transmission Electron Micrographs of Control ovary of mice showing normal architecture of double membrane of nucleus, chromatin material. Mitochondria as well as the ribosomes are very distinct. Mitochondrial cristae with lipid droplets are clearly visible (x 14,000).

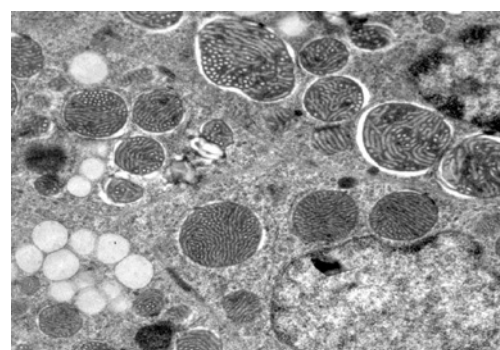


Figure 4: Transmission Electron Micrographs of ovary of mice treated with Endosulfan for 1 week showing nucleus with invagination. Dilated nuclear pore complex were observed with increased heterochromatinization. Dissolved plasma membrane is clearly visible with vacuolated spaces. Degeneration in mitochondria are clearly visible (x 22,000).

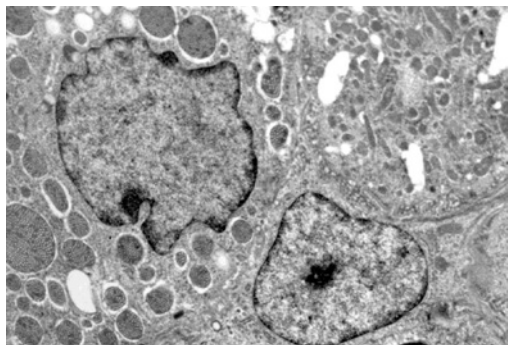


Figure 5: Transmission Electron Micrographs of ovary of mice treated with Endosulfan for 2 weeks showing degenerated and deshaped nucleus. Mitochondrial membrane was fragmented. Wavy nuclear membrane was clearly visible. Heterochromatinised elongated nucleus with patch like nucleolus and dilated nuclear pore complex are clearly observed. RER are in highly degenerated condition (x 14,000).

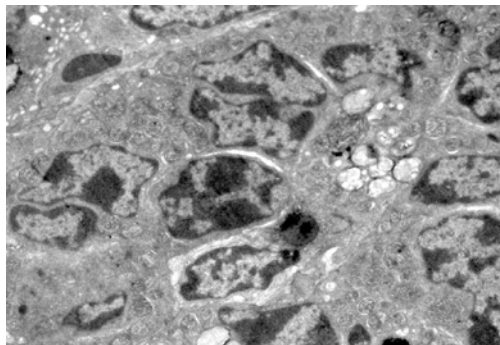


Figure 6: Transmission Electron Micrographs of ovary of mice treated with Endosulfan for 4 weeks showing nucleus in degenerated condition. Nuclear pore complex is highly dilated. Nucleolus is not prominent. Lipid droplets are increased in the cytoplasmic region. Rudimentary plasma membrane are also observed (x 14,000).

normal endoplasmic reticulum (Figure 3). Ovary of mice treated with Endosulfan for 1 week showed nucleus with intact nuclear membrane with dilated nuclear pore complex with increased heterochromatinisation. Dissolved plasma membrane was clearly visible with vacuolated spaces and dilation in nuclear pore complex with degeneration in mitochondria (Figure 4). Ovary of mice treated with Endosulfan for 2 weeks showed degenerated and deshaped nucleus. Mitochondrial membrane was highly degenerated in mitochondria. Wavy nuclear membrane with heterochromatinised elongated nucleus was observed. The nuclear pore complex was dilated at many places. Rough endoplasmic reticulum and mitochondria were in highly degenerated condition (Figure 5). Endosulfan 4 weeks treated ovary showed nucleus in highly degenerated condition. Nuclear pore complex were highly dilated while nucleolus were not prominently observed. Lipid droplets were highly increased in the cytoplasmic region while rudimentary plasma membrane was observed (Figure 6). Endosulfan 4 weeks followed by Selenium 4 weeks administered ovary showed normal shape of nucleus with mitochondria and rough endoplasmic reticulum. Mitochondria with mitochondrial cristae were restored to normal in structure. Double membrane of nucleus was observed denotes recovery in cells (Figure 7).

Discussion

Pesticide causes oxidative stress [10] reported that endosulfan and chlorpyrifos administration suppressed the estradiol concentrations in neonatal female rats. But we observed elevated level of estrogen in endosulfan administered mice. Endosulfan causes lots of health hazards including hepatic, renal and reproductive disorders [11]. Endosulfan may cause decrease in semen quality, increase in testicular and prostate cancer and an increase in defects in male sex organs [12]. Biochemical changes in endosulfan treated testes of rats was observed by [13]. Endosulfan treatment in pubertal rats inhibits testicular functions [14]. Endosulfan administered mice showed degeneration of germinal epithelium to the greater extent. Large vacuolated spaces were also observed in mature Graafian follicle. Degeneration in corpus luteum was also evident. Serrated double membrane of nucleus was observed in ovary. Vacuolization in mitochondria was observed. Polyribosome was also observed. Degenerated nuclear membrane was evident. Nuclear fragmentation was also observed

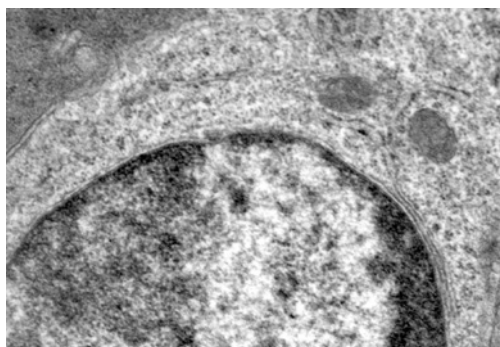


Figure 7: Transmission Electron Micrographs of ovary of mice treated with Endosulfan for 4 weeks followed by Selenium administered for 4 weeks showing normal shape of nucleus with mitochondria and RER. Mitochondria with mitochondrial cristae are clearly visible. Double membrane of nucleus is clearly visible denotes recovery in cells (x 35,000).

with degenerated mitochondria.

Selenium in the recent times has proven its efficacy as a good antioxidant. Selenium is a vital element and its crucial role is underlined by the fact that it is the only trace element to be specified in the genetic code, as selenocysteine, which when incorporated into selenoproteins, protects tissues and membranes from oxidative stress and controls cell redox status [15]. The functions of many of the twenty-five human selenoproteins are as yet unknown, although they generally participate in antioxidant and anabolic processes [16]. A recent systematic review and meta-analysis of antioxidant supplements for the prevention of gastrointestinal cancers has assessed the evidence for an effect of selenium. It acts as an antioxidant and helps protect the body against the damaging effects of free radicals [17]. Data from three Chinese trials were included, two of which used selenised yeast [18]. In our study, selenium maintains both estrogen and progesterone levels in mice as it normalises the hormonal imbalance. It is essential for the activity of glutathione peroxidase, an enzyme that protects against reactive oxygen species and subsequent cell membrane damage and is an integral part of more than about 30 known proteins. [19,20].

In the present study, selenium restores the sub-cellular structure of the ovary in mice very effectively, proving that it possesses an antidote effect against endosulfan-induced toxicity at the hormonal level as well as at the sub-

cellular level. The primary nutritional role of selenium in regulating the redox state and energy metabolism involves its incorporation as selenocysteine, the 21st amino acid, into selenoproteins. Selenium potentially affects cancer development through its known effects on oxidative stress, DNA repair, inflammation, apoptosis, proliferation, carcinogen metabolism, testosterone production, angiogenesis, fat metabolism, and immune function [21]. The basic mechanism is the glutathione and thioredoxin antioxidant systems which function to regenerate other antioxidants while themselves providing the primary antioxidant defense in the water phase of the body. Glutathione peroxidase and thioredoxin reductase are two natural antioxidant enzymes that contain selenium and depend upon selenium activity for their antioxidant functionality. Both the glutathione and thioredoxin systems enhance their own antioxidant activity by inducing the production of other natural antioxidant enzymes [22]. Probably, this defence mechanism of selenium plays the vital role to combat the deleterious effect of endosulfan at the sub cellular as well as hormonal level.

Conclusions

Therefore, from the present study it can be concluded that selenium restores at hormone levels as estrogen, progesterone and at sub cellular level of ovary of mice exposed to endosulfan. It possesses antidote effect against endosulfan induced toxicity.

References

- Helle RA, Marie VA, Thomas HR, Marianne GI, Eva CBJ. Effects of Currently Used Pesticides in Assays for Estrogenicity, Androgenicity, and Aromatase Activity *in Vitro*. *Toxicology and Applied Pharmacology*. 2002; 179: 1-12.
- Agency of Toxic Substances and Disease Registry, Toxicological Profile for Endosulfan. 2000.
- World Health Organization. The WHO Recommended Classification of Pesticides by Hazard. 2005.
- EPA, Reregistration Eligibility Decision for Endosulfan. 2002.
- Bretveld R W, Thomas CM, Scheepers PT, Zielhuis GA, & Roeleveld N. Pesticide exposure: the hormonal function of the female reproductive system disrupted?. *Reproductive Biology and Endocrinology*. 2006; 4: 30.
- Gellert RJ. Kepone, mirex, dieldrin, and aldrin: estrogenic activity and the induction of persistent vaginal estrus and anovulation in rats following neonatal treatment. *Environ Res*. 1978; 16: 131-138.
- Safe SH. Environmental and dietary estrogens and human health: is there a problem? *Environ Health Perspect*. 1995; 103: 346-351.
- Miller S, Walker SW, Arthur JR, Nicol F, Pickard K. Selenite protects human endothelial cells from oxidative damage and induces thioredoxin reductase. *ClinSci*. 2001; 100: 543-550.
- El-Demerdash FM. Antioxidant effect of vitamin E and selenium on lipid peroxidation, enzyme activities and biochemical parameters in rats exposed to aluminium. *J Trace Elem Med Biol*. 2004; 18: 113-122.
- Ahmad MM, Maqsood Ahmad M, SarvatSaleha. Effects of endosulfan and chlorpyrifos on the reproductive organs and sex hormones of neonatal rats. *Pakistan Journal of Zoology*. 1993; 25: 11-14.
- Sinha P, Verma P, Kumar A, Nath A. Testicular atrophy in mice *Mus musculus* under sublethal doses of endosulfan. *J Ecophysiol & Occup Hlth*. 2004; 4: 191-196.
- Hileman B. Environmental estrogens linked to reproductive abnormalities. *Cancer, C & EN*. 1994; 19-23.
- Sinha N, Narayan R, Saxena DK. Endosulfan induced biochemical changes in the testes of rat. *Vet Hum Toxicol*. 1995; 37: 547-549.
- Chitra KC, LatChoumycandane C and Mathur PP. Chronic Effect of endosulfan on the testicular function of rat. *Asian Journal of Andrology*. 1999; 1: 203-206.
- Hatfield DL, Gladyshev VN. How selenium has altered our understanding of the genetic code. *Molecular and Cell Biology*. 2002; 22: 3565-3576.
- Maroni M, Colosio C, Ferioli A, Fait A. Biological monitoring of pesticide exposure: a review. *Introduction. Toxicology*. 2000; 143: 1-118.
- Uchendu C, Ambali SF, Ayo JO, Esievo KAN. Acetyl-L-carnitine attenuates haemotoxicity induced by subacute chlorpyrifos exposure in wistar rats. *Der Pharm Let*. 2011; 3: 292-303.
- Bjelakovic G, Nikolova D, Simonetti RG, Gluud C. Antioxidant supplements for prevention of gastrointestinal cancers: a systematic review and meta-analysis. *Lancet*. 2000; 364: 1219-1228.
- Yu SY, Zhu YJ, Li WG. Protective role of selenium against hepatitis B virus and primary liver cancer in Qidong. *Biological Trace Element Research*. 1997; 56: 117-124.
- Jameson RR. and Diamond AM. Regulatory role for-Sec tRNA[Ser]Sec in selenoprotein synthesis. *RNA*. 2004; 10: 1142-1152.
- Rayman MP. The importance of selenium to human health. *Lancet*. 2000; 356: 233-241.
- Taylor PR, Parnes HL, Lippman SM. Science peels the onion of selenium effects on prostate carcinogenesis. *JNCI J Natl Cancer Inst*. 2004; 96: 645-647.