

Research Article

Distribution and Morphological Pattern of Intracranial Aneurysm in Patient with Subarachnoid Haemorrhage in a Tertiary Care Hospital of Bangladesh

Hasan MN^{1*}, Hoque MA², Rahman KM², Masum AA¹, Khandaker MN³ and Alim MA⁴

¹Department of Internal Medicine, Bangabandhu Sheikh Mujib Medical University (BSMMU), Bangladesh

²Department of Neurology, National Institute of Neuroscience, Bangladesh

³Department of Physical medicine, BSMMU, Bangladesh

⁴Institute of Public Health Nutrition, Bangladesh

*Corresponding author: Hasan MN, Department of Internal Medicine, Bangabandhu Sheikh Mujib Medical University (BSMMU), Bangladesh

Received: May 18, 2017; Accepted: June 07, 2017;

Published: June 14, 2017

Abstract

A cross-sectional observational study was carried out to evaluate the distribution and morphological anatomy of cerebral vessels in patients with aneurysmal subarachnoid hemorrhage in the department of neurology, Dhaka medical college hospital, Bangladesh from January 2013 to January 2014. A total of 30 patients aged more than 18 years of age with spontaneous subarachnoid haemorrhage, diagnosed clinically and confirmed by computerized tomography scan of the head and cerebral spinal fluid were included in the study. The mean (\pm SD) age of the patients was 45.0 (\pm 9.4) years with a male predominance (60%). The common site of aneurysm was anterior communication artery (36.7%) followed by middle cerebral artery (26.7%) and posterior communicating artery (23.3%). Only single basilar top aneurysm was found. Over half (53.3%) of the aneurysms was of medium-sized (5 – 12 mm). Saccular aneurysms were common as was observed in present study (93%) irrespective of its anatomical location. Neck-size of the aneurysm showed 87% narrow necked, while the rest 13% had wide neck. In conclusion aneurysmal subarachnoid haemorrhage, aneurysms were mainly located in anterior communicating and middle cerebral arteries and of medium-sized. Majority were saccular type and narrow-necked. Surgeon or physician should consider the morphological pattern and distribution of intracranial aneurysm to manage them effectively.

Keywords: Subarachnoid haemorrhage; Intracranial aneurysm; Digital subtraction angiography; Bangladesh

Introduction

Subarachnoid Hemorrhage (SAH) may occur spontaneously, usually from a ruptured cerebral aneurysm [1]. Evidence shows that cerebral aneurysm is responsible for 70 to 75% of spontaneous SAH [2]. Saccular aneurysm is responsible for 85% of SAH. The frequency of aneurysms of an adult without particular risk factors is 2.3% [3]. The anterior circulation of brain contains approximately 85% of aneurysms [4]. Saccular aneurysms occurs at the sites of arterial bifurcation and anterior communicating artery (30%) is the most common site followed by posterior communicating artery (25%) and middle cerebral artery (20%) [5]. Most intracranial aneurysm never ruptures although risk increases with the size of aneurysm but paradoxically most ruptures occur in small aneurysm which is less than 10 mm [6]. In patients with no history of SAH, where the five-year cumulative rate of rupture of aneurysms located in the internal carotid artery and anterior cerebral circulation (anterior communicating artery, anterior cerebral artery, or middle cerebral artery) is zero for aneurysms under 7 mm, 2.6 percent for 7 to 12 mm, 14.5 percent for 13 to 24 mm, and 40 percent for 25 mm or more. In contrasts with rupture rates is of 2.5 percent, 14.5 percent, 18.4 percent, and 50 percent, respectively, for the same sizes of aneurysms in the posterior circulation [6]. As an aneurysm develops, it typically forms a neck with a dome. The length of the neck and the size of the dome vary greatly and are important factors in planning neurosurgical obliteration or endovascular embolization [4].

Therefore, it is important to determine the site and morphology of cerebral aneurysm to predict the risk of rupture and take a decision about the neurosurgical management.

Materials and Methods

This was a cross-sectional observational study carried out in the department of neurology, Dhaka medical college hospital, Bangladesh from January 2013 to January 2014. A total of 30 patients were included in the study. The inclusion criteria were: adult (\geq 18 years) patients of spontaneous SAH detected clinically and by CT scan of head in both sex, financially capable of doing Digital Subtraction Angiography (DSA) and who gave consent to take part in the study. The patient with traumatic SAH, intracerebral haemorrhage, patients taking antiplatelet and anticoagulant drugs, and patient with comorbid conditions were excluded from the study.

Before commencement of the study, ethical approval was obtained from the Bangladesh Medical Research Council. After enrolment all the patients underwent DSA. DSA is the procedure consists of injecting a contrast medium into the arterial system rendering this normally radiolucent structure into a radio-opaque structure. Two-dimensional (2D) film is then developed yielding resolution comparable to plain radiographs. This technique is capable of providing information on both large and small-vessel pathology [7,8]. Having obtained an informed consent history was noted and thorough physical examination especially neurological examinations

Table 1: Socio-demography of patients (n = 30).

Characteristics	Frequency	Percentage	Mean
Age (years)			45.0 ± 9.4
≤ 20	1	3.3	
21 – 30	1	3.3	
31 – 40	6	20.0	
41 – 50	16	53.4	
> 50	15	20.0	
Sex			
Male	18	60.0	
Female	12	40.0	

Table 2: Distribution of patients by anatomical location of aneurysm (n= 30).

Anatomical location	Frequency	Percentage
Anterior communicating artery	11	36.7
Middle cerebral artery	8	26.7
Posterior communicating artery	7	23.3
Internal carotid artery	1	3.3
Top of the basilar artery	1	3.3

were carried out by the investigator himself. Before reaching a final diagnosis, consultation was done with a neurologist. A history of unconscious patients was taken from their attendants. The patients of SAH were diagnosed on the basis of clinical features and findings of computerized tomography scan of head and some cases by lumbar puncture. Investigations like complete blood count, serum lipid profile, blood sugar, serum creatinine, electrocardiography, chest X-ray were also done. Then DSA was performed via a femoral arterial approach by interventional neurologists in the cath lab of Dhaka medical college hospital. Identification of aneurysm sites and measurement of their size were done. Aneurysmal size ≤ 4 mm was considered as small, 5-12 mm as medium and ≥ 13 mm as large [7]. Morphology of the aneurysms was assessed. Presence of any pseudo-sac or any embryological variations was also assessed. Size of the neck of aneurysms was also measured. Each patient was evaluated immediately and 6 hours after DSA for any post-procedural complications. Data were collected using a semi-structured questionnaire containing the variables of interest. Using computer software SPSS (Statistical Package for Social Sciences) (version 20.0), data were processed and analysed. The test statistics used to analysis the data were descriptive statistics. Analysed data were presented in the form of table and graphs with due interpretation.

Results

A total of 30 patients were included in the study. Of them, over half (53.4%) was in their 4th decade of life. The median (±SD) age of the patients was 45.0 (±9.4) years and the youngest and oldest patients were 18 and 59 years, respectively. Male patients were predominant with 60% over female with 40% (Table 1).

Among all patients 36.7% of the patients had aneurysm in the anterior communication artery, 26.7% in the middle cerebral artery and 23.3% in the posterior communicating artery. Internal carotid artery and top of the basilar artery were involved in only 1 patient

Table 3: Distribution of patients by size of the aneurysm (n = 30).

Size (mm)	Frequency	Percentage
≤ 4	9	30.0
5 – 12	12	53.3
≥ 13	5	16.7

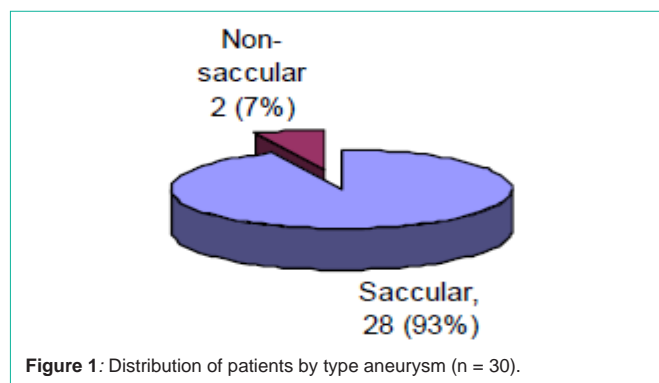


Figure 1: Distribution of patients by type aneurysm (n = 30).

(Table 2).

In terms of size of the aneurysm, 53.3% were medium sized between 5 – 12 mm, 30% were 4 or < 4 mm and 16.7% were 13 or > 13 mm, which is shown in the (Table 3).

Saccular aneurysm constituted majority (93%) of the cases. Only 7% were non-saccular type (Figure 1). Among them 87% were of narrow neck and 13% patient had wide neck.

Discussion

Morphology and distribution pattern of intracranial aneurysm is important to know before manage them effectively. The present study demonstrated that 80% of the patients were younger than 50 years old with a male preponderance (60%). Although the incidence increased with age, studies have shown that half the patients were younger than 55 years at the time of subarachnoid haemorrhage, which is somewhat consistent with our study. However, a female preponderance of the disease has been seen in several studies [9]. The medical records of all residents of Olmsted county Minnesota with a view to find the population-based incidence and prevalence rates of intracranial saccular aneurysm showed a total 348 intracranial aneurysms were detected among 270 persons during the 31-year period. There were 105 male subjects (39%) and 165 female subjects (61%) [10]. But our study shows almost reverse with male preponderance (60%) and the reason may be due to geographic variation and small sample size.

Saccular aneurysms are the most common type as was observed in present study (93%) irrespective of its anatomical location. Other literature also proved that saccular aneurysms are the commonest (85%) type of aneurysm which is consistent with our study [5]. Our study revealed the common site of aneurysm was anterior communication artery (36.7%) followed by middle cerebral artery (26.7%) and posterior communicating artery (23.3%). Internal carotid artery and top of the basilar artery were seldom involved. Over half (53.3%) of the aneurysms was of medium-sized (5 – 12 mm). This findings are in accordance with the other study outcome like saccular aneurysms occurs at anterior communicating artery (30%) was the most common site followed by posterior communicating

artery (25%) and middle cerebral artery (20%) [5]. The frequency at which saccular aneurysms are found in the general population depends on the definition of size. Most intracranial aneurysms will never rupture. The rupture risk increases with the size of aneurysm, but paradoxically, most ruptured aneurysms are small-i.e., less than 1 cm; the explanation for this paradox is that 90% of all aneurysms are small and the small fraction of this majority that ruptures outnumber the greater fraction of the minority of large aneurysms that ruptures [6]. Although small sample size is one of the limitations of our study, it demonstrated the distribution and important morphology of SAH.

Conclusion

From the findings of the study it can be concluded that in aneurismal subarachnoid haemorrhage, aneurysms are mainly located in anterior communicating and middle cerebral arteries and of medium-sized. Majority are saccular type and narrow-necked. Patients are usually middle-aged (younger than 50 years) and predominantly female. Surgeon or physician should consider the morphological pattern and distribution of intracranial aneurysm to manage them effectively.

Acknowledgement

We are thankful to all the staffs in ward and cath lab of Dhaka medical college hospital, who helped us to accomplish the study.

References

1. Ropper AH, Samuels MA. Cerebrovascular disease in Adams and Victor's Principles of Neurology. New York: McGraw- Hill. 2009; 9: 808-809.
2. Kenneth W, Ian L, Geraint BF. Subarachnoid haemorrhage in Neurology and Neurosurgery illustrated. London: Elsevier. 2010; 5: 276.
3. Rinkel GJE, Djibuti M, Algra A, van GJ. Prevalence and risk of rupture of intracranial aneurysm: a systematic review. Stroke. 1998; 29: 251-256.
4. Kasper DL, Fauci AS, Haucser SL, Longo DL, Jameson JL, Loskalzo J. Subarachnoid haemorrhage in Harrison's Principle of Internal Medicine. 19th edition, McGraw-Hill: New York 2015:1784.
5. Colledge NR, Walker BR, Ralston SR. Subarachnoid haemorrhage in Davidson's Principle and Practice of Medicine. London: Elsevier. 2010; 21: 1190-1191.
6. Wiebers DO, Whisnant JP, Huston J III. Unruptured intracranial aneurysms: natural history, clinical outcome, and risks of surgical and endovascular treatment. Lancet. 2003; 362: 103-110.
7. Korogi Y, Takahashi M, Katada K. Intracranial aneurysms: detection with three-dimensional CT angiography with volume rendering-comparison with conventional angiographic and surgical findings. Radiology. 1999; 211: 497-506.
8. Anderson C, Anderson R, Bonita R. Epidemiology of aneurismal subarachnoid haemorrhage in Australia and New Zealand: incidence of case fatality from Australian Cooperative Research on Subarachnoid Haemorrhage Study (ACROSS). Stroke. 2004; 35: 2059-2063.
9. Gijn J, Kerr RS, Rinkel GJE. Subarachnoid haemorrhage. Lancet. 2007; 369: 306-318.
10. Menghini VV, Brown RD, Sicks JD, O'Fallon WM, Wiebers DO. Incidence and prevalence of intracranial aneurysms and haemorrhage in Olmsted County, Minnesota, 1965 to 1995. Neurology. 1998; 51: 405-411.