

Clinical Image

Multisite Onset of Mechanical Contraction in Extensive Damage of His-Purkinje Conduction System

Federico Ferrando-Castagnetto^{1*}, Roberto Ricca-Mallada¹, Alvaro Rivara¹ and Rodolfo Ferrando²

¹Cardiology Department, University Cardiovascular Center, School of Medicine, Universidad de la República, Montevideo, Uruguay

²Nuclear Medicine Division, Centro Asistencial del Sindicato Médico, Montevideo, Uruguay

*Corresponding author: Federico Ferrando-Castagnetto, University Cardiovascular Center, Hospital de Clínicas p.2, Av. Italia s/n. Montevideo, Uruguay

Received: December 07, 2015; Accepted: January 15, 2016; Published: January 20, 2016

Clinical Image

A 69-years-old woman with past history of non-reperused myocardial infarction, chest pain and dyspnea was referred to 99m-Tc MIBI gated-SPECT myocardial perfusion imaging. A) Masquerading Bundle-Branch Block (MBBB). B) Anterior and apical perfusion defect, telesystolic volume=71ml, LVEF=42%. Left ventricle (LV) mechanical dyssynchrony was evaluated through Sync Tool (Emory Cardiac Toolbox™). C) Multisite onset of mechanical contraction (red arrows) was detected freezing video-images of contractile expansion in 17-segments polar map at early systole. D) Rest phase histogram: peak amplitude=134.00o, standard deviation=60.71o, bandwidth=205.00o. MBBB is an unusual conduction disorder associated with cavity enlargement, fibrotic blockthrough anterolateral wall and severe systolic dysfunction. Large clinical trials demonstrated that extended myocardial scar predict a suboptimal response to biventricular pacing and poor prognosis, but did not describe impacts of this therapy in MBBB subjects. Our findings suggest a fully distorted site of onset of mechanical contraction could be installed even before severe systolic dysfunction develops.

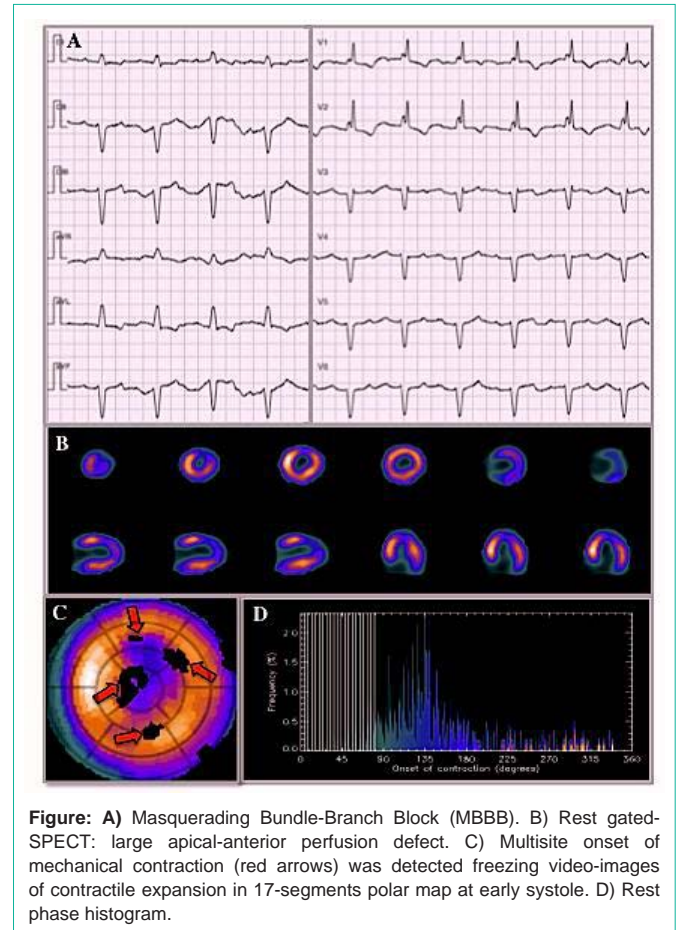


Figure: A) Masquerading Bundle-Branch Block (MBBB). B) Rest gated-SPECT: large apical-anterior perfusion defect. C) Multisite onset of mechanical contraction (red arrows) was detected freezing video-images of contractile expansion in 17-segments polar map at early systole. D) Rest phase histogram.