

## Case Report

# Simple Partial Status Epilepticus Presenting As Left Sided Hemiparesis

Vijaya Raj Bhatt<sup>1</sup>, Madan Raj Aryal<sup>2\*</sup>, Paras Karmacharya<sup>2</sup> and Nicole Shonka<sup>1</sup>

<sup>1</sup>Department of Internal Medicine, Division of Hematology-Oncology, University of Nebraska Medical Center, USA

<sup>2</sup>Department of Internal Medicine, Reading Health System, USA

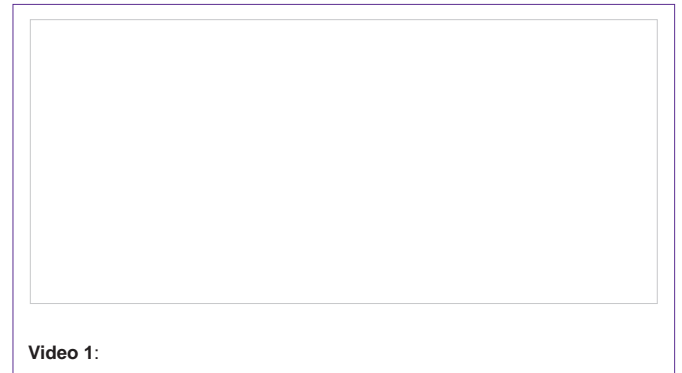
**\*Corresponding author:** Vijaya R. Bhatt, MBBS, Division of Hematology-Oncology, Department of Internal Medicine, University of Nebraska Medical Center, 987680 Nebraska Medical Center, Omaha, NE 68198-7680, USA

**Received:** May 01, 2014; **Accepted:** May 12, 2014;

**Published:** May 14, 2014

## Simple Partial Status Epilepticus

A 77-year-old man presented to emergency department with complaints of acute onset left-sided hemiparesis which lasted for less than an hour. Medical history was significant for isocitrate dehydrogenase 1 wild-type high grade glioma diagnosed approximately 3 months ago. He had undergone concurrent chemotherapy with temozolomide and intensity modulated radiation therapy. Ten days prior to the presentation, the patient had received first dose of bevacizumab for symptomatic progression. Examination revealed mild hemiparesis and numbness of left upper and lower extremities. Magnetic resonance imaging of brain showed stable T2 hyperintense lesions involving the right parieto-occipital cortex and right temporo-occipital cortex; and no evidence of increased peri-tumoral edema. Two hours after admission, the patient was found to have continuous involuntary rhythmic contraction of his left upper extremity without any change in mental status (video 1). An electroencephalogram (EEG) confirmed the diagnosis of simple partial status epilepticus. The patient received intravenous lorazepam and levetiracetam and was placed on continuous EEG monitoring. Over the next few days, antiepileptic regimen was optimized. Patient's hemiparesis improved with resolution of seizures and he was discharged to rehabilitation facility on stable condition. This case illustrates the subtle nature of the simple partial status epilepticus and emphasizes that Todd's paralysis should be considered in the differential diagnosis of focal weakness particularly in patients with structural brain lesions.



## Discussion

Epileptic seizures are common in patients with brain tumors with its incidence depending on the histopathological type of tumor [1,2]. It is more common in gliomas, where it can be the only symptom [1]. Seizures may present as a non-convulsive status epilepticus or at times as subtle simple partial status epilepticus. Rarely, it can be followed by postictal Todd's paralysis [3]. As in our case: this condition must be recognized as it can mimic a neurological worsening due to other reasons, such as stroke or progression of the tumor or peri-tumoral edema. EEG monitoring may help diagnose the status epilepticus in a few cases [1].

## Learning Points

1. It is important to recognize the subtle nature of the simple partial status epilepticus.
2. Todd's paralysis should be considered in the differential diagnosis of focal weakness particularly in patients with structural brain lesions.

## References

1. Cavaliere R, Farace E, Schiff D. Clinical implications of status epilepticus in patients with neoplasms. *Arch Neurol*. 2006; 63: 1746-1749.
2. Casazza M, Gilioli I. Non-convulsive status epilepticus in brain tumors. *Neurol Sci*. 2011; 32: S237-239.
3. Yano H, Shinoda J, Hara A, Shimokawa K, Sakai N. Chordoid meningioma. *Brain Tumor Pathol*. 2000; 17: 153-157.