

Case Report

Methicillin-Sensitive *Staphylococcus Aureus* Bacteremia Secondary to a Prostate Abscess in Healthy 19-Year-Old Male

Sangarlangkarn A¹ and Villanueva MS^{2*}¹Department of Medicine, Mt. Sinai School of Medicine, USA²Department of Medicine, Yale University School of Medicine, USA***Corresponding author:** Villanueva MS, Department of Medicine, Section of Infectious Disease, Yale University School of Medicine, 135 College St., Suite 323, New Haven, CT, 06511, USA**Received:** May 30, 2014; **Accepted:** June 12, 2014;**Published:** June 14, 2014

Case Presentation

A 19-year-old male presented with 3 days of fever, headache and abdominal discomfort accompanied by pain and tingling in his scrotum while voiding. Past medical history included brain arteriovenous malformation status post gamma knife. He underwent bilateral hydrocele/inguinal hernia repair as a child. He had no history of diabetes, intravenous drug use or immunodeficiency. He had intermittent facial acne and furunculosis. He was sexually active but denied anal intercourse; he had no history of Sexually Transmitted Infections (STIs). He denied recent digital rectal exam or trauma to the genital area; he was an avid bicyclist but had no recent prolonged bike rides. There was no history of urinary problems. He was a nursing student.

On admission, temperature was 103.3; blood pressure 120/70, heart rate 118, respiratory rate 26 and oxygen saturation 96% on room air. On physical exam, lungs were clear and cardiac exam showed no murmur. The abdomen was soft and non-tender; digital rectal exam was not performed. The scrotum was mildly tender to palpation. Laboratory testing on admission showed white blood count of 18.6 cells/mm³. Urinalysis revealed positive leukocyte esterase along with 20-30 white blood cells and 10-20 red blood cells per high-power field. Chest radiograph was normal.

Admission blood and urine cultures were positive for *Staphylococcus Aureus* susceptible to Oxacillin (MSSA). The patient was started on intravenous Oxacillin. On hospital day 2, he developed pleuritic chest pain. Chest radiograph showed new non-cavitating nodular opacities in both lower lobes. Transesophageal echocardiogram revealed no valvular vegetations. Renal ultrasound revealed no focal lesions. HIV testing was negative. Urine testing for gonorrhea and chlamydia was negative. Because of persistent fevers and bacteremia after 48 hours on appropriate antibiotics, computer tomography of the chest/abdomen/pelvis with intravenous contrast was performed; this showed scattered bilateral pulmonary

Abstract

Prostate abscess caused by *Staphylococcus Aureus* is rare and is infrequently reported as a cause of persistent bacteremia. Previous reports were predominantly due to Methicillin-resistant *Staph aureus*, occurring in patients with diabetes, prolonged indwelling urinary catheters, instrumentation or trauma to the lower urinary tract. We report an unusual case of a healthy 19-year-old male with persistent Methicillin-sensitive *Staphylococcus aureus* bacteremia and septic pulmonary emboli from a prostate abscess in the absence of obvious risk factors.

Keywords: *Staph aureus* bacteremia; Prostate abscess; Methicillin sensitive *Staph aureus*; Methicillin resistant *Staph aureus*

nodules and a 4 x 2.5 cm tubular cystic structure in the prostate gland suggestive of prostate abscess with reactive left common iliac lymph node (Figure 1). He underwent cystoscopy and transurethral uprooting of the abscess. Cultures from the abscess grew MSSA with the same antibiotic susceptibilities as the blood culture isolate. Pathology revealed acute or chronic inflammation. Post-operatively, the fevers resolved. He was discharged home and completed 4 weeks of intravenous Oxacillin. Eight months later, an abdominal pelvic MRI scan showed resolution of the abscess.

Discussion/Conclusion

We report an unusual case of community acquired *Staph Aureus* Bacteremia (SAB) in a healthy young man that was secondary to a prostate abscess. While it is possible that the prostate abscess resulted from hematogenous seeding from another source, we were unable to define an alternative primary focus.

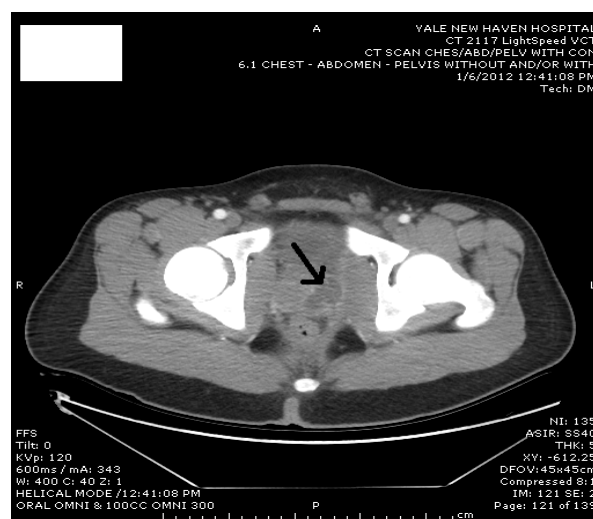


Figure 1: Abdominal pelvic CT scan demonstrating prostatic abscess (arrow).

Table 1: Reported Cases of Staph Aureus Bacteremia with Prostate Abscess.

Case	Age	Comorbidities	Urologic RF	GU symptoms	Complications	Duration bacteremia	Infecting Staph	Intervention and outcome
[1]	69	DM	Not reported	Irritative voiding	Endocarditis (mitral valve)	Not reported	MSSA	Transurethral drainage, recovered
[6]	63	DM, CAD, PVD	Prior scrotal abscess	Urinary retention, dysuria, perineal discomfort	None	13 days	MRSA	Incision and drainage, recovered
[10]	43	IVDU, HCV	Not reported	Hesitancy, slow stream, dysuria, perineal pain	None	10 days	MRSA	Transurethral resection prostate, recovered
[9]	56	DM	BPH, Self digital rectal exam	Hematuria, difficulty urinating	Perinephric abscess	5 days	MRSA	Transurethral drainage, recovered
[8]	53	DM, HTN, obesity	Not reported	Urinary urgency	None	12 days	MRSA	Recovered
[5]	40	HIV	MSM	Urinary hesitancy, weak stream, abdominal pain relieved by urination	None	6 days	MRSA	Transperineal drainage, recovered
[7]	45	DM	Not reported	Dysuria, perineal discomfort, rectal tenesmus	None	Not reported	MRSA	Percutaneous drainage, recovered
Current case	19	None	Previous bilateral hydrocele repair	Scrotal tingling	Septic pulmonary emboli	3days	MSSA	Transurethral drainage, recovered

DM= Diabetes Mellitus; MSSA= Methicillin-sensitive Staphylococcus Aureus; CAD= Coronary Artery Disease, PVD= Peripheral Vascular Disease; MRSA= Methicillin-resistant Staphylococcus Aureus; IVDU= Intravenous Drug Use; HCV= Hepatitis C Virus Infection; BPH= Benign Prostatic Hypertrophy; HIV= Human-Immunodeficiency Virus Infection; MSM= Men who have Sex with Men.

Prostate abscess has become a rare clinical entity since the development of effective antibiotic therapy. In the pre-antibiotic era, most cases were due to Neisseria gonorrhea or metastatic staphylococcal infection. More recently, cases have been associated with E. coli and other gram negative bacteria. The most common mechanism for abscess formation is reflux of infected urine into the prostatic ducts causing initial prostatitis, which when left untreated, can progress to prostate abscess. Predisposing factors include diabetes mellitus, chronic bacterial prostatitis, urologic instrumentation and indwelling urinary catheters, bladder outlet obstruction, HIV infection or chronic hemodialysis [1]. In the largest review of cases of prostate abscess from 1952-1986 by Weinberger et al. [2], cases of Staphylococcus Aureus (S. aureus) are rare, with the incidence reported to be as low as 6% of 109 cases. In a more recent series of 24 cases in India seen between 1999-2008, only 8% were due to S. aureus [3].

While prostate abscess caused by S. Aureus, particularly Methicillin-resistant S. Aureus (MRSA), have been previously reported, albeit rare [4], cases with concomitant bacteremia are more uncommon, with seven cases reported, predominantly in the urologic literature. These are summarized in Table 1.

The first case described a 69-year-old gentleman with diabetes [1]. Subsequent cases have all been reported in elderly men over the age of 40 with diabetes mellitus or other immunocompromised states [4-10]. All had urologic complaints upon presentation including perineal discomfort, dysuria, urinary retention, but only a few cases had identifiable inciting urologic events, such as prior incision and drainage of a scrotal abscess [6], unprotected sex with men [5] or self digital rectal exam [9]. One case reported by Hoffman et al [1] had resultant infective endocarditic, presumably originating from a

prostate abscess. All cases reported persistent bacteremia ranging from 2-13 days with intermittent to hectic fevers. All cases required surgical drainage for resolution of bacteremia. Most previously reported bacteremic cases were caused by community acquired MRSA. Our patient is the second case of prostate abscess that was caused by MSSA resulting in bacteremia. Unlike previous cases, this one occurred in a young healthy male without any immunocompromised state or other comorbidities. He had previously undergone hydrocele repair as a child but otherwise lacked the usual risk factors for prostate abscess. He had a history of facial furunculosis which may have predisposed him to colonization with S. aureus.

Clinical markers for complicated SAB include unidentifiable focus, positive blood cultures and persistent fevers 72 hours after admission, and time to positive blood culture less than 14 hours [11]. All previously reported bacteremic cases, including our patient met criteria for complicated SAB with persistent positive blood cultures and fevers despite appropriate antibiotic treatment. Furthermore, in our patient, we presume that the lung nodules seen on chest radiograph after admission were septic pulmonary emboli. Metastatic septic embolic phenomena have been reported in the setting of other pelvic infections, such as suppurative pelvic thrombophlebitis [12]. To our knowledge, this complication has not previously been reported from prostate abscess.

In summary, we report a case of SAB secondary to MSSA resulting from a prostatic abscess in a young healthy male. This entity is rare and mostly presents in elderly patients with underlying urological conditions and/or immunocompromised states. It should, however, also be considered in young healthy men who present with non-specific urologic symptoms and persistent, complicated SAB in the absence of another primary focus.

References

1. Hoffman MA, Steele G, Yalla S. Acute bacterial endocarditis secondary to prostatic abscess. *J Urol*. 2000; 163: 245.
2. Weinberger M, Cytron S, Servadio C, Block C, Rosenfeld JB, Pitlik SD, et al. Prostatic abscess in the antibiotic era. *Rev Infect Dis*. 1988; 10: 239-249.
3. Tiwari P, Pal DK, Tripathi A, Kumar S, Vijay M, Goel A, et al. Prostatic abscess: diagnosis and management in the modern antibiotic era. *Saudi J Kidney Dis Transpl*. 2011; 22: 298-301.
4. Deshpande A, Haleblan G, Rapose A. Prostate abscess: MRSA spreading its influence into Gram-negative territory: case report and literature review. *BMJ Case Rep*. 2013; 2013.
5. Chao BH, Kidd JM, Dow AW. Methicillin-resistant *Staphylococcus aureus* bacteremia due to prostatic abscess. *J Hosp Med*. 2009; 4: 9-11.
6. Fraser TG, Smith ND, Noskin GA. Persistent methicillin-resistant *Staphylococcus aureus* bacteremia due to a prostatic abscess. *Scand J Infect Dis*. 2003; 35: 273-274.
7. Park SC, Lee JW, Rim JS. Prostatic abscess caused by community-acquired methicillin-resistant *Staphylococcus aureus*. *Int J Urol*. 2011; 18: 536-538.
8. Beckman TJ, Edson RS. Methicillin-resistant *Staphylococcus aureus* prostatitis. *Urology*. 2007; 69: 779.
9. Tobian AA, Ober SK. Dual perinephric and prostatic abscesses from methicillin-resistant *Staphylococcus aureus*. *South Med J*. 2007; 100: 515-516.
10. Baker SD, Horger DC, Keane TE. Community-acquired methicillin-resistant *Staphylococcus aureus* prostatic abscess. *Urology*. 2004; 64: 808-810.
11. Khatib R, Riederer K, Saeed S, Johnson LB, Fakh MG, Sharma M, et al. Time to positivity in *Staphylococcus aureus* bacteremia: possible correlation with the source and outcome of infection. *Clin Infect Dis*. 2005; 41: 594-598.
12. Fred HL, Harle TS. Septic pulmonary embolism. *Dis Chest*. 1969; 55: 483-486.