

## Case Report

# Macular Schisis Cavities in Non-accidental Trauma

Koo EB, Bhisitkul RB and de Alba Campomanes AG\*

Department of Ophthalmology, University of California San Francisco, USA

\*Corresponding author: de Alba Campomanes AG, Department of Ophthalmology, University of California, San Francisco

Received: February 28, 2015; Accepted: March 23, 2015; Published: April 16, 2015

## Abstract

**Purpose:** To illustrate a severe case of bilateral macular schisis cavities in an infant caused by non-accidental trauma.

**Methods:** Observational case report of one patient.

**Results:** A 6-month old male admitted to the ICU after being found unresponsive at home presented with severe retinopathy related to non-accidental trauma. A subdural and subarachnoid hemorrhage complicated his course, and he ultimately died 2 days after admission.

**Conclusion:** We describe a case of bilateral retinopathy secondary to non-accidental trauma and illustrate severe macular schisis cavities using B-scan ultrasonography and fundus photos.

**Keywords:** Non-Accidental Trauma; Ultrasonography; Traumatic Retinopathy; Fundus Photography

## Introduction

The reported retinal findings in non-accidental trauma include intraretinal hemorrhages, nerve fiber layer hemorrhages, hemorrhages with a central white spot, and retinoschisis cavities with perimacular folds. We examined a patient with B-scan ultrasonography to further characterize bilateral macular schisis cavities in the setting of severe non-accidental trauma [1].

## Case Report

A previously healthy 6-month-old male was admitted to the pediatric intensive care unit after having been found unresponsive at home. On initial ophthalmologic examination, the patient was comatose and intubated. He had suffered a subdural and subarachnoid hemorrhage with significant cerebral edema necessitating an external ventricular drain. Pupils were symmetric, mid-dilated, and non-reactive. Anterior segment exam of both eyes was otherwise normal. The fundus exam exhibited numerous subretinal, intraretinal, and preretinal hemorrhages and large hemorrhagic posterior schisis cavities in both eyes (Figure 1). The images obtained by B-scan ultrasound (Figure 1) demonstrate the characteristics of these large schisis cavities. Based on the constellation of findings, a diagnosis of suspected non-accidental trauma was made.

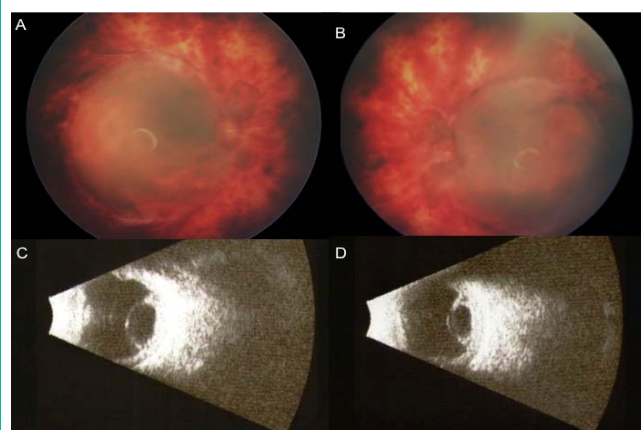
## Discussion

Retinal findings in the setting of non-accidental trauma have been widely described in the literature. The fundus finding of numerous retinal hemorrhages throughout the entire retina involving the preretinal, intraretinal, and subretinal space is the most common description and raises a high suspicion for non-accidental trauma [1]. The incidence of retinal findings in the setting of suspected non-accidental trauma ranges from 85 to 100% depending on the study design [2].

Specific retinal findings have been reported to be associated with more severe neurologic damage. In one consecutive series of 14 patients with presumed non-accidental trauma - all with varying

extents of retinal hemorrhages-, large subhyaloid hemorrhages, vitreous hemorrhage or more diffuse involvement of the retina was associated with a higher chance of significant neurologic damage [7]. Retinoschisis has also been associated with severe neurologic injuries. In one case series of patients with non-accidental trauma, 75% of the patients presenting with perimacular retinal folds (similar to those seen in this case) died. Other findings associated with higher mortality are nonreactive pupils and peripheral retinoschisis [8]. Similarly, in an autopsy series of 188 cases, 14 patients were reported to have bilateral macular schisis cavities [5]. The death of our patient with non-reactive pupils and large schisis cavities is consistent with these reports.

The most widely accepted hypothesis for retinopathy associated with non-accidental trauma including schisis cavities is that the repetitive shaking mechanism of the injury exerts vitreous traction on the retina and vasculature where vitreous is most firmly attached



**Figure 1:** A-B. The optic nerves were barely discernible amidst the extensive hemorrhage. The macula was notable for large hemorrhagic schisis cavities, which were well demarcated. C-D. The smooth dome-like contour, the abrupt boundaries, and significant height of these schisis cavities are illustrated here by B-scan ultrasonography. The vitreous remains adherent to the retina.

[4]. Advanced imaging techniques, like OCT, have confirmed the presence of vitreoretinal traction on the apices of the perimacular folds surrounding the schisis cavities [3]. In the previously mentioned autopsy study, the vitreous was found to be attached to the internal limiting membrane in those eyes with schisis cavities [5]. These reports are consistent with our finding of vitreous adherent to the macula; the vitreous-retinal interface can clearly be visualized at the edges of the macular schisis cavities on the B-scan (Figure 1). Other mechanisms that have been proposed include increased intracranial pressure, increased thoracic pressure and hypoxia [6]. However, these hypotheses are likely sequelae of the main injury caused by repetitive acceleration-deceleration and not actual causes of the retinopathy given the differences seen in retinopathies related to compressive head or chest traumas.

In conclusion, our ultrasonographic finding of vitreous adherent to schisis cavities corroborates previously reported OCT findings and the hypothesis that the vitreous is exerting significant traction on the retina during repetitive shaking. Consistent with the report of high mortality associated with these funduscopic findings, our patient also expired 2 days after admission. The severity of the patient's traumatic retinopathy strongly correlated with the severity of his intracranial injury and fore told his poor prognosis for survival.

## References

1. Morad Y, Wygnansky-Jaffe T, Levin AV. Retinal haemorrhage in abusive head trauma. *Clin Experiment Ophthalmol*. 2010; 38: 514-520.
2. Kivlin JD, Simons KB, Lazoritz S, Ruttum MS. Shaken baby syndrome. *Ophthalmology*. 2000; 107(7):1246-1254.
3. Sturm V, Landau K, Menke MN. Optical coherence tomography findings in Shaken Baby syndrome. *Am J Ophthalmol*. 2008;146(3):363-368.
4. Forbes BJ. Clues as to the pathophysiology of retinal hemorrhages in Shaken Baby syndrome determined with optical coherence tomography. *Am J Ophthalmol*. 2008;146(3):344-345.
5. Emerson MV, Jakobs E, Green WR. Ocular autopsy and histopathologic features of child abuse. *Ophthalmology*. 2007;114(7):1384-1394.
6. Levin AV. Retinal hemorrhage in abusive head trauma. *Pediatrics*. 2010;126(5):961-970.
7. Wilkinson WS, Han DP, Rappley MD, Owings CL. Retinal hemorrhage predicts neurologic injury in the shaken baby syndrome. *Arch Ophthalmol*. 1989;107(10):1472-1474.
8. Mills M. Funduscopic lesions associated with mortality in shaken baby syndrome. *J AAPOS*. 1998; 2(2):67-71.