

## Special Article - Cancer Clinical Cases and Images

# Chondromatosis of the Sternum

**Feng C\***

Department of Radiology and Anesthesiology, First Hospital of Jilin University, China

**\*Corresponding author:** Chunsheng Feng, Department of Anesthesiology, The First Hospital of Jilin University, China**Received:** October 13, 2015; **Accepted:** November 04, 2015; **Published:** November 06, 2015

## Keywords

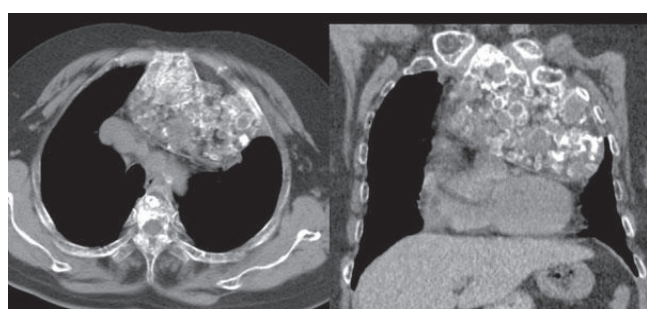Sternal tumors; Chondromatosis; Computed tomography

## Abbreviation

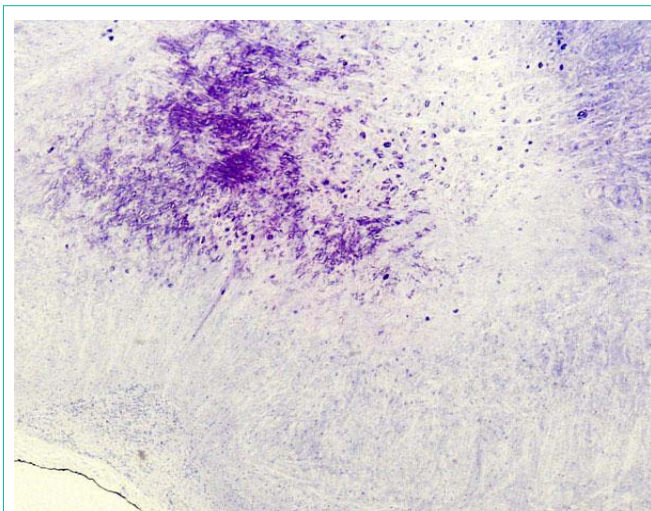
CT: Computed Tomography

## Clinical Image

A 62-year-old woman presenting with exertional shortness of breath for 18 months was admitted to our hospital. Chest CT showed Sternal tumor with circular calcification, shifting adjacent mediastinal structures (Figure1). Diagnostic biopsy of the lesion was indicative of



**Figure 1:** Chest axial and oblique reformatted CT images showed giant sternal mass with scattered circular or arc calcifications.



**Figure 2:** Pathological analysis from biopsy showed cartilaginous cells without cytologic atypia (HE stain $\times$ 40).

chondroma with no evidence of malignancy (Figure2). The patient refused any intervention.