

Case Report

Subclavian Artery Pseudoaneurysm Secondary to Accidental Stone Chip Injury and its Excision

Nagre SW*

Department of Cardiothoracic Surgery, Grant Medical College, India

*Corresponding author: Suraj Wasudeo Nagre, Department of Cardiothoracic Surgery, Grant Medical College, 31 seventh Floor, Trimurti Building, JJ Hospital Compound, Byculla, Mumbai, Pin: 400008, India

Received: April 06, 2016; Accepted: June 28, 2016;

Published: July 01, 2016

Abstract

A pseudoaneurysm, also known as a false aneurysm, is a hematoma that forms as a result of a leaking hole in artery. Hematoma was contained by the surrounding tissues. Also it must continue to communicate with the artery to be considered a pseudoaneurysm. Post stab injury Subclavian artery pseudoaneurysm is rare entity with great significance because of risk of complications like thrombosis, rupture, gangrene, limb loss and should be operated early whenever diagnosed. Our case report has 18 year male patient with history of accidental stone chip injury to left supraclavicular region followed by pulsatile swelling after five days due to Subclavian artery pseudoaneurysm. We excised pseudoaneurysm with direct closure of opening in Subclavian artery and removal of stone chip.

Keywords: Pseudoaneurysm; Stone chip injury; Subclavian artery; Pulsatile swelling

Introduction

According to the literature data, post traumatic pseudoaneurysm is rare entity [1]. Most common site is common femoral artery, followed by radial and brachial artery but Subclavian artery is very rare because trauma to it is rare. Incidence of complications associated with such pseudoaneurysm is estimated around 2–6% [2]. We present a case of the patient in whom pseudoaneurysm of left Subclavian artery developed after five days of accidental stone chip injury and was successfully treated by surgical excision of pseudoaneurysm and removal of stone chip with direct closure of opening in Subclavian artery.

Case Presentation

A 18- years-old male patient was admitted at our Institute with history of accidental injury to left supraclavicular region lateral side by stone chip while walking nearby to stone chipper (Figure 1A). After five days the patient noticed gradually increasing pulsatile swelling at injury site. Clinical examination revealed presence of pulsating mass at injury site of 12 by 12 cm in diameter. Left brachial radial and ulnar artery pulsations are palpable. Chest X-ray shown radiopaque stone chip below left clavicle (Figure 1B). Ultrasonography and CT angiography verified presence of pseudoaneurysm connected by opening in second part of left Subclavian artery (12cm in diameter) (Figure 2).

After short preoperative preparation, the patient underwent surgical intervention under general anesthesia. Left supraclavicular incision taken to access and loop the proximal Subclavian artery (Figure 3A,3B). Left side transaxillary incision taken to access and loop the axillary artery. Intravenous heparin (5000IU) was administered. Proximal Subclavian artery and axillary artery both clamped. Dissection and separation of pseudoaneurysm followed by excision was done with cautery along with its content the clotted blood (Figure 4A,4B). Stone chip causing trauma also removed. The

opening of pseudoaneurysm in left Subclavian artery was closed with prolene 6-0 directly. After putting 14 numbers negative suction

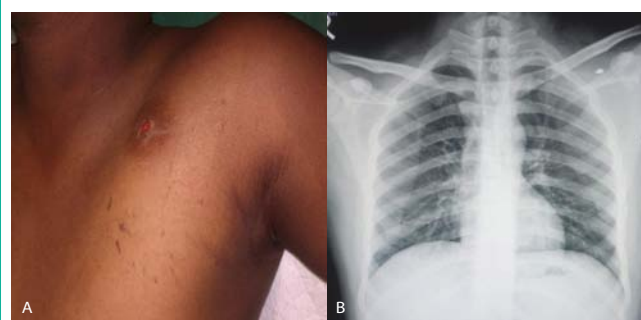


Figure 1: A) Entry wound in supraclavicular region due to stone chip. B) Chest X-ray showing radio opaque stone chip below left clavicle.

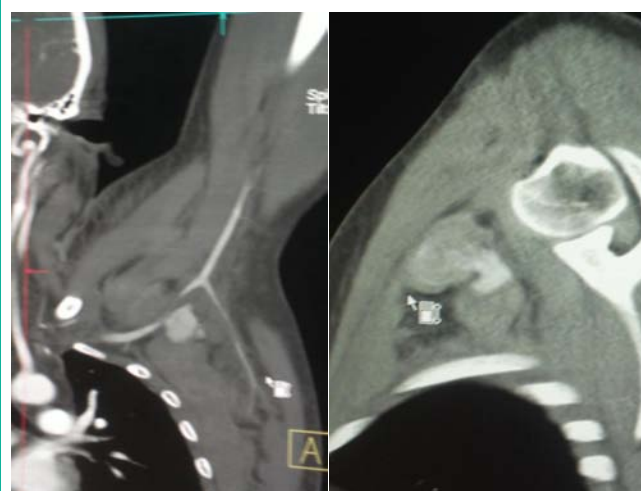

Figure 2: CT angiography showing subclavian artery pseudoaneurysm with openings in subclavian artery.

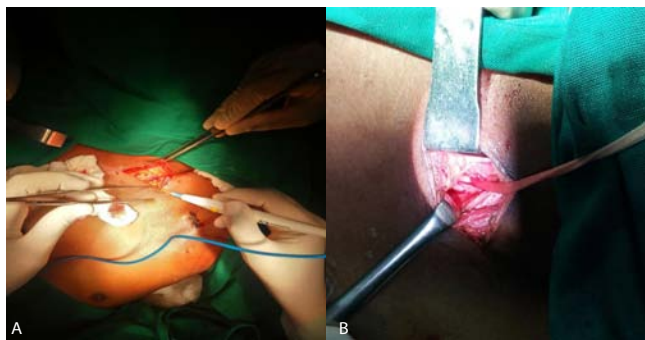


Figure 3: A) Supraclavicular incision to expose proximal subclavian artery. B) Exposed and looped subclavian artery.

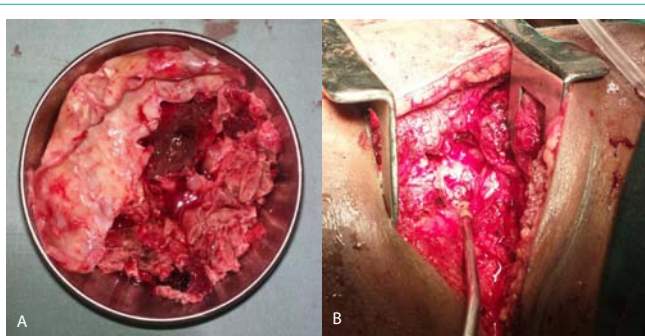


Figure 4: A) Excised pseudoaneurysm. B) Opening in subclavian artery closed directly by prolene 6-0.

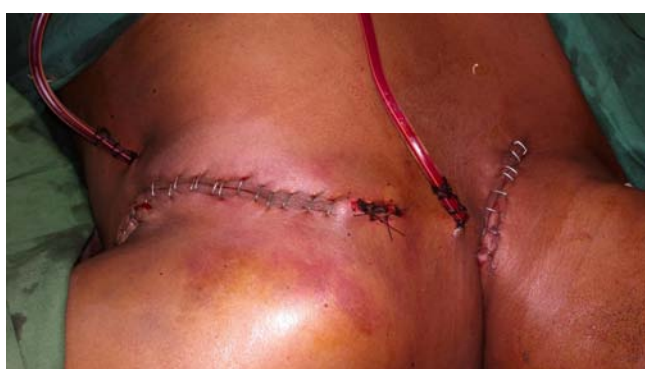

Figure 5: Closed tranaxillary and supraclavicular surgical incision with negative suction drain *in situ*.

romovac drain in supraclavicular and axillary region, wound closed in layer (Figure 5). Skin closed with stapler. Radial and ulnar artery pulsation checked. Drain removed after 48 hours. On the seventh postoperative day the patient was discharged.

Discussion

Post traumatic pseudoaneurysm is rare. The most common cause for such pseudoaneurysm is intragenic like post av fistula dialysis

needle puncture or invasive procedures like percutaneous coronary interventions. Most common site for such pseudoaneurysm are radial, brachial and common femoral artery. Post foreign injury pseudoaneurysm is rare in that Subclavian artery pseudoaneurysm was rare. If such pseudoaneurysm became infected, the surgical treatment can be extremely difficult.

Although recently published, meta-analyses showed no superiority of Subclavian artery stenting in such pseudoaneurysm because even after closing the opening which connect Subclavian artery with pseudoaneurysm, the already formed pseudoaneurysm is high risk of infection [3,4]. So excision of that pseudoaneurysm is must.

If the Subclavian artery is normal with clearly visible opening that connect with pseudoaneurysm then pseudoaneurysm can be excised without sacrificing the part of Subclavian artery by just direct or vein patch closure of that opening with prolene suture. Sometimes rarely excision of part of Subclavian artery with interposition grafting may be required.

Conclusion

The pseudo aneurysm excision was simple and safe even in inexperienced hands by proper anatomical knowledge. Proximal and distal control of artery is must for safe excision of pseudoaneurysm. By proper anatomical dissection pseudo aneurysm can be excised without damaging the surrounding vital structure like brachial plexus and axillary vein. Timely management was important to prevent complications like infection, rupture and gangrene. If the Subclavian artery is normal with clearly visible opening feeding pseudoaneurysm then pseudoaneurysm can be excised without sacrificing the part of Subclavian artery by just direct closure of opening in Subclavian artery with prolene. Sometimes rarely excision of part of Subclavian artery with interposition grafting may be required.

References

1. Sherev DA, Shaw RE, Brent BN. Angiographic predictors of femoral access site complications: implication for planned percutaneous coronary intervention. *Catheter Cardiovasc Interv.* 2005; 65: 196-202.
2. Muller DWM, Shamir KJ, Ellis SG, Topol EJ. Peripheral vascular complications after conventional and complex percutaneous coronary interventional procedures. *Am J Cardiol.* 1992; 69: 63-68.
3. Koreny M, Riedmüller E, Nikfardjam M, Siostrzonek P, Müllner M. Arterial puncture closing devices compared with standard manual compression after cardiac catheterization: systemic review and meta-analysis. *JAMA.* 2004; 291: 350-357.
4. Carey D, Martin JR, Moore CA, Valentine MC, Nygaard TW. Complications of femoral artery closure devices. *Catheter Cardiovasc Interv.* 2001; 52: 3-8.