

## Clinical Image

# Pseudo Bull's Eye Maculopathy

Chabbar Imane\*, Tamym Bouchra, Serghini Louai and Berraho Amina

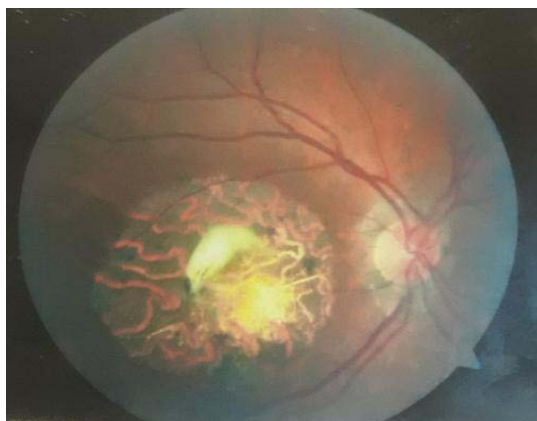Ophthalmology B, Ibn-Sina University Hospital, Morocco

\*Corresponding author: Imane Chabbar, Ophthalmology B, Ibn-Sina University Hospital, Morocco

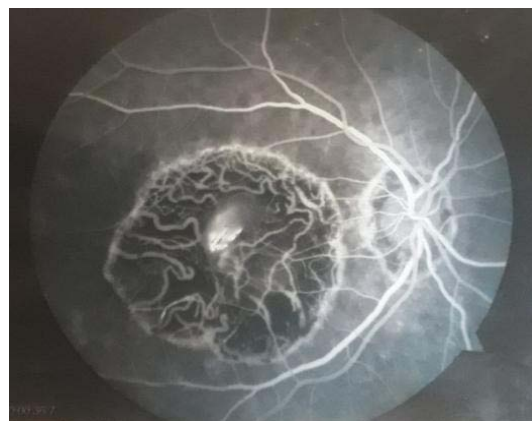
Received: October 27, 2020; Accepted: November 12, 2020; Published: November 19, 2020

## Clinical Image

Figure 1 having Color fundus photography showing a discolored rounded lesion of the macula with a yellowish background, with abnormal visibility of choroidal vessels and peripapillary atrophy. Figure 2 having Retinal fluorescein angiography showing an inhomogeneous macular lesion with gradual staining by window effect, corresponding to a macular atrophy with retinal pigment



**Figure 1:** Color fundus photography showing a rounded macular lesion with a yellowish background and abnormal visibility of choroidal vessels with peripapillary atrophy.



**Figure 2:** Fluorescein angiography showing a macular atrophy with retinal pigment epithelium degeneration.

epithelium degeneration. The bilateral and symmetrical character of this macular lesion, the young age of the patient and the pseudo bull's eye appearance make suspect a probable Stargardt Disease.