

## Clinical Image

# Bilateral Renal Metastasis Revealing an Adenocarcinoma of the Lung

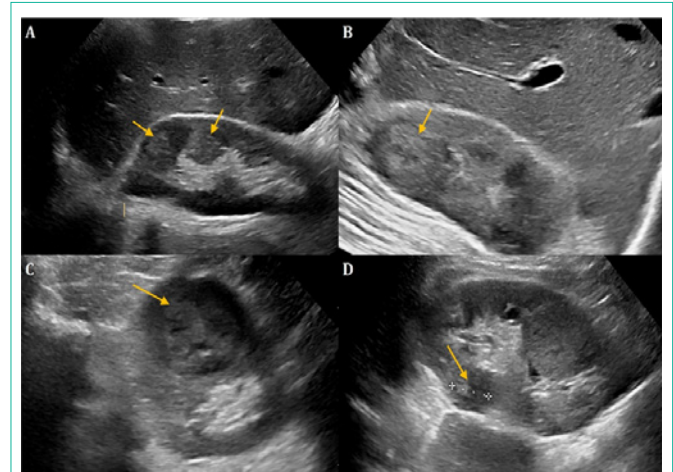
**Adil H\*, Jerguigue H, Latib R and Omor Y**

Department of Radiology, National Institute of Oncology, Mohammed V University, Rabat, Morocco

**\*Corresponding author:** Adil Hajar, Department of radiology, National Institute of Oncology, Mohammed V University, Rabat, Morocco**Received:** July 29, 2022; **Accepted:** August 18, 2022;**Published:** August 25, 2022

## Clinical Image

Lung cancer represents the first cause of death by cancer in the world, and adenocarcinoma is the most commonly histological subtype. Extra-thoracic metastasis of lung cancer is mostly encountered in the brain, the bone, the liver, as well as the adrenal gland. Hence, renal metastasis from lung cancer is extremely rare. They are usually asymptomatic; however, they may present with pain and hematuria. Renal metastasis usually presents as small, multiple, and bilateral, wedge-shaped masses, with endogenous growth. Although, some case reports documented unilateral, well circumscribed, exogenous mass simulating primary renal carcinoma. Thus, the definitive diagnosis requires histopathology examination after surgical resection or core needle biopsy.



**Figure 1:** Ultrasound images demonstrating multiple bilateral, echoic, wedge-shaped masses in a patient presenting with hematuria. A CT scan was performed and it demonstrated typical image of lung cancer. Histological findings after needle core biopsy confirmed the metastatic origin of the renal masses.