

Case Report

Accelerated Development of Brucellar Spondylitis after Halving the Dose of Oral Doxycycline and Rifamycin

Zhiqi Zhang³; Wendong Xie²; Jin Peng²; Weiwang Tuo²; Tao Guo²; Bo Liu^{1*}

¹Gansu Provincial Hospital, PR China

²Gansu University of Chinese Medicine, PR China

³Minle County Hospital of Traditional Chinese Medicine, Zhangye City, Gansu Province, PR China

*Corresponding author: Bo Liu

Gansu Provincial Hospital, No.204, DonggangWestRoad, Lanzhou, 730000, Gansu Province, PR China.

Email: liubo19993619696@163.com

Received: July 31, 2024

Accepted: August 16, 2024

Published: August 23, 2024

Abstract

Brucella spondylitis is a disease caused by Brucella infection, usually transmitted to humans through contact with infected animals or their products, which can lead to serious health problems, including long-term pain, fatigue and disability [1]. Currently, antibiotics are the mainstay of treatment for brucellosis spondylitis. Commonly used antibiotics include streptomycin, rifampicin, doxycycline, methotrexate/sulfamethoxazole, ciprofloxacin, and gentamicin, which accelerate the progression of brucellosis spondylitis by allowing Brucella to regrow and multiply again when given for an insufficient length of time and in insufficient doses [2]. When there is no improvement in symptoms after giving adequate duration and dose of antibiotics, surgical treatment is given.

Keyword: Brucella spondylitis; Halving of drug doses; Doxycycline and rifamycin; Surgical treatment; Relapse

Introduction

Antibiotic therapy is the mainstay of treatment for brucellosis spondylitis. Doxycycline and rifamycin are commonly used antibiotics for the treatment of the disease. These two drugs have powerful bactericidal effects and can effectively inhibit the growth and reproduction of Brucella. However, the accuracy of the drug dosage is critical to the effectiveness of the treatment. When oral doxycycline and rifamycin doses are halved, the concentration of the drugs decreases, which may result in the bacteria not being completely killed. In this case, some of the bacteria may become resistant to the drugs and continue to grow and multiply. Bacteria that are not completely eliminated continue to multiply in the body, which may lead to an aggravation of brucellar spondylitis. The disease progression is accelerated by an increase in the number of bacteria and the production of toxins. In addition, the bacteria multiply within the spine, which may lead to serious complications such as spinal deformities and neurological damage. Half-dose antibiotic treatment fails to kill the bacteria effectively, which may lead to recurrent disease. Long-term recurrent infections make the treatment of Brucella spondylitis more difficult and reduce the quality of life of patients.

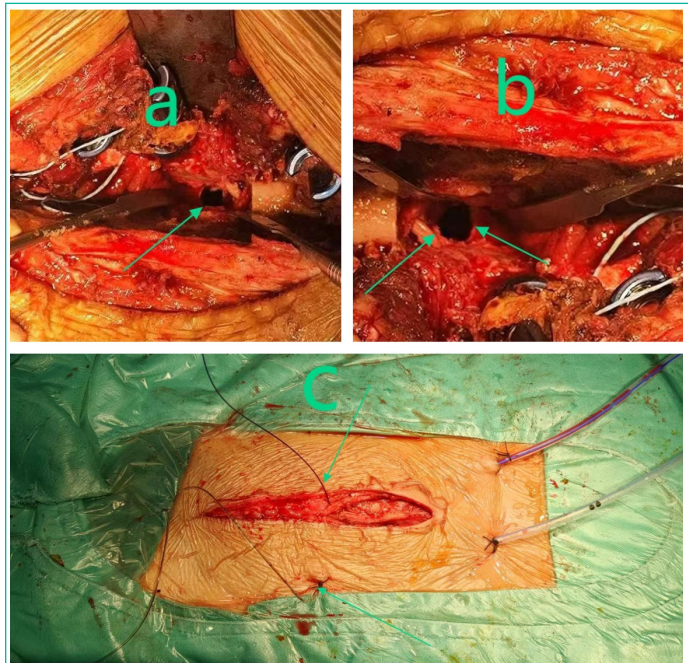
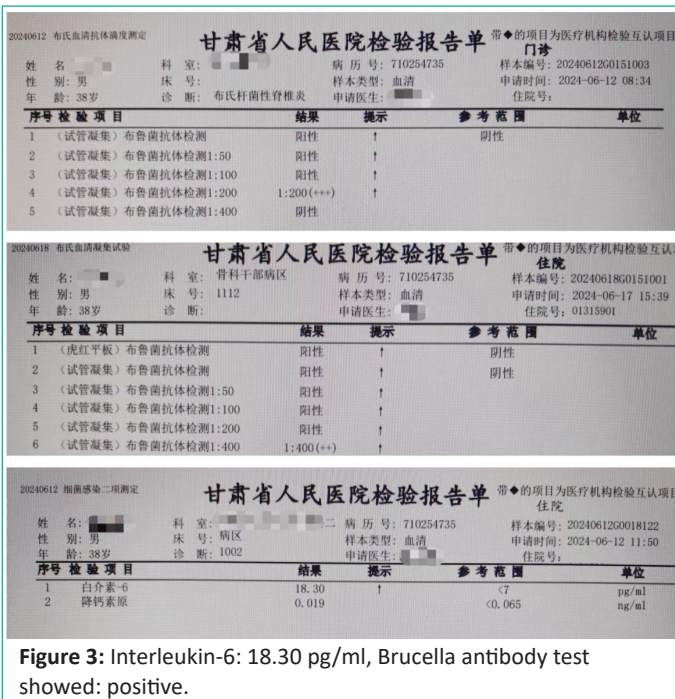
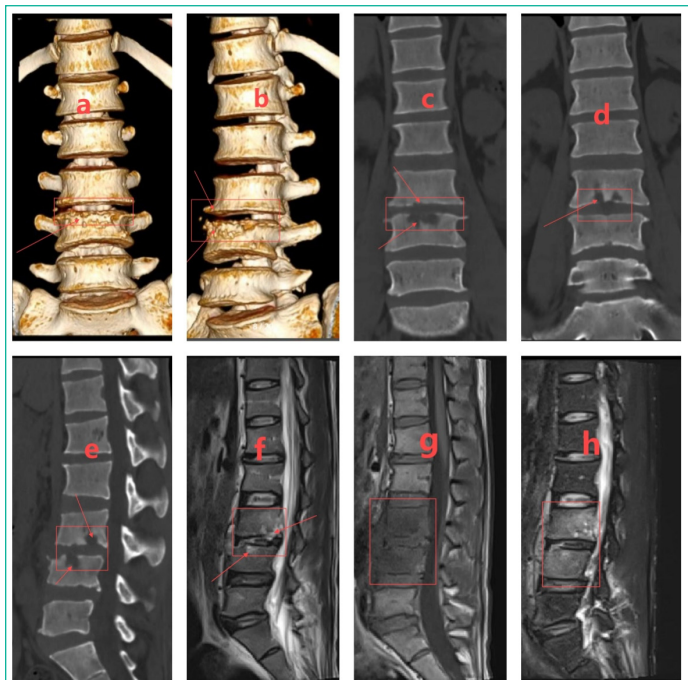
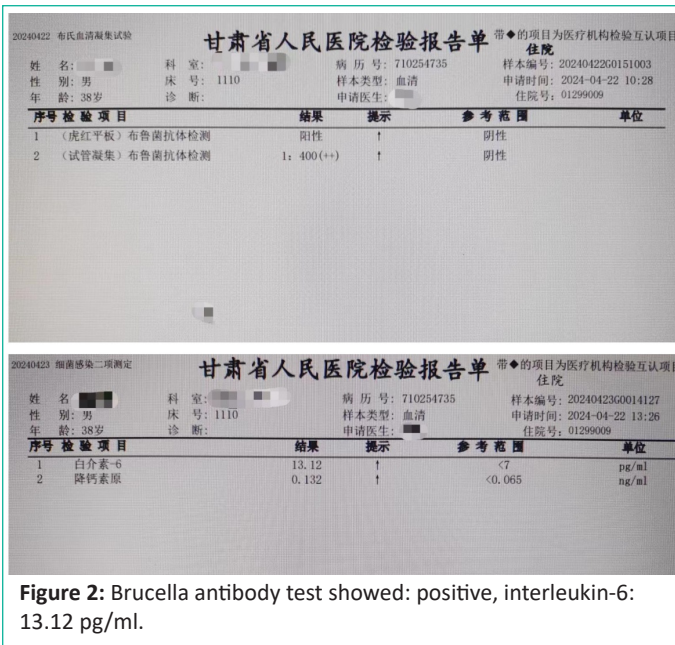
Case Report

The patient was a 38-year-old male who was hospitalized for 12 days due to fever, low back pain and limitation of movement. He reported that 3 months ago he started having pain

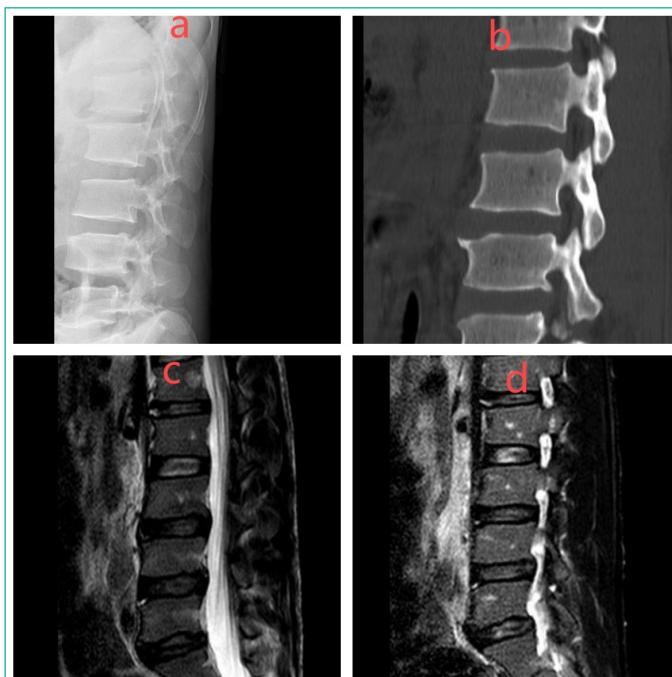

Figure 1 a-d: X-rays, CT scans, and MRI scans showed: no bone destruction was seen.

in his lower back with fever, which was relieved by oral pain medication. Symptoms recurred and he came to our hospital on 20 April 2024. Physical examination showed: significant lumbar tenderness with intermittent fever. X-rays, CT scans as well as



MRI scans showed: no bone destruction (Figure 1a-d). Brucella antibody test showed: positive, interleukin-6: 13.12 pg/ml (Figure 2). Brucella infection was diagnosed in conjunction with the clinical manifestations. doxycycline and rifamycin were given regularly orally and the symptoms resolved. the patient was successfully discharged from the hospital on 9 April 2024, and was instructed to continue the oral medication for 6 months. from 10 May 2024 to 2 June 2024, the patient autonomously reduced the dose of doxycycline and rifamycin medication by half orally for 23 days. starting from 3 June 2024, the patient again experienced lumbar on 10 June 2024, the patient came back to our hospital. Interleukin-6: 18.30 pg/ml, Brucella abortus antibody test: positive (Figure 3), CT scan and 3D reconstruction: bone destruction of lumbar 3 and 4 vertebrae (Figure 4a-e), MRI: bone destruction of lumbar 3 and 4 vertebrae, and abscess formation (Figure 4f-h). The condition was significantly worse than the first hospitalisation.

On admission, lumbar 3 and 4 vertebrae were examined and lesions were removed under general anaesthesia. Intraoperatively, it was seen that: lumbar 3 and 4 vertebrae were destroyed with disc destruction and pus formation. Necrotic bone

tissue was removed with an ultrasonic bone knife, pus was aspirated with a suction device, and surrounding necrotic tissue was removed with a condenser knife (Figure 5a-b). A drainage tube was placed at the lesion site (Figure 5c). The lesion was repeatedly flushed with iodophor solution and saline through the drainage tube. Finally, pedicle screws were implanted to stabilise the lumbar spine (Figure 6) [3]. Pathological examination showed pathological changes consistent with chronic septic arthritis (Figure 7) [4]. Postoperative oral doxycycline and rifamycin were continued in adequate doses. Changes in the patient's condition were recorded.

Discussion

Medication is the first choice for Brucella spondylitis. However, when the condition is aggravated with bone destruction

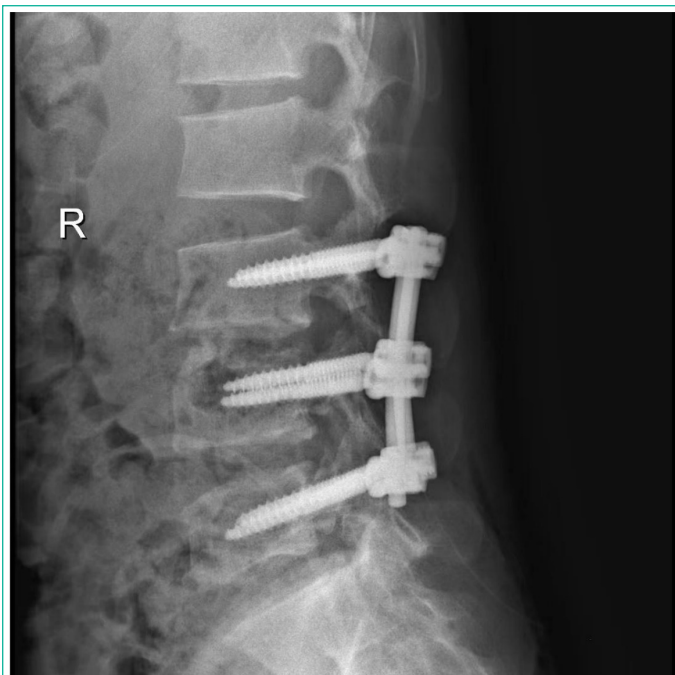


Figure 6: Implantation of pedicle screws to stabilise the lumbar spine.

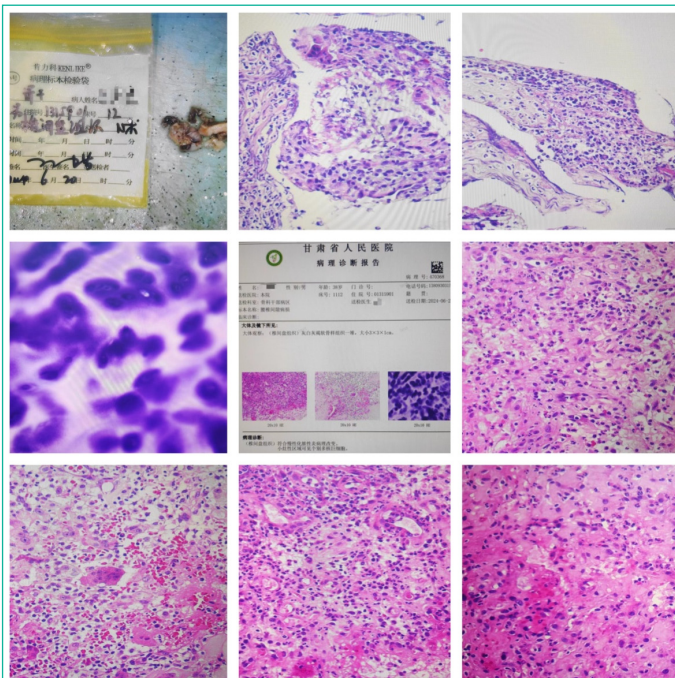


Figure 7: Pathological examination showed pathological changes consistent with chronic suppurative inflammation.

and abscess formation, surgical treatment is the first choice. Advantages of surgical treatment: ① Complete removal of the lesion and reduction of the extent of infection. ② Fixing the lumbar spine with a nail rod system increases the stability of the lumbar spine and facilitates recovery. ③ Precise sampling, conducive to determining the nature of the infection and precise medication. ④ Placement of drainage tubes and repeated rinsing with saline and povidone-iodine solution, etc., to sterilise more thoroughly and facilitate further recovery. Postoperative treatment with oral medication is more effective [5].

Author Statements

Conflict of Interest

The authors have no financial disclosures or other conflicts of interest to report related to the content of this article.

References

1. Spervovasilis N, Karantanis A, Markaki I, Konsoula A, Ntontis Z, Koutsierimpas C, et al. Brucella Spondylitis: Current Knowledge and Recent Advances. *J Clin Med*. 2024; 13: 595.
2. Unuvar GK, Kilic AU, Doganay M. Current therapeutic strategy in osteoarticular brucellosis. *North Clin Istanbul*. 2019; 6: 415-420.
3. Na P, Mingzhi Y, Yin X, Chen Y. Surgical management for lumbar brucella spondylitis: Posterior versus anterior approaches. *Medicine (Baltimore)*. 2021; 100: e26076.
4. Ma H, Zhang N, Liu J, Wang X, Yang Z, Lou C, et al. Pathological features of Brucella spondylitis: A single-center study. *Ann Diagn Pathol*. 2022; 58: 151910.
5. Liu C, Liu Q, Zheng J, Niu N, Shi J, Yang Z. Selection of treatment strategies for lumbar Brucella spondylitis: a retrospective clinical study. *Front Surg*. 2024; 11: 1365498.