

## Case Report

# Next Generation DNA Sequencing Diagnoses Fungal Etiology in Chronic Respiratory Disease, Clinical Response Supports Clinical Validity

Gordon G and Fry SE\*

Fry Laboratories, Scottsdale, AZ, USA

\*Corresponding author: Stephen E Fry, Fry Laboratories, LLC 14807 N. 73<sup>rd</sup> St. #103 Scottsdale, AZ, USA

Received: September 16, 2021; Accepted: October 06, 2021; Published: October 13, 2021

**Abstract**

A 71-year white male presented to pulmonologists with progressively worsening respiratory problems with a chronic productive cough, asthma symptoms and malaise. The patient was subjected to the traditional treatment of antibiotics, cough suppressants, and inhaled bronchodilator and corticosteroids. After multiple failed combinations of antibiotics, cough suppressants, and inhalers, the patient had a sputum sample, which was analyzed by special stains and targeted Next Generation DNA Sequencing (NGS). Fungal eukaryotic (18S) NGS identified by 'best match', *Candidae parapsilosis* and *C. viswanathii* and an organism in the *Glomerulaceae* family, *Funnelformis mosseae*. The patient was prescribed an antifungal in tandem with an antibiotic, Terbinafine and Doxycycline. The patient rapidly improved to his baseline. This communication communicates the potential of NGS microbial sequencing in pathogen identification in chronic pulmonary disease and improved clinical outcome.

**Keywords:** *Candidae parapsilosis*; *C. viswanathii*; *Funnelformis mosseae*; DNA Sequencing; Respiratory disease

**Introduction**

A 71-year-old white male presented to the pulmonologists for having a variety of respiratory problems. Besides having a known history of exercise-induced asthma, the patient reported suffering from allergic rhinitis, had a deviated nasal septum, and consistently produced an above average amount of sputum throughout his life. Over the past year, the patient started to develop increasing respiratory complaints: persistent productive cough, increasing eustachian tube dysfunction, laryngitis, inflammation of the nasal mucosal lining, and a persistent feverish feeling. His primary care physician prescribed Augmentin, which cleared up his symptoms for two weeks. He returned to his symptomatic state with complaint of a cough, sputum, plugged ears, and malaise. The patient received a course of Amoxicillin with symptomatic relief for two weeks and then a sharp remission. The patient switched to another primary care physician who prescribed doxycycline. The patient improved for two weeks and decided he was well enough to travel. Shortly after his trip he became symptomatic again with complaints of cough, significant sputum production, and malaise. These issues worsened and ended up developing into full bronchitis and tracheitis. The patient then consulted a pulmonologist who believed that the patient potentially had acute coccidiomycosis or influenza. The pulmonologist empirically prescribed benzonate and phenergan with codine.

**Case Presentation**

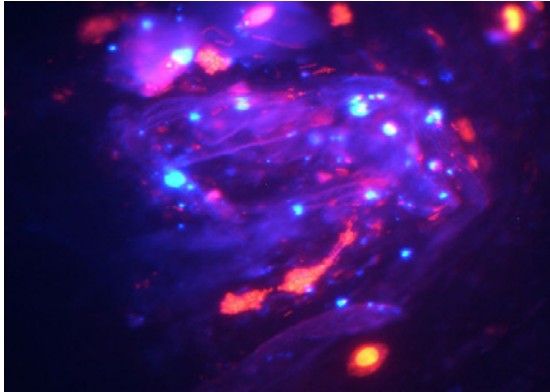
His chest X-ray was normal, sputum cultures were positive for *Streptococci spp.*, *Neisseria spp.* and *Prevotella spp.*, his Coccidiomycosis serologies were negative. A sinus X-ray or CT was not done. The fungal culture grew *Candida spp.* While the traditional identification tests were being performed, the patient

also had a sputum sample sent to Fry Laboratories for special stains and fungal eukaryotic (18S) microbial sequencing using the RIDI™ system [1]. The stain developed in our laboratory performed on the sputum combines a Hoechst stain and Calcofluor White fungal stain ('Mosaic' stain) for identification of DNA containing biofilm and fungal elements [2-4]. The stain resulted in a clear indication of significant DNA positive elements, biofilm, and fungi in the sputum sample. Amplicon sequencing and bioinformatic analysis identified several fungi; *Funnelformis mosseae*, *Candidae parapsilosis* and *C. viswanathii*.

The patient was prescribed terbinafine 250mg/day and doxycycline 100mg/b.i.d. By the 39<sup>th</sup> day the patient had dramatic improvements of all respiratory symptoms and constitutional complaints. The patient's respiratory capacity and abilities returned to baseline and his overall energy level and feeling of wellbeing returned to normal as well (Figure 1).

**Discussion**

The patient was most likely colonized in the sinus tract and pulmonary architecture. NGS augments the microscopy and clinical findings and clarifies the infectious process in respiratory disease. Less than 2% of bacteria are cultivable, fungi are also difficult to culture. Of great utility is the ability to rapidly identify fungi, which are usually difficult to grow and require a much longer time for culture. The prominent fungi in the sample *Funnelformis mosseae* (formerly *Glomus mosseae*) is a common arbuscular mycorrhizal soil fungus, uncultivable, with worldwide distribution. It has been reported in humans by our laboratory [5-7]. The use of Doxycycline augments the fungal activity of terbinafine; doxycycline may play a role in reducing the fungal biofilm allowing the antifungal terbinafine to work more



**Figure 1:** 'Mosaic' Stain of sputum, 400X. The 'Mosaic' stain is an easy to use combination stain used in our laboratory to simultaneously demonstrate biofilm and the presence of chitin (common to all fungi and some protozoa). Images of the Hoechst stain and then of the Calcofluor white stain are merged electronically to provide the image which include a color-coded interpretation.

effectively [8,9]. NGS allows the clinician to utilize a technology that has revolutionized human genomics; it is now possible to assess uncultivable microbes, which we are discovering are playing a greater role in human disease.

## Acknowledgement

We would like to thank the Southwest Center for Chronic Disease for financial assistance.

## References

1. Ellis JE, Missan DS, Shabilla M, Martinez D, Fry SE. Rapid infectious disease identification by next-generation DNA sequencing. *J Microbiol Methods*. 2017; 138: 12-19.
2. Hoch HC, Galvani CD, Szarowski DH, Turner JN. Two new fluorescent dyes applicable for visualization of fungal cell walls. *Mycologia*. 2005; 97: 580-588.
3. Latt SA, Stetten G, Juergens LA, Willard HF, Scher CD. Recent developments in the detection of deoxyribonucleic acid synthesis by 33258 Hoechst fluorescence. *J Histochem Cytochem*. 1975; 23: 493-505.
4. Latt SA, Stetten G. Spectral studies on 33258 Hoechst and related bisbenzimidazole dyes useful for fluorescent detection of deoxyribonucleic acid synthesis. *J Histochem Cytochem*. 1976; 24: 24-33.
5. Fry SE. Applied use of Next Generation Sequencing for Infectious Disease. *Medical Research Archives: KEI Journals*. 2017.
6. Ellis J, Missan D, Shabilla M, Martinez D, Fry SE. Microbial community profiling of peripheral blood in myalgic encephalomyelitis/chronic fatigue syndrome. *Human Microbiome Journal: Elsevier*. 2018: 16-21.
7. Ellis JE, Heuser R, Missan DS, Martinez D, Heningburg A, Shabilla M, et al. Evidence for polymicrobial communities in explanted vascular filters and atheroma debris. *Mol Cell Probes*. 2017; 33: 65-77.
8. Gao Y, Zhang C, Lu C, Liu P, Li Y, Li H, et al. Synergistic effect of doxycycline and fluconazole against *Candida albicans* biofilms and the impact of calcium channel blockers. *FEMS Yeast Res*. 2013; 13: 453-462.
9. Miceli MH, Bernardo SM, Lee SA. *In vitro* analyses of the combination of high-dose doxycycline and antifungal agents against *Candida albicans* biofilms. *Int J Antimicrob Agents*. 2009; 34: 326-332.