

Clinical Image

Heroin Injection Marks Should Never be Missed on Physical Exam

Tariq Khurram*, Farhangi Arezo and Rana Fauzia

Department of Internal Medicine, University of Florida College of Medicine, USA

***Corresponding author:** Tariq Khurram, Department of Internal Medicine, University of Florida College of Medicine, Jacksonville, FL, 653 West 8th Street, Box L 18, Jacksonville, FL 32209, USA

Received: March 23, 2014; **Accepted:** June 17, 2014;
Published: June 23, 2014

Acute heroin overdose is very common problem among urban and suburban populations in the United States. Heroin abusers inject the drug intravenously to attain the desired “rush” of euphoria which not only predisposes them to dependence but also makes these individuals vulnerable to HIV, Hepatitis, abscesses.

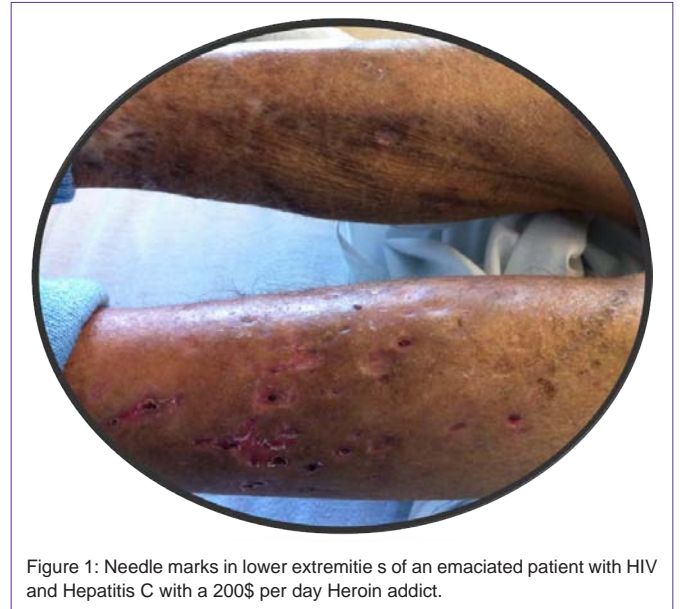


Figure 1: Needle marks in lower extremities of an emaciated patient with HIV and Hepatitis C with a 200\$ per day Heroin addict.