

Case Report

Cerebral Toxoplasmosis in A Human Immunodeficiency Virus (HIV) Seronegative Patient with Liver Cirrhosis

Elroy Patrick Weledji^{1*}; Frank Zouna²¹Department of Surgery, Faculty of Health sciences, University of Buea, Cameroon, W/Africa; Regional hospital Limbe, S.W. Region, Cameroon²Department of Medicine, Faculty of Health Sciences, University of Buea, Cameroon, W/Africa, Regional Hospital Limbe, S.W. Region, Cameroon***Corresponding author: Weledji EP**

Holy family foundation, Livanda Kongo Hill, lumpsum quarters, PO Box 126, Limbe, Cameroon.

Tel: 237699922144

Email: elroypat@yahoo.co.uk

Received: September 12, 2024**Accepted:** October 01, 2024**Published:** October 08, 2024

Introduction

CNS infection often develops as an opportunistic infection in patients with impaired host defence mechanisms due to immune deficiency, malignancy, diabetes mellitus, alcoholism, liver cirrhosis and, the prognosis is usually poor [1,2]. It develops either by spread from a contiguous focus or by haematogenous spread from a distant focus, such as intra-abdominal infection, endocarditis, urinary tract infection, or pulmonary infection. It is rare, but life-threatening in an HIV seronegative patient with decompensated liver cirrhosis. Liver cirrhosis is an immunocompromised state because of reticuloendothelial dysfunction and porto-systemic shunting [3]. Bacterial infections in cirrhosis are common, particularly in decompensated patients and account for significant mortality [4,5]. A case of a cerebral parasitic toxoplasmosis in an HIV-seronegative patient with liver cirrhosis is reported.

Case Presentation

A 40-year-old African man was admitted as an emergency with a sudden left arm and leg weakness. He had no history of

Abstract

Cerebral toxoplasmosis can affect a patient who is immunocompromised with chronic liver disease. Patients with liver cirrhosis with Central Nervous System (CNS) infection could easily be misdiagnosed for hepatic encephalopathy. A case of cerebral toxoplasmosis in an Human Immunodeficiency Virus (HIV)-seronegative patient with liver cirrhosis in a low-resource setting is reported. Although the cerebral toxoplasmosis improved with medical treatment, the patient died from progressive hepatic failure. Despite the usually poor prognosis, early diagnosis and prompt treatment of CNS infection complicating immunosuppression from chronic liver disease) would prevent early death.

Keywords: Liver; Cirrhosis; Brain; Toxoplasmosis; Sepsis; Encephalopathy

Key Clinical messages

- Patients with liver cirrhosis with Central Nervous System (CNS) infection could easily be misdiagnosed for hepatic encephalopathy. A clinical suspicion of a cranial infection would necessitate a brain CT or an MRI to exclude the presence of CNS lesions.
- Cerebral toxoplasmosis can occur in HIV seronegative patient

Cerebral toxoplasmosis can occur in patient with cirrhosis

hypertension, diabetes mellitus, cardiovascular disease, atrial fibrillation or human immunodeficiency virus (HIV) infection. He was a driver, married, and with excessive alcohol consumption (6 drinks per day). On admission, he was conscious with a Glasgow Coma Scale score of 15. His blood pressure was 120/80 mmHg, pulse rate 80/minute and regular, respiratory rate 20/min, and normal body temperature, 37°C. The conjunctivae were pink and oral mucosa moist. Chest and cardiovascular examinations were unremarkable. Abdominal examination revealed dilated supraumbilical veins consistent with *caput medusa* a sign of chronic liver disease and portal hypertension, a nodular liver, moderate splenomegaly and mild ascites. He had a left hemiparesis, but there was no neck stiffness nor flapping tremor indicating meningism or encephalopathy respectively. The laboratory test revealed anaemia (Haemoglobin 7.6 g/dl), a normal white cell count (WBC $9.5 \times 10^9/\text{mm}^3$, thrombocytopenia ($119 \times 10^9/\text{mm}^3$), negative HIV serology and malaria parasite, normal urea, creatinine, clotting screen, serum albumin and alpha-fetoprotein. Liver tests showed normal liver

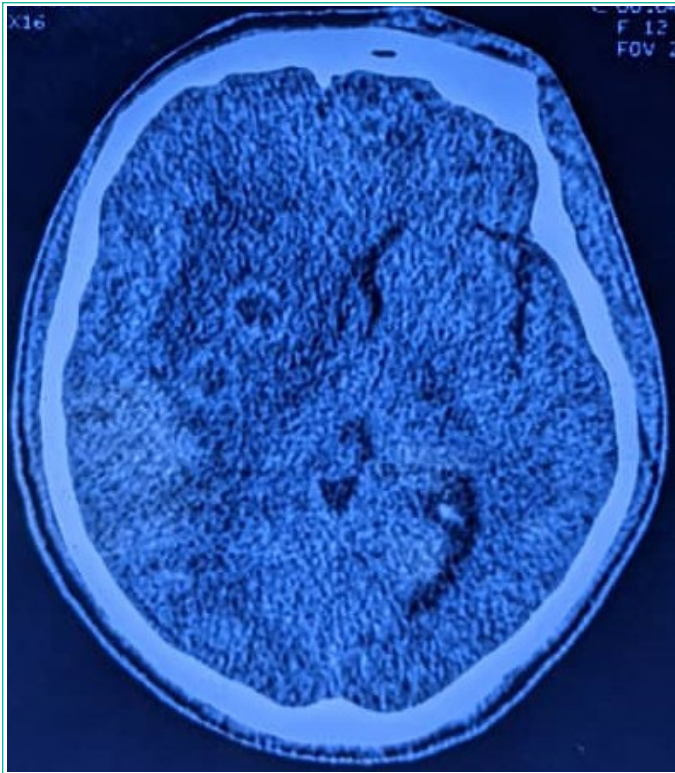


Figure 1: Brain CT scan showing contrast enhanced rings of *T. gondii* with surrounding oedema and effacement of right lateral ventricular horn.

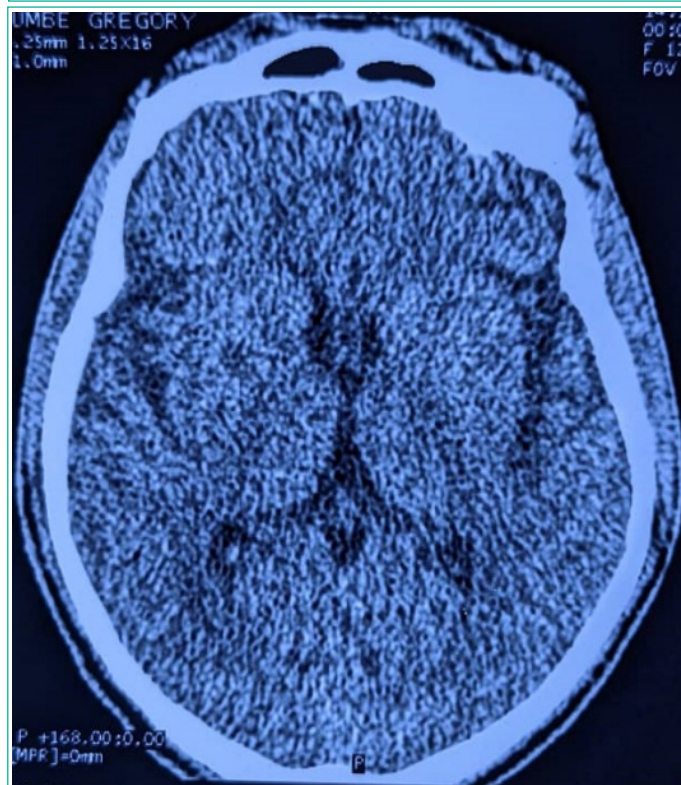


Figure 2: CT scan showing response to 1 week of medical treatment of *toxoplasmosis gondii*.

transaminases and a toxoplasma IgG serology was not done due to financial constraints. Urinary urobilinogen, glucose, bilirubin and ketone were negative. Ascitic tap showed ascitic fluid of yellowish colouration, WBC of < 5 cells/mm³ only and ascitic fluid proteins of 12g/l (n: 0-30 g/l). Abdominal ultrasound showed a nodular liver with irregular borders and with a coarse heterogeneous echostructure consistent with cirrhosis. There was also a homogeneous splenomegaly. A cerebral Computed Tomography (CT) scan revealed multiple cerebral contrast ring-enhancing lesions with massive perifocal oedema and mass effect

with effacement of the right frontal horn (Figure 1). The findings were suggestive of cerebral toxoplasmosis and CNS tuberculosis was a possible differential. The patient was treated empirically for cerebral toxoplasmosis with a combination of double strength trimethoprim and sulfamethoxazole thrice daily for 6 weeks, vitamin B1, proton pump inhibitor (omeprazole) and physiotherapy. There was a clinical regain of motor strength in both left upper and lower limbs after 1 week and, a head CT scan showed radiological improvement (Figure 2). The patient was discharged a week later with continuation of medical treatment. He returned after 12 months with decompensated liver disease and died from hepatic encephalopathy a few months later.

Discussion

The case demonstrated the presentation of cerebral toxoplasmosis in an HIV-negative patient immunocompromised from probable alcoholic liver cirrhosis. The presumptive diagnosis was made from the clinical findings, ultrasound of the liver, and a brain CT scan. The neurological symptoms were relieved following the empirical treatment of cerebral toxoplasmosis. The patient, however, died of hepatic encephalopathy from the progressive liver disease about a year later. Patients with cirrhosis are susceptible to several infectious diseases, such as septicaemia, meningitis, pneumonia, urinary tract infection, and Spontaneous Bacterial Peritonitis (SBP) [5]. Six (11%) of 53 cases of brain abscess had liver cirrhosis, presenting with non-specific symptoms and all died soon after [6]. The high mortality in patients with liver cirrhosis is firstly due to the difficulty in differentiating brain abscess from hepatic encephalopathy. Only 34% of the patients have the complete triad of headache, fever, and focal neurological deficits [1]. In the advanced stage of liver cirrhosis, hepatic encephalopathy is common and usually presents with disorientation, confusion, drowsiness and coma. Furthermore, patients with liver cirrhosis can often have episodes of fever caused by endotoxaemia or SBP. Neck stiffness occurs in only 8% of patients with brain abscess and it is not always easy in clinical settings to detect mild neurological findings in patients with impaired consciousness. Secondly, bacterial infections worsen hepatic failure. The Systemic Inflammatory Response Syndrome (SIRS) from increased endotoxins, bile acids, nitric oxide, and cytokines such as *tumour necrosis factor- α* and *interleukin 6*, may occur resulting in sepsis, renal failure, encephalopathy and death. It is important to start treatment as quickly as possible to prevent SIRS as the cytokine cascade is usually irreversible. Thirdly, most patients with liver cirrhosis are not surgical candidates because of their bleeding tendency and low hepatic reserve. Only 33% of patients with liver cirrhosis patients received surgical treatment, compared with 66% of non-cirrhotic patients [1]. Liver dysfunction leads to several abnormalities of defence mechanisms because of the depressed humoral and cell-mediated immunity. Bacterial translocation from the intestine induces bacteraemia, and impaired hepatic bacterial clearance results in failure to control bacteraemia [3]. Severe bacteraemia may cause infections of several organs, but pathogenic bacteria may not be identified in 30% of brain abscesses [1,4]. In the present case, the causative pathogen was the parasite, *Toxoplasma gondii*. *T. gondii* infection of humans occurs either congenitally or by ingestion of foodstuffs contaminated by infected cat faeces or lamb or pork contaminated with *T. gondii* cysts [7]. Primary infection in immune competent host is asymptomatic or may produce a mild flu-like illness, malaise, headache, cervical lymphadenopathy. Infection acquired during pregnancy may lead to serious fetal malformations [8]. After

primary infection cysts are formed in the tissue and remained inactive until reactivation. Cellular immunity mediated by T cells, macrophages and cytokines play a crucial role in controlling the tissue cysts [9]. The infection is self-limiting in immunocompetent individuals because an efficient immune control limits the dissemination of the rapidly multiplying tachyzoite stage [7]. However, the parasite still remains viable in the tissue cysts. Chronically infected individuals who possess defects in cell-mediated immunity as in Chronic Liver Disease (CLD), HIV/AIDS etc, are at risk for reactivation of the infection and its dissemination, causing serious complications and death [10-12]. *T. gondii* is the most frequent obligate intracellular protozoan causing opportunistic infections in immunocompromised patients mostly in the developing world [10]. An association between *T. gondii* infection and Chronic Liver Disease (CLD) has been observed. Co-infection in both *T. gondii*/ Hepatitis B Virus (HBV) and *T. gondii*/ Hepatitis C Virus (HCV) was 33.3% and 31.4%, respectively with a highly significant association between *T. gondii* parasitaemia and HCV viral load. There was also a significant increase of liver enzymes in the serum of patients positive for *T. gondii* compared with negative patients [11]. *Toxoplasma* seropositivity was higher in patients with Child-Pugh class C CLD than Child-Pugh class A and, may signify disease evolution [12]. Several studies have reported the parasite found in 20%- 90% of patients with cirrhosis through IgG and polymerase chain reactions PCR tests [13]. The three forms of cerebral toxoplasmosis are focal toxoplasma meningoencephalitis, multifocal encephalitis and diffuse toxoplasma meningoencephalitis. The common presentations include decreased consciousness, headache, hemiparesis, cranial nerve palsy, seizure, meningeal signs, dementia and psychosis [13,14]. Diagnosis is considered from clinical findings, CT scan, or Magnetic Resonance Imaging (MRI) of the brain with serological findings [1].

Conclusion

Cerebral toxoplasmosis can affect an HIV-negative patient who is immunocompromised with liver cirrhosis. Patients with liver cirrhosis with CNS infection could easily be misdiagnosed for hepatic encephalopathy. A clinical suspicion of a cranial infection is important when encountering cirrhotic patients with disturbance of consciousness and fever. Brain CT or MRI must be considered to exclude the presence of CNS lesions. Early treatment is important for this complication of immunosuppression which has a poor prognosis.

Author Statements

Author Contributions

EPW was the main author, FZ was the main physician and contributed to literature search and writing of the paper.

Consent

Written informed consent from the next of kin to the patient was granted to write and publish the paper.

Acknowledgements

Maryl Ngomba and Nina Bilola Voma contributed to collection of test reports and retrieval of medical record.

Conflict of Interest

The authors declare no competing interests

Data Availability Statement

The data that support the findings of this study are available on request from the corresponding author. The data are not publicly available due to privacy or ethical restriction.

References

1. Kao Pt, Tseng HK, Liu CP, Su SC, Lee CM. Brain abscess: Clinical analysis of 53 cases. *J Microbiol Immunol Infect.* 2003; 36: 129-136.
2. Lu CH, Chang WN, Lui CC. Strategies for the management of bacterial brain abscess. *J Clin Neurosci.* 2006; 13: 979-985.
3. Ashare A, Monick MM, Powers LS, Yarovinsky T, Hunninghake GW. Severe bacteraemia results in a loss of hepatic bacterial clearance. *Am J Respi Crit Care Med.* 2006; 173: 644-652.
4. Merli M, Lucidi C, Gianelli V, Giusto M, Riggio O, Falcone M, et al. Cirrhotic patients are at risk for health care-associated bacterial infections. *Clin Gastroenterol Hepatol.* 2010; 8: 979-985.
5. Arvanti V, D'Amico G, Fede G, Manousou P, Tsochatzis E, Pleguezuelo M, et al. Infections in patients with cirrhosis increase mortality four-fold and should be used in determining prognosis. *Gastroenterology.* 2010; 139: 1246-1256.
6. Kato J, Koda M, Fujise Y, Tokunaga S, Matono T, Sugihara T, et al. Brain abscess in a patient with decompensated cirrhosis. *J Med cases.* 2011; 2: 55-57.
7. Al Malki ES. Toxoplasmosis, stages of the protozoan life cycle and risk assessment in humans and animals for an enhanced awareness and an improved socio economic status. *Saudi J Biol Sci.* 2021; 28: 962/969.
8. Montoya JG, Liesenfeld O. Toxoplasmosis. *The Lancet.* 2004; 363: 1965-76.
9. Schlutter D, Kwok LY, Lutjen S, Soltek S, Hoffmann S, Korner H, et al. Both lymphotoxin- α and TNF are crucial for control of *Toxoplasma gondii* in the central nervous system. *J Immunol.* 2003; 170: 6172-6182.
10. Ferreira MS, Borges AS. Some aspects of protozoan infections in immunocompromised patients. A review. *Mem Instv Oswaldo Cruz.* 2002; 97: 443-457.
11. El-Sayed MN, Ramadan ME, Ramadan ME. *Toxoplasma gondii* infection and Chronic Liver Diseases: Evidence of an association. *Trop Med Infect Dis.* 2016; 1: 7.
12. Navia BA, Petito CK, Gold JWM, Cho ES, Jordan BD, Price RW. Cerebral toxoplasmosis complicating the acquired immune deficiency syndrome. Clinical and neuropathological findings in 27 patients. *Ann Neurol.* 1986; 19: 224- 38.
13. Tedjamartono TD, Suryana K. Cerebral toxoplasmosis in newly diagnosed cirrhosis patient: a case report. *Int Journal of Surg Research.* 2021; 10: 111-114.
14. El-Henawy EA, Razik AA, Zakaria S, Elhammady D, Saady N, Azab MS. Is toxoplasmosis a potential risk factor for liver cirrhosis? *Asian Pacific J Trop Med.* 2015; 8: 784-791.