

Case Report

A Case of Presenting the Occipital Focal Sign as Post-Resuscitation Encephalopathy

Masao Ueno¹, Shiho Okuda*, Tomoko Ikkaku¹,
Manami Inagi², Masayuki Shirakawa², Fumio
Kanda³ and Shin Takano¹

¹Department of Neurology, Hyogo Rehabilitation Center Hospital, 1070, Akebono-cho, Nishi-ku, Kobe 651-2181, Japan

²Department of Rehabilitation, Hyogo Rehabilitation Center Hospital, 1070, Akebono-cho, Nishi-ku, Kobe 651-2181, Japan

³Department of Neurology, Kobe University Hospital, 7-5-2 Kusunoki-cho, Chuo-ku, Kobe 650-0017, Japan

*Corresponding author: Shiho Okuda, Department of Neurology, Hyogo Rehabilitation Center Hospital, 1070, Akebono-cho, Nishi-ku, Kobe 651-2181, Japan, Tel: 81-78-927-2727, Fax: 81-78-925-9203, Email: s_okuda@hwc.or.jp

Received: May 05, 2014; Accepted: Aug 04, 2014;

Published: Aug 07, 2014

Abbreviations

SPECT: Single photon Emission Computed Tomography; EEG: Electroencephalogram

Background

Most patients with a hypoxic brain injury show a broad spectrum of impairment [1-3]. Here, we report a case that showed visual agnosia as an occipital focal sign following hypoxic brain injury.

Case Presentation

A right-handed 38-year-old man was admitted to the emergency hospital with cardiac arrest due to ventricular fibrillation. Although cardiopulmonary resuscitation for 38 minutes was successful, clinical features of post-resuscitation encephalopathy developed. Brain CT findings were negative. MRI was not performed. The patient was admitted to our hospital for rehabilitation 1 month after the incident.

A neurological examination was normal except for global aphasia. The patient could only understand simple commands such as to open or close his eyes. A Standard Language Test of Aphasia showed that auditory verbal comprehension, naming, repetition, reading and writing were impaired.

As global aphasia gradually improved, the patient exhibited substantial difficulty recognizing people on the basis of their facial appearance, objects, and words. He could not recognize members of his immediate family including his wife and close friends by sight except by voice. The patient was able to draw objects and copy drawings, but could not explain them. Holding an object allowed him to identify it where vision had not. Visual fields and acuity were normal. A Visual Perception Test for Agnosia (VPTA) showed impairment, as he correctly named 2 of 16 objects, 5 of 16 colors, 1 of

Abstract

A 38-year-old man was admitted with cardiac arrest. Although cardiopulmonary resuscitation was successful, visual agnosia remained as post-resuscitation encephalopathy. Brain MRI findings 6 months after onset appeared to be normal, while brain SPECT showed occipital hypoperfusion. Most patients with a hypoxic brain injury show a broad spectrum of impairment. Nevertheless, our case was characteristic in regard to visual agnosia as a focal sign related to an occipital lobe disorder.

Keywords: Hypoxic brain injury, Focal occipital sign, Visual agnosia, SPECT

16 pictures, 3 of 16 celebrities, and 0 of 8 signs. We made a diagnosis of visual agnosia. MRI of the brain revealed no abnormality and EEG findings were also normal.

We performed rehabilitation training, which led to good VPTA scores for naming objects (14/16) and colors (14/16), where as impairment remained for naming pictures (10/16), celebrities (2/16), and signs (1/8). The Mini-Mental State Examination score was 25 of 30. Brain MRI performed 6 months after the incident demonstrated no abnormality (Figure 1 A, B), while brain SPECT showed occipital hypoperfusion, by which visual agnosia was substantiated (Figure 2). The patient was independent in daily life activities.

Discussion

Visual agnosia is subdivided into a perceptive visual agnosia, in which a deficit in high level perception is implicated, and associative visual agnosia, in which a high level perception is preserved but the percept is unable to activate semantic identifying information [4]. Our patient was diagnosed with associative visual agnosia, because

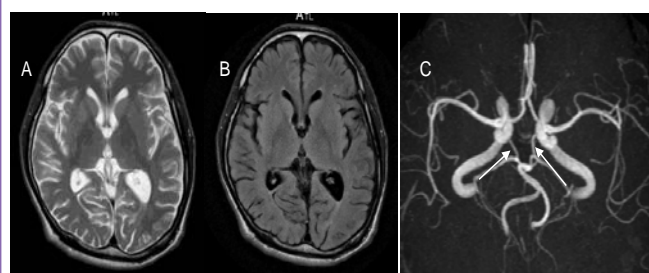
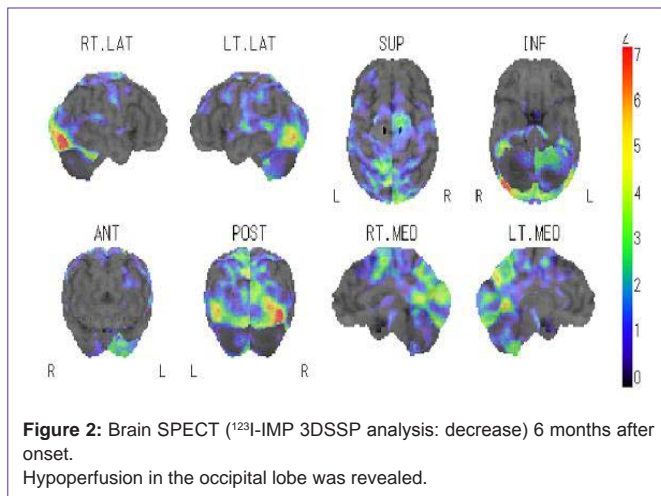


Figure 1: Brain MRI 6 months after onset. No remarkable findings were noted in (A) T2-weighted axial and (B) FLAIR-weighted axial images. C: Brain MRA shows that the posterior communicating arteries were well developed.



he could draw an object and copy a drawing but could not describe what was seen.

Brain damage caused by hypoxia after cardiac arrest is typically widespread; with the watershed cerebral cortex and basal ganglia more frequently damaged [1]. Clinically, visual recognition problems seem to be noted less frequently than memory disturbance and changes in personality and behavior [1-3]. Our case was characteristic in presentation of an occipital focal sign, visual agnosia, in spite of predicted global brain damage. MRA showed that the posterior communicating arteries were well developed (Figure 1C), thus posterior circulation might be mainly supplied by anterior circulation through the posterior communicating arteries. As a result, the occipital lobe that became a border zone area might be strongly affected by hypoxia.

Diffusion-weighted MRI findings in an acute stage are helpful for evaluating diffuse cerebral anoxia, and can aid in determination of prognosis and management [5]. Also MRI findings in the chronic stages how diffuse brain atrophy and obtundation of the gray-white matter junction [5,6]. Otherwise, Arishima et al. reported 2 patients with hypoxic brain damage for whom MRI performed in an acute stage did not show abnormal intensity [7]. Those 2 cases had different clinical courses, as one did not recover from coma, and the other showed complete recovery. MRI at 4 months in the former case revealed mild brain atrophy of the cerebrum and cerebellum. Therefore, MRI may reveal abnormal findings in the chronic stage in clinically severe cases, even when acute stage findings are normal.

The present case is interesting because brain MRI findings were normal in spite of obvious visual agnosia 6 months after the incident. SPECT revealed hypoperfusion of the occipital lobes. There are a few cases reported in which SPECT showed decreased perfusion in

regions of the brain where MRI findings did not show hypoxic brain injury [8,9]. Although neuroimaging is a useful tool for demonstrating hypoxic injury, no randomized controlled trials have been conducted [10]. Further studies are needed to clarify the prognosis of hypoxic brain injury.

Conclusion

We report a case of hypoxia in the chronic stage in which visual agnosia was presented as an occipital focal sign. SPECT was useful to identify hypoxic brain injury in our patient.

Competing Interests

The authors have no competing interests to declare.

References

- Greene JD. Apraxia, agnosias, and higher visual function abnormalities. See comment in PubMed Commons below *J Neurol Neurosurg Psychiatry*. 2005; 76 Suppl 5: v25-34.
- Caine D, Watson JD. Neuropsychological and neuropathological sequelae of cerebral anoxia: a critical review. See comment in PubMed Commons below *J Int Neuropsychol Soc*. 2000; 6: 86-99.
- Peskine A, Picq C, Pradat-Diehl P. Cerebral anoxia and disability. See comment in PubMed Commons below *Brain Inj*. 2004; 18: 1243-1254.
- Wilson BA. Cognitive functioning of adult survivors of cerebral hypoxia. See comment in PubMed Commons below *Brain Inj*. 1996; 10: 863-874.
- Arbelaez A, Castillo M, Mukherji SK. Diffusion-weighted MR imaging of global cerebral anoxia. See comment in PubMed Commons below *AJNR Am J Neuroradiol*. 1999; 20: 999-1007.
- Takahashi S, Higano S, Ishii K, Matsumoto K, Sakamoto K, Iwasaki Y, et al. Hypoxic brain damage: cortical laminar necrosis and delayed changes in white matter at sequential MR imaging. See comment in PubMed Commons below *Radiology*. 1993; 189: 449-456.
- Arishima H, Hosoda T, Hashimoto N, Handa Y, Kubota T, Suzuki R. [Hypoxic ischemic encephalopathy with atypical findings on CT and MR imaging: two case reports]. See comment in PubMed Commons below *Brain Nerve*. 2009; 61: 874-879.
- Rupright J, Woods EA, Singh A. Hypoxic brain injury: evaluation by single photon emission computed tomography. See comment in PubMed Commons below *Arch Phys Med Rehabil*. 1996; 77: 1205-1208.
- Shibata K, Uchiyama S, Tei H, Shibagaki Y, Maruyama S. [A case of cortical blindness confirmed by single photon emission computerized tomography and visual evoked potential]. See comment in PubMed Commons below *Rinsho Shinkeigaku*. 1994; 34: 241-245.
- Hahn DK, Geocadin RG, Greer DM. Quality of evidence in studies evaluating neuroimaging for neurologic prognostication in adult patients resuscitated from cardiac arrest. See comment in PubMed Commons below *Resuscitation*. 2014; 85: 165-172.