

Clinical Image

Clival Invasion by Giant Prolactinoma

Belfquih H*, El Mostarchid B

Department of Neurosurgery, Mohammed V Military Teaching Hospital, Morocco

*Corresponding author: Hatim Belfquih, Department of Neurosurgery, Mohammed V Military Teaching Hospital, N°273, Hay Al Khiam III, Temara, Morocco

Received: November 17, 2016; **Accepted:** December 02, 2016; **Published:** December 07, 2016

Clinical Image

A 35-year-old man presented with complaints of generalized headaches and worsening vision in both eyes. Magnetic resonance imaging showed a massive sellar tumor with suprasellar, cavernous sinuses, sphenoid and ethmoid air sinuses extension (Figure 1A, B and C). It also invaded the clivus and was present anterior to it and in the extradural space anterior to the brainstem (Figure 1A and C). Endocrinological evaluation showed high serum prolactin level to 2507ng/ml. A transsphenoidal surgery was performed, the tumor was partially resected. At Histological examination, the tumor cells showed infiltration into the bony trabeculae. At follow-up after 1 year, the patient showed marked improvement in the vision with no radiological progression.

Giant prolactinomas causing invasion of clivus is extremely rare. Clival invasion was associated with a lower rate of complete resection, a higher rate of operative complications, and a higher rate of recurrence [1,2].

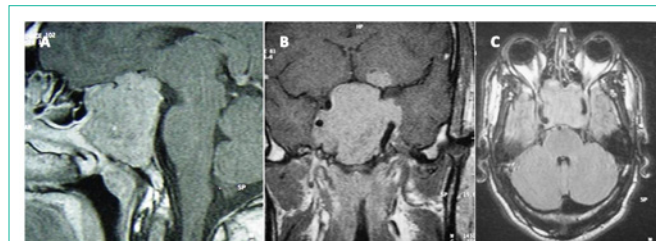


Figure 1:

References

1. Wong K, Raisanen J, Taylor SL, McDermott MW, Wilson CB, Gutin PH. Pituitary adenoma as an unsuspected clival tumor. *Am J Surg Pathol.* 1995; 19: 900-903.
2. Chen X, Dai J, Ai L, Ru X, Wang J, Li S, et al. Clival invasion on multi-detector CT in 390 pituitary macroadenomas: correlation with sex, subtype and rates of operative complication and recurrence. *AJNR Am J Neuroradiol.* 2011; 32: 785-789.