

## Clinical Image

# Endogenous Endophthalmitis: Clinical Picture

Zeinebou H'meimett\*; LOCherkaoui

Department of Ophthalmology A, Specialty Hospital,  
Rabat, Morocco

\*Corresponding author: Zeinebou H'meimett

Department of Ophthalmology A, Specialty Hospital,  
Rabat, Morocco.

Email: zeienbou\_h@yahoo.com

**Received:** October 09, 2023

**Accepted:** November 03, 2023

**Published:** November 10, 2023

## Clinical Image

Endogenous endophthalmitis is an exceptional endo ocular infection occurring through the hematogenous route.

This is a 67-year-old diabetic or ADO patient, admitted for a profound decline in visual acuity of the OD with a painful red eye.

Ophthalmological examination reveals a decrease in visual acuity with positive light perception with high tone in the finger, conjunctival hyperemia, a perikeratic circle, synechiae and hypopyon (Figure 1). An ocular ultrasound performed showing vitreous condensation. Venous treatment based on dual therapy and IVT. A worsening of the picture with the appearance of rubeosis iris and hyphema (Figure 2).

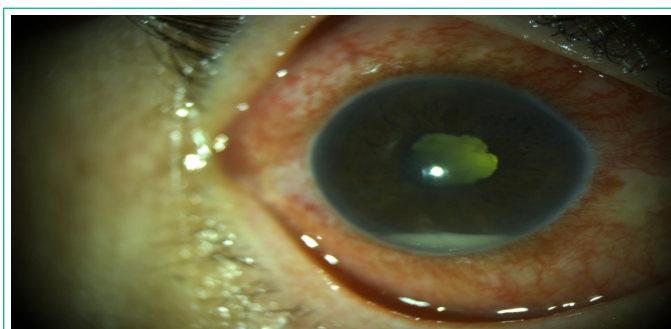

Figure 1: Upon admission.

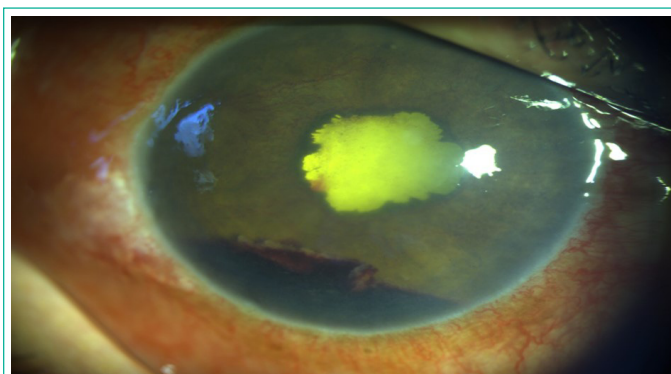


Figure 2: A few days of progress.