

Clinical Image

Bubble Inside the Cup

Krushna Gopal Panda*, Avik Kumar Roy and Soumyava Basu

Retina Services, LV Prasad Eye Institute, India

***Corresponding author:** Krushna Gopal Panda, Retina Services, LV Prasad Eye Institute, Patia, Bhubaneswar, India

Received: May 01, 2016; **Accepted:** May 09, 2016;

Published: May 12, 2016

Clinical Image

A 33 year old man presented with advanced glaucoma and retinal detachment as a result of blunt ocular trauma. Three weeks following pars plana vitrectomy plus endolaser and fluid gas exchange, he presented with a scintillating air bubble within the optic disc cup deepened by glaucomatous damage. At the post-operative 3 weeks the best corrected visual acuity and intra ocular pressure were Counting finger 1 meter and 35 mm of hg respectively. At two months follow up, the best corrected visual acuity and intraocular pressure were 20/40 and 18mm Hg with three medications respectively. The air bubble was gone.

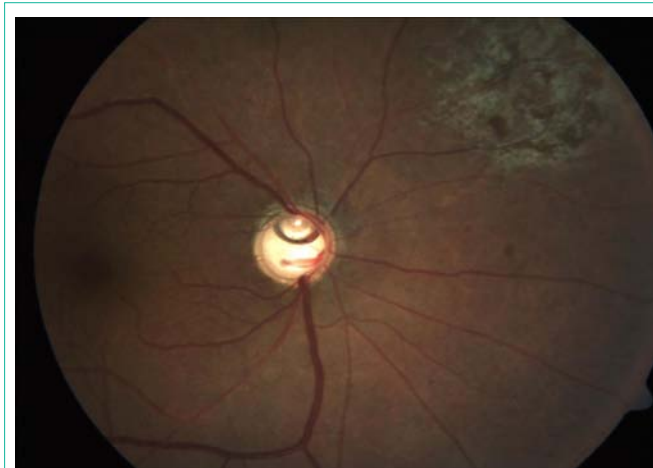


Figure 1: Fundus photograph of the right eye showing a small scintillating air bubble within the optic disc cup deepened by glaucomatous damage.