

## Special Article - Ophthalmology: Clinical Cases and Images

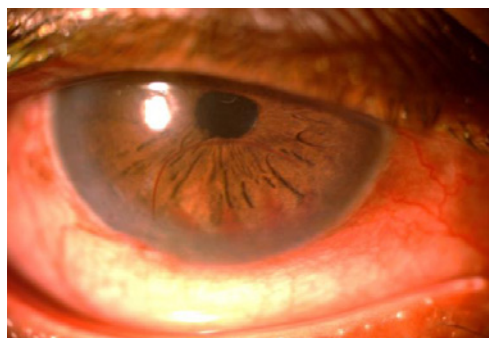
## “The Thin Red Line”: In Post WW2 era

**Roy AK\* and Ramyashri S**

Glaucoma Service, LV Prasad Eye Institute, India

**\*Corresponding author:** Roy AK, Glaucoma Service, LV Prasad Eye Institute, Patia. Bhubaneswar 751024, India**Received:** July 18, 2016; **Accepted:** July 22, 2016;**Published:** July 25, 2016**Clinical Image**

A 69 year old gentleman with uncontrolled primary open angle glaucoma and cataract in his only seeing right eye underwent small incisional cataract surgery with posterior chamber intraocular lens implantation combined with trabeculectomy. On first postoperative day, there were a shallow descemet's membrane detachment and trace hyphema which were observed. Subsequently after one week, the descemet's membrane reattached spontaneously with a spectacular red sinuous margin, probably resulting from pulling of altered heme at the junction of normal and previously detached descemet's membrane.

**Figure:**